Subaxial Cervical Spine Injury Classification Systems

Bizhan Aarabi, MD, FRCSC*
Beverly C. Walters, MD, MSc, FRCSC‡§
Sanjay S. Dhall, MD¶
Daniel E. Gelb, MD||
R. John Hurlbert, MD, PhD, FRCSC#
Curtis J. Rozzelle, MD**
Timothy C. Ryken, MD, MS‡‡
Nicholas Theodore, MD§§
Mark N. Hadley, MD‡

*Department of Neurosurgery, University of Maryland, Baltimore, Maryland; ‡Division of Neurological Surgery, University of Alabama at Birmingham, Birmingham, Alabama; §Department of Neurosciences, Inova Health System, Falls Church, Virginia; ¶Department of Neurosurgery, Emory University, Atlanta, Georgia; ||Department of Orthopaedics, University of Maryland, Baltimore, Maryland; #Department of Clinical Neurosciences, University of Calgary Spine Program, Faculty of Medicine, University of Calgary, Calgary, Alberta, Canada; **Division of Neurological Surgery, Children's Hospital of Alabama, University of Alabama at Birmingham, Birmingham, Alabama; ‡‡Iowa Spine & Brain Institute, University of Iowa, Waterloo/Iowa City, Iowa; §§Division of Neurological Surgery, Barrow Neurological Institute, Phoenix, Arizona

Correspondence:
Mark N. Hadley, MD, FACS,
UAB Division of Neurological Surgery,
510 – 20th Street South, FOT 1030,
Birmingham, AL 35294-3410.
E-mail: mhadley@uabmc.edu,
205-934-3655 phone, 205-975-6081 fax

Copyright © 2013 by the
Congress of Neurological Surgeons

KEY WORDS: Cervical spine trauma, Radiographic classification, Spinal cord injury, Spinal fracture classification, Spinal injury classification

Neurosurgery 72:170–186, 2013 DOI: 10.1227/NEU.0b013e31828341c5 www.neurosurgery-online.com

RECOMMENDATIONS

Level I

- The Subaxial Injury Classification (SLIC) and severity scale is recommended as a classification system for spinal cord injury. This system includes morphological, ligamentous, and neurological information in its scoring, thus communicating a greater amount of information regarding the extent of the patient's injury. Its overall inter-rater reliability has an intraclass correlation coefficient of 0.71.
- The Cervical Spine Injury Severity Score (CSISS) is recommended as a classification system for graded instability and fracture patterns in patients with spinal cord injury. Although there is excellent reliability, (intra-observer and interobserver intraclass correlation coefficients for 15 reviewers were 0.977 and 0.883, respectively) the system is somewhat complicated, and its use may be limited to clinical trials rather than daily practice.

ABBREVIATIONS: ALC, anterior ligamentous complex; **ALL**, anterior longitudinal ligament; **ASIA**, American Spinal Injury Association; **AIS**, ASIA Impairment Scale; **CSISS**, Cervical Spine Injury Severity Score; **CE**, compressive extension; **CF**, compressive flexion; **DLC**, discoligamentous complex; **DE**, distractive extension; **DF**, distractive flexion; **LF**, lateral flexion; **MIV**, major injury vectors; **PLC**, posterior ligamentous complex; **PLL**, posterior longitudinal ligament; **STSG**, Spine Trauma Study Group; **SLIC**, Subaxial Injury Classification; **TRU**, Trauma Resuscitation Unit; **VC**, vertical compression

Level III

- The Harris classification of subaxial spinal injury is not recommended for describing the bony and soft tissue characteristics seen on imaging studies in spinal cord injury due to its low reliability (intraclass correlation coefficient of 0.42). It may be used in addition to more reliable measures for comparison to previous or other studies using this system.
- The Allen classification of subaxial spinal injury is not recommended for describing the mechanistic and imaging findings in cervical spine and spinal cord injury due to its low reliability (intraclass correlation coefficient of 0.53). Fortunately, this classification system is not in widespread use.

RATIONALE

Cervical spine fractures and fracture dislocations are heterogeneous in pattern and pathogenesis, and difficult to classify. Traditionally, based upon visual (imaging) appearance and a number of ambiguous and descriptive classifications,[1-5] spine surgeons have preferred using simple, nonspecific terms such as "locked facets," "wedge" or "burst" fractures in order to infer the mechanics of cervical spine injury, segmental alignment, and instability. Using these classification schemes, algorithms for management in order to achieve spinal cord protection, prevention of deformity, long-term spinal stability and mitigation of pain have been recommended.[1,2,6] Recent mechanistic classification strategies have taken advantage of radiographs,[3,7] and in a few instances axial computed tomography (CT),[1,2] in order to define major vector forces such as flexion, extension, and compression in order to further define injury severity and spinal instability. Many of these

Copyright © Congress of Neurological Surgeons. Unauthorized reproduction of this article is prohibited.

classification schemes are descriptive and cannot be validated easily.[1,3-5,8,9] With the advent of multi-dimensional reformatted static or dynamic CT and magnetic resonance imaging (MRI), an attempt has been made to introduce classifications with more reliability and validity.[10-34] An easy, reliable, and well-validated injury classification system for quantification of skeletal and ligamentous damage may help with communication, management, prognostication, and research in the field of subaxial cervical spine injuries.[35-38]

SEARCH CRITERIA

A computerized search of the National Library of Medicine (PubMed) database of English literature published from 1966 to 2011 was performed focusing on human studies and subaxial cervical spine injury classification systems using MEDLINE medical subject headings and keywords "cervical spine trauma," "cervical spine injury," "cervical spine injury classification," and "subaxial cervical spine injury." Approximately 28 500 citations were obtained. Additional search terms "Cervical Spine Injury Classification" resulted in 593 citations, "lower cervical spine injury classification" resulted in 87 citations, and "subaxial cervical spine injury classification" resulted in 25 citations. Titles and abstracts of these 112 manuscripts were reviewed. Additional publications were cross-referenced from the citation lists of these papers. Finally, the members of the author groups were asked to contribute articles known to them on the subject matter that were not found by other search means. Duplications, case reports, pharmacokinetic reports, general reviews, editorials, and critiques were excluded. Twenty-one manuscripts were fully reviewed and contributed to the topic of subaxial cervical spine injury classification systems; 4 of which contributed to the formulation of recommendations and are summarized in Evidentiary Table format at the end of this paper (Table 3).

SCIENTIFIC FOUNDATION

Anatomy

Each subaxial motion segment is made of 2 subjacent vertebrae connected together by the intervertebral disc, the posterior arch ligaments, and the facet joints. Facet joints in the subaxial spine are almost flat (~45 degrees with horizon) and the angle of inclination increases from C7 to C3.[3,9] In their classification scheme, which applies best to the cervical spine, Holdsworth and Panjabi et al divided the cervical spine motion segments into 2 columns or elements: (1) Anterior: anterior longitudinal ligament (ALL), anterior annulus, vertebral bodies, transverse processes, posterior annulus, and the posterior longitudinal ligament (PLL); and (2) Posterior: ligamentum flavum, facet capsules, interspinous ligament, supraspinous ligament, pedicles, laminae, and the spinous processes[3,9] (Figure 1).

CLASSIFICATION SYSTEMS

Holdsworth Classification

In 1949, Nicoll[5] introduced the concept of stability and instability in the treatment of thoracolumbar injuries. In 1963, based on clinical, radiological, surgical, and postmortem observational studies of 1000 patients, Holdsworth[3,39,40] proposed his 2-column concept of thoracolumbar and cervical spine stability/instability, emphasizing the importance of posterior ligamentous complex (PLC) and the morphology of facet joint sustaining violence. PLC was composed of interspinous, supraspinous, and capsular ligaments, and ligamentum flavum. Holdsworth's observational studies indicated the absolute necessity of flexion/rotation for disruption of PLC; pointing out that direct longitudinal pull along PLC fibers rarely, if ever, results in rupture, unless the intensity of trauma is extremely high. According to Holdsworth, 5 patterns of trauma can cause fractures or fracture dislocations of the spine: (1) Flexion, (2) Flexion/rotation, (3) Extension, (4) Compression, and (5) Shear (Figure 2). Flexion results in wedge fractures, which are usually stable, while flexion/rotation forces result in fractures or fracture/dislocations that are usually unstable. Extension will rupture the disc space; however, the PLC stays intact (stable in flexion). Compression will produce a burst, but because of the intactness of the PLC, these fractures are usually stable. Stability is lost in shearing injuries (Figure 2). Holdsworth's classification system establishes the importance of segmental ligaments and the influence of facet anatomy in determining stability. However, despite its apparent simplicity, it has not been widely put into practice and has never been validated.

Allen's Mechanistic Classification

As conceptualized by Allen and associates, translation of kinetic energy into fractures and dislocations is determined by 2 independent variables: injury vector and the posture of the cervical spine at the time of accident. Using these mechanistic analogies and the pattern of segmental failure on radiographs of the cervical spine from 165 patients, in 1982 Allen et al introduced their classification of the subaxial cervical spine fractures and dislocations. These investigators presumed that identical segmental failures could result from injury vectors of the same magnitude when applied to cervical spines set in similar postures.[7] Based on the mechanism of injury, fractures and dislocations occur in families, or phylogenies, with specific anatomic derangements. These families of fractures and dislocations include: (1) Compressive Flexion, (2) Vertical Compression, (3) Distractive Flexion, (4) Compressive Extension, (5) Distractive Extension, and (6) Lateral Flexion (Figure 3). The nomenclature in each category describes the forces upon the cervical spine at the time of injury and the magnitude of the force vector. Within each category, a series of injuries were described from mild to severe stages (Figure 3).

Compressive Flexion (CF)

Up to 36 percent of the 165 patients described by Allen et al had evidence of compressive flexion injury of 5 degrees of severity. This

Copyright © Congress of Neurological Surgeons. Unauthorized reproduction of this article is prohibited.

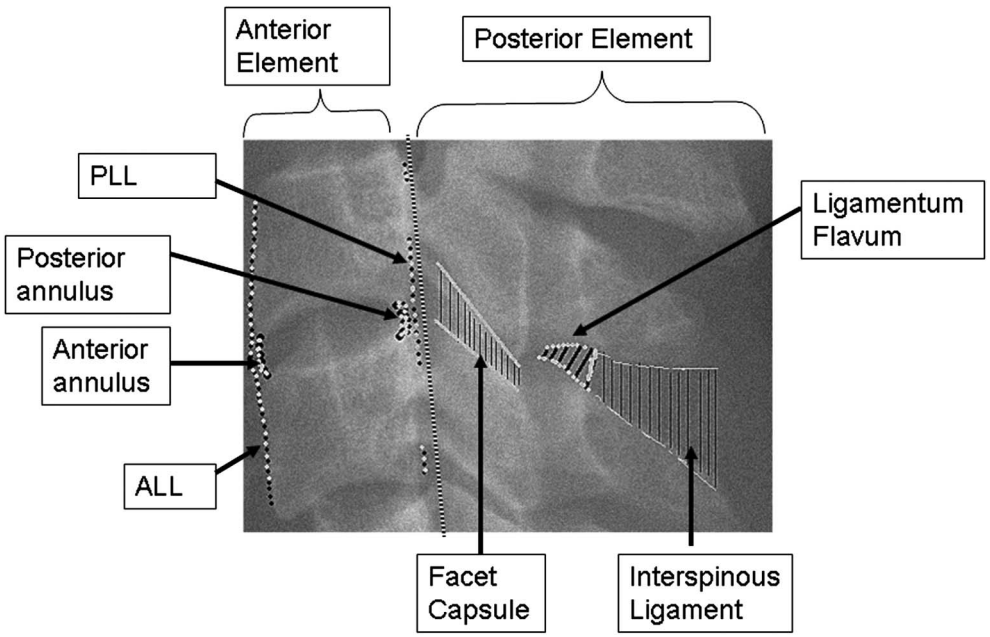

FIGURE 1. *Lateral cervical spine roentgenogram depicting approximate anatomical location of the main discoligamentous structures contributing to physiological stability of a single motion segment.*

fracture most frequently occurred at C5/6 with the C5 body sustaining the CF injury.

a. CF stage 1: Blunting of the anterior superior vertebral margin was seen in 36 patients, none of which had any evidence of neurological deficit and failure of posterior arch ligaments (Figure 4A).
b. CF stage 2: A "Beak" vertebral body and loss of height is characteristic of CF stage 2. Seven of the 165 patients had this radiographic pattern of injury, 1 of whom had central cord syndrome (Figure 4B).
c. CF stage 3: There is a fracture line through the "beak-form" vertebral body but there is no translation of the vertebral bodies. Two of the 4 patients in this category had a neurological deficit; 1 had a central cord injury, and the other 1 had a complete spinal cord injury (Figure 4C).
d. CF stage 4: Patients in CF stage 4 had less than 3 mm translation of the fractured bodies. Of 8 patients in this category, 2 had central cord syndrome, 1 had a partial lesion, and 3 had a complete spinal cord injury (Figure 4D).
e. CF stage 5: There is more than 3 mm of translation of the vertebral bodies. One of 11 patients with CF stage 5 had a central cord injury and the remaining 10 had complete spinal cord injuries. In CF stage 5, the posterior aspect of the anterior element ligaments and the entire posterior arch ligaments are disrupted (Figure 4E).

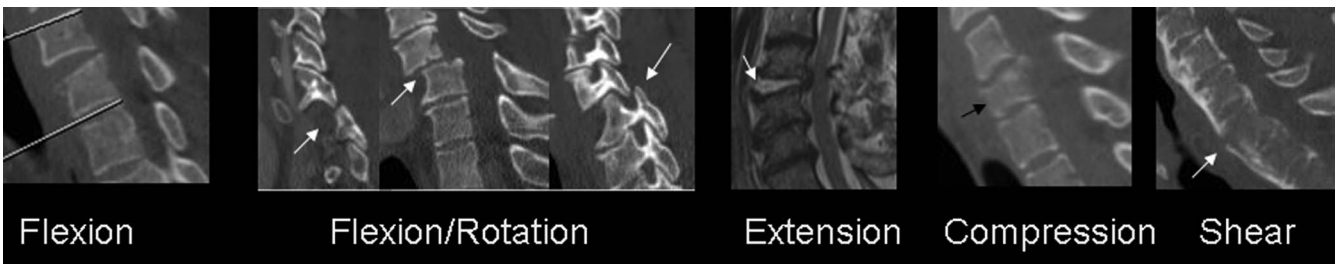

FIGURE 2. *Five different patterns of osseous and ligamentous injuries of the cervical spine proposed by Holdsworth. Sagittal reformatted computed tomography depicts Flexion, Flexion/Rotation, Compression and Shear injuries to the cervical spine. Reformatted T2W magnetic resonance imaging shows a typical example of Extension injury to the subaxial spine with disruption of the disc space and ALL.*

Copyright © Congress of Neurological Surgeons. Unauthorized reproduction of this article is prohibited.

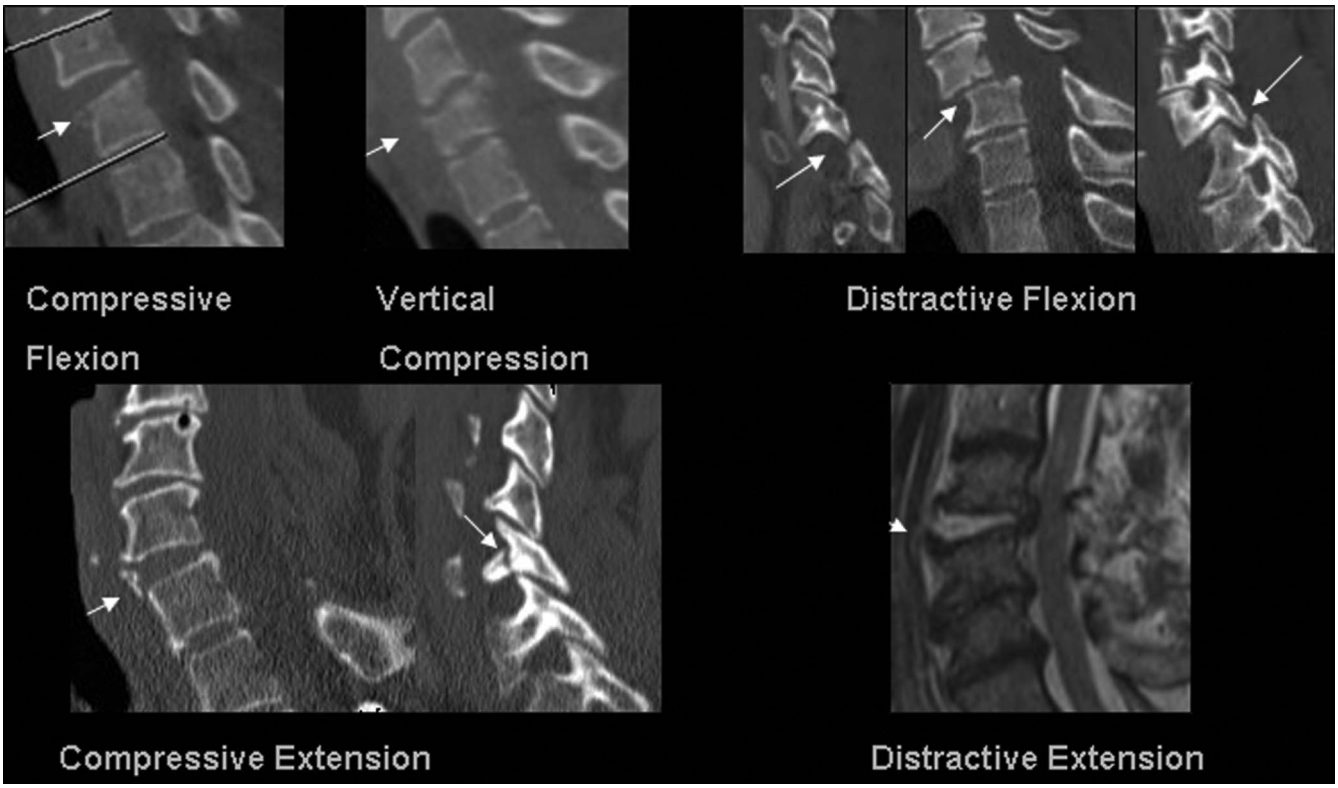

FIGURE 3. *Reformatted computed tomography (Compressive Flexion, Vertical Compression, Distractive Flexion and Compressive Extension) and magnetic resonance (MR) views (Distractive Extension) of the Mechanistic Classification of Allen and associates. Each phylogeny can have several stages of injuries.*

Vertical Compression (VC)

In vertical compression, the compressive force is transmitted to the cervical spine with the neck in a neutral position. In the series of 165 patients reported by Allen et al, 14 had vertical compression. Of the 14, 5 were in stage 1, 4 were in stage 2, and 5 were in stage 3.

a. VC stage 1: There is a "cupping" deformity of either the superior or the inferior endplate, without evidence of ligamentous failure. One of 5 patients had central cord syndrome.
b. VC stage 2: There is a "cupping" deformity of both endplates. None of the 4 patients in this series had a neurological deficit (Figure 5A).
c. VC stage 3: There is extensive fragmentation and bursting of the vertebral body in this category. The posterior part of the body may be bulging into the canal and the ligamentous structures may or may not be disrupted. Three of 5 patients in this stage had complete cord injury (Figure 5B).

Distractive Flexion (DF)

In distractive flexion injury, vector force is transmitted to the occiput while the neck is in flexion. Sixty-one of the 165 patients in this series had DF injuries. In descending levels in the subaxial spine, there is an increase in stage and the degree of severity of neurological deficit with the C6/7 interspace most commonly involved in DF stage 4 and with the greatest number of complete injuries. Fifty-seven percent of DF stage 4 occurred at C6/7. The DF category is a typical example of tension-shear of the posterior arch ligaments.

a. DF stage 1: There is facet subluxation in flexion with divergence of the spinous processes. Twelve of 61 patients in the DF category had DF stage 1 injuries (Figure 6).
b. DF stage 2: There is a unilateral facet dislocation (locked facet, interlocked facet) with varying degrees of posterior arch ligamentous failure. Rotary listhesis may be seen in the injured motion segment (Figure 7A).
c. DF stage 3: In this stage there is a bilateral facet dislocation with a degree of listhesis of up to 50%. Seventeen of 61 patients in this series had DF stage 3 injuries (Figure 7B).
d. DF stage 4: There is extreme translation of 1 vertebral body on the other 1, hence "floating vertebra," and there are bilateral locked facets. There is significant failure of the posterior arch ligaments and there may be significant injury to the posterior arch (Figure 7C).

Compressive Extension (CE)

In CE, there is a blow to the forehead or face that forces the neck into extension and thrusts the head toward the torso. The major

Copyright © Congress of Neurological Surgeons. Unauthorized reproduction of this article is prohibited.

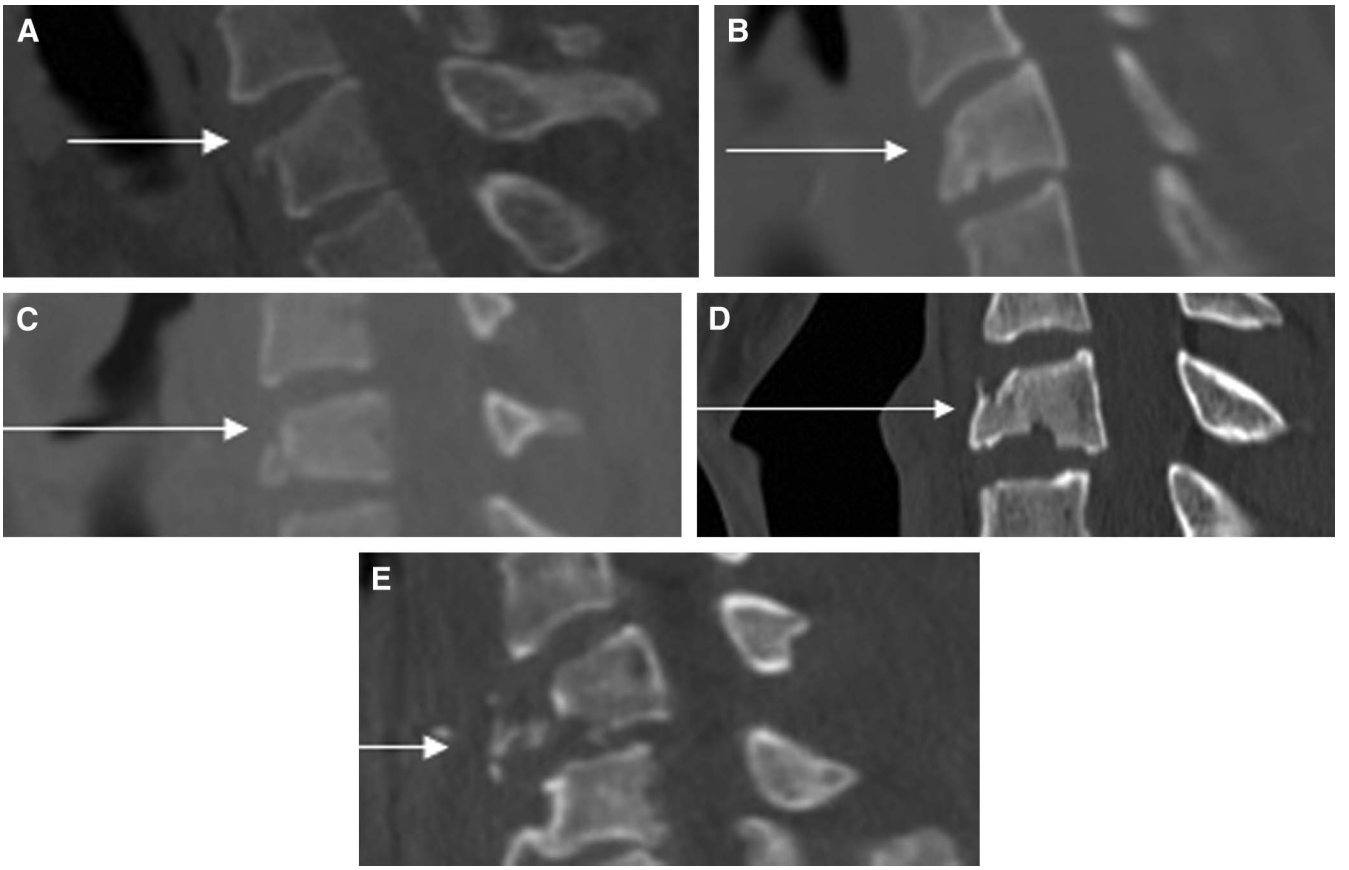

FIGURE 4. *Reformatted sagittal computed tomographic views (**A-E**) of cervical spine indicating compressive flexion (CF) phylogeny stages 1 to 5 of Allen et al Classification. CF stage 1 (**A**) is associated with blunting of the antero-superior end plate of the vertebral body. In CF stage 2 (**B**) there is a "beak-shape" deformity of the vertebral body without translation. In CF stage 3 (**C**) there is a "broken beak" of the vertebral body without translation. CF stage 4 (**D**) indicates a broken beak with up to 3 mm translation and in CF stage 5 (**E**) we have a broken vertebral body with more than 3 mm translation. Stages 4 and 5 are very much reminiscent of "teardrop" fractures.*

injury vector stresses posterior elements in compression. There is fracture or impaction of the posterior arch. Forty of the 165 cases in the Allen series suffered from CE with stage 1 as the most frequent (32 cases). Although theoretically sound, the authors did not present any CE stage 3 or CE stage 4 cases. The majority of CE stage 1 and CE stage 2 injuries were concentrated at the C6/C7 motion segment.

a. CE stage 1: Unilateral fracture of an articulating process, combined unilateral pedicle and laminar fracture (floating lateral mass) or combined pedicle and articulating process fractures are grouped in CE stage 1. There may be slight rotary listhesis of subjacent bodies. The majority of patients with CE stage 1 injury had no deficit. However, 8 patients did suffer from radiculopathy, 4 from partial spinal cord injuries, and 1 from a complete spinal cord injury (Figure 8A).
b. CE stage 2: Pathology in CE stage 2 is a bilaminar fracture of the posterior arch that could occur at multiple levels. Five of 40 cases in this report had a CE stage 2 injury.
c. CE stages 3 and 4: There are bilateral vertebral arch fractures at the corners (eg, facets, pedicles or laminae). In CE stage 4, but not in CE stage 3, there is partial vertebral body width displacement anteriorly. Allen et al did not encounter any patients in this category (Figure 8B).
d. CE stage 5: Two motion segments are involved with bilateral posterior arch fractures and full anterior displacement of 1 vertebral body on the other. Three patients in this series had CE stage 5. Despite significant injury to 2 subjacent motion segments, none of the 3 patients in this series had a complete spinal cord injury (Figure 9).

Distractive Extension (DE)

In DE, the neck is extended and the vector force is applied over the anterior calvarium or face. This is typically seen in the elderly who fall on their faces from a sitting or standing position. There is widening of the disc space or a transverse non-deforming fracture of the vertebral body. Nine of 165 patients in this series had DE. The investigators believed the incidence of this entity is underreported (Figure 10).

a. DE stage 1: In DE stage 1, there is widening of the disc interspace with possible chip fracture of the anterior lips of the

Copyright © Congress of Neurological Surgeons. Unauthorized reproduction of this article is prohibited.

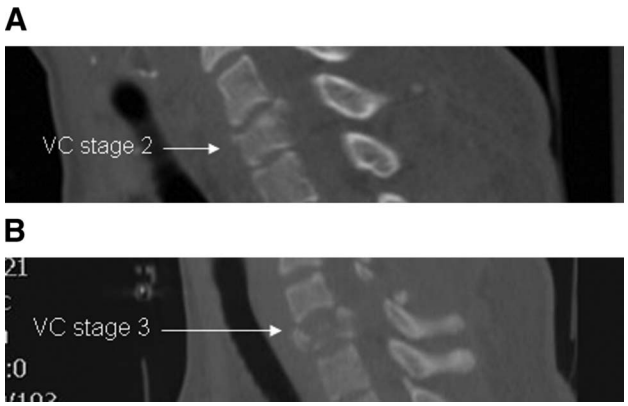

FIGURE 5. *Reformatted sagittal computed tomography views of cervical spine indicating vertical compression (VC) fracture stages 2 and 3 of Allen et al Classification. In VC stage 2 (A) there is cupping of superior and inferior end plates of C6 vertebral body and in VC stage 3 (B) there is significant compression fracture of the vertebral body with protrusion of bone fragments into the spinal canal. The latter is an example of a burst fracture.*

cephalad or caudad vertebrae. There were 2 patients in this series demonstrating this finding; neither had a neurological deficit.

b. DE stage 2: In addition to a widened disc space, there is failure of the posterior arch ligaments, with an added opportunity for spinal cord injury. Seven of 9 patients had DE stage 2 and all except 1 had a neurological deficit (Figure 10).

Lateral Flexion (LF)

A major compressive injury vector (slow forced flexion of the head towards 1 shoulder) on 1 side causes vertebral arch fracture and a minor distractive injury vector on the opposite side produces asymmetric compression of 1 motion segment (LF stage 1). In LF stage 2, in addition to an ipsilateral compression fracture of the posterior arch, there is displacement of 1 body on the other. Five of 165 patients in this series were classified in this category, with 3 in stage 1 without deficit, and 2 in stage 2 with no deficit, 1 of whom had a complete spinal cord injury.

In summary, Allen's classification system for subaxial cervical spine fractures provides more mechanistic detail than that proposed by Holdsworth, but the utility of such detail remains unknown. Attempt at measurement of reliability has been undertaken and the intraclass correlation coefficient is only 0.53.[38] The additional intricacies make the system more complicated and likely explain why, despite having been published almost 30 years ago, this classification system is not widely used.

Harris Classification

Based on biomechanical, cadaveric, and pathological evidence that vector forces along the "central coordinating system" are fundamental determinants of cervical spine injuries, Harris and his colleagues introduced yet another mechanistic classification

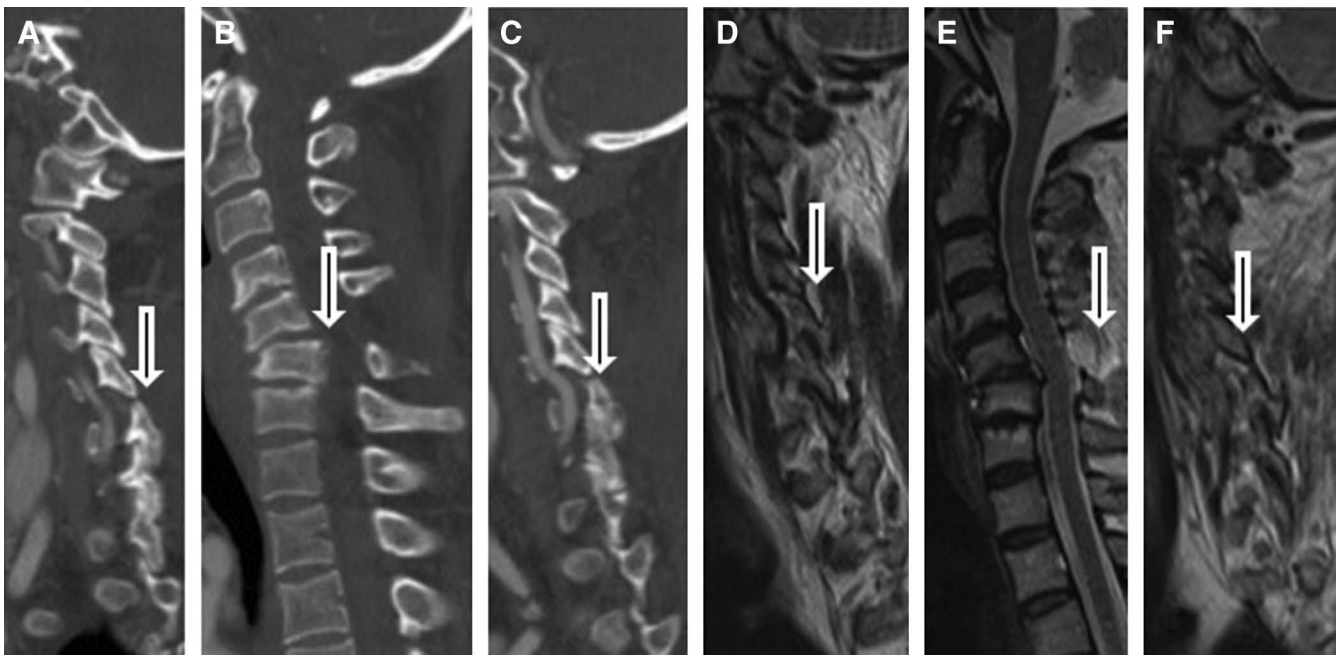

FIGURE 6. *Sagittal reformatted views of cervical spine indicating distractive flexion stage 1 phylogeny of Allen et al Classification (A, B, C) associated with significant ligamentous injury (D, E, F).*

Copyright © Congress of Neurological Surgeons. Unauthorized reproduction of this article is prohibited.

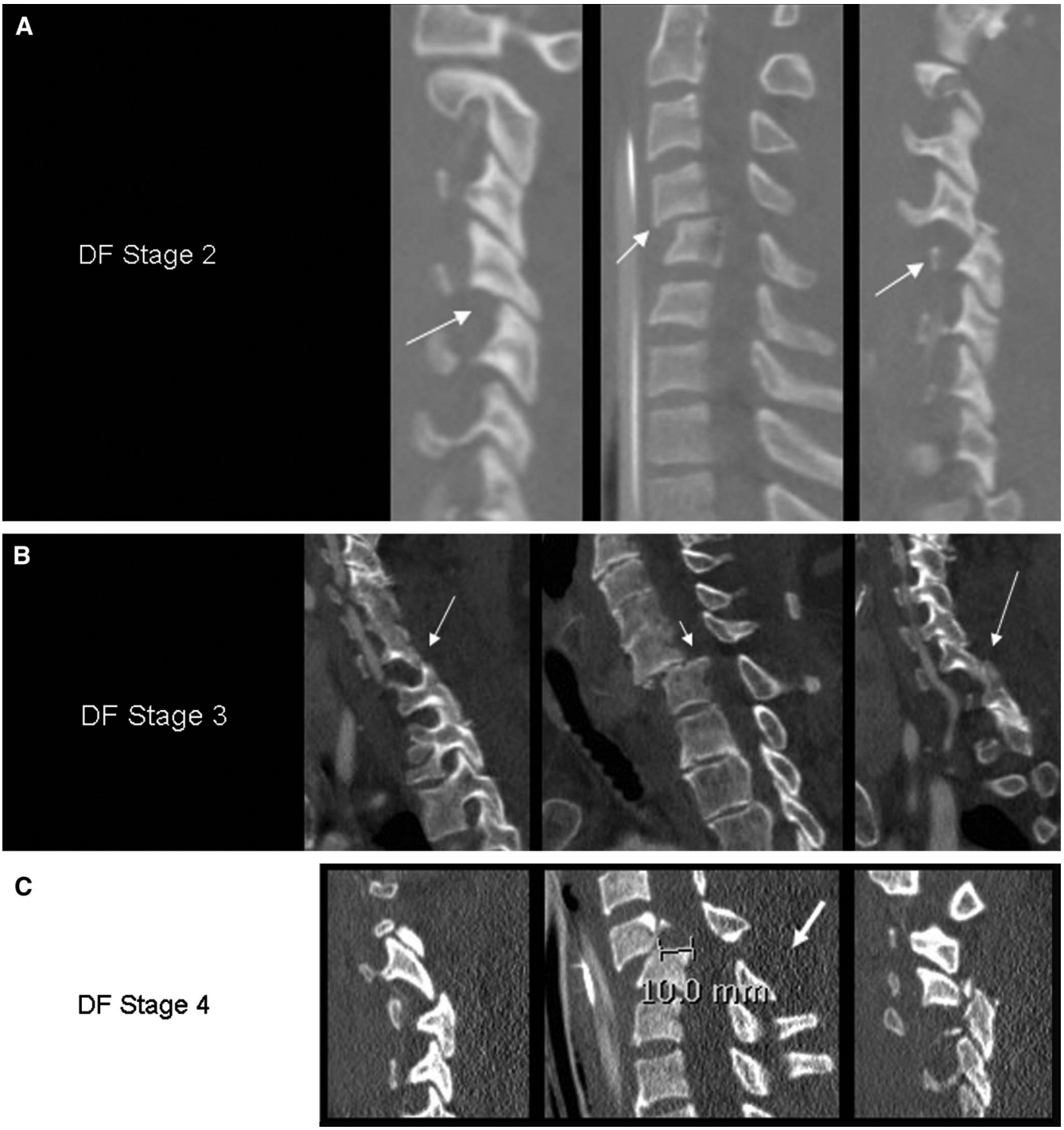

FIGURE 7. *Reformatted sagittal computed tomography views of cervical spine indicating distractive flexion (DF) stages 2 to 4 of Allen et al Classification. In DF stage 2 (A), there is unilateral locked facets. In DF stage 3 (B) facets are bilaterally locked with partial translation of the rostral vertebral body and in DF stage 4 (C) there is significant translation of the rostral vertebral body in conjunction with bilateral locked facets.*

Copyright © Congress of Neurological Surgeons. Unauthorized reproduction of this article is prohibited.

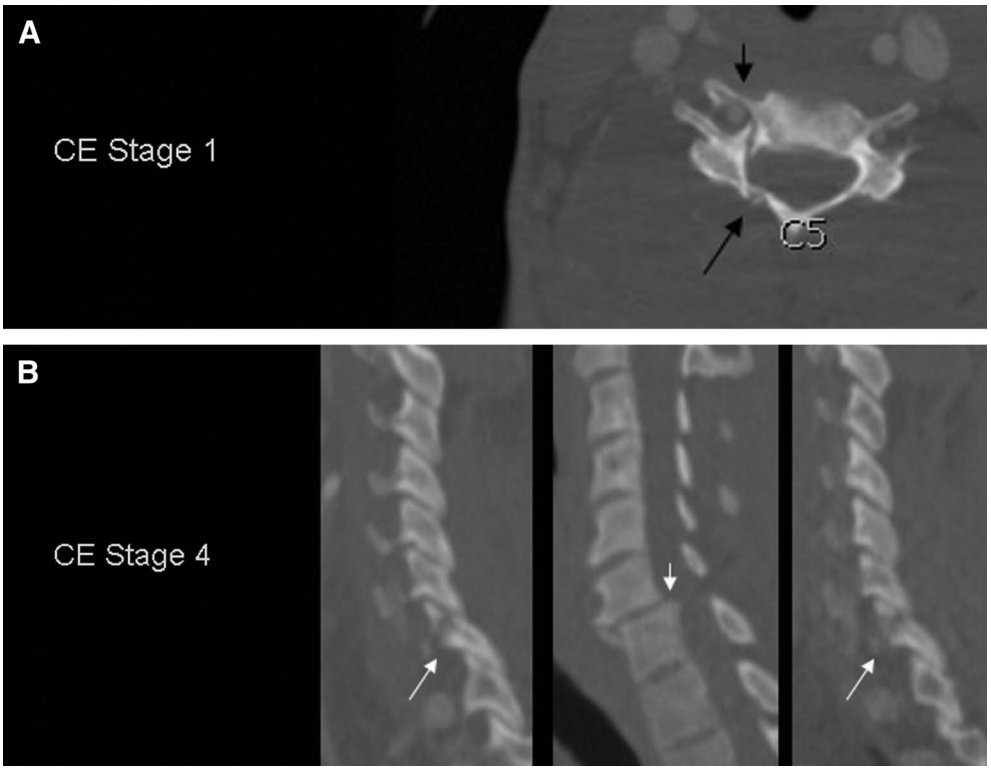

FIGURE 8. *Reformatted axial computed tomography indicating a typical floating lateral mass of C5 vertebral body compatible with compressive extension (CE) stage 1 (**A**), and reformatted sagittal computed tomography views of cervical spine indicating fracture of the superior articulating processes of C7 bilaterally compatible with CE stage 4 of Allen et al Classification (**B**).*

system for cervical spine fractures and dislocations in 1986.[2] This classification was also derived from data from the literature, and from clinical and radiographic observations. Major vector forces were flexion, extension, rotation, vertical compression, and lateral bending. A combination of vector forces such as flexion-rotation, extension-rotation, and lateral bending may produce added varieties of injuries. It was believed that specific vector forces and the magnitude of causative force determine groups of injuries that could be used in a new classification.

Flexion

a. Anterior subluxation (hyperflexion sprain): Flexion vector forces along the Z-axis produce bilateral disruption of posterior ligamentous complex, including the joint capsules. On radiographs, there is widening of the interspinous ligament (Figure 11). There is a 30 to 50% chance of delayed dislocation if not managed properly. This category is identical with distractive flexion stage 1 described by Allen et al.
b. Bilateral interfacetal dislocation: In this category, there is dislocation or locking of both facet joints. There may be evidence of translation of up to 50%. Anterior and posterior ligamentous complexes are disrupted, producing complete instability of the involved motion segment. In the Allen et al classification, this pathology is referred to as distractive flexion injury stage 3 (Figure 7B).
c. Simple wedge (compression) fracture: In this class of injuries, the body of the involved vertebra assumes a wedge deformation. PLC may or may not be disrupted. In the Allen et al classification, this category ranged from compressive flexion injury stages 1 to 3 as described above (Figure 4A-C).
d. Clay-shoveler (coal-shoveler) fracture: a vertical fracture through the spinous processes of C6, C7 and T1 is the result of forced flexion of the neck with intense tightening of interspinous and supraspinous ligaments.
e. Flexion teardrop fracture: The degree of flexion and anatomical injury in this category is quite substantial. There is a triangular fracture of the body with encroachment into the spinal canal (Figure 4D-E). Anterior ligamentous complex (ALC) and PLC are both disrupted and there is a flexion deformity of the cervical spine at that motion segment. Neurological injury is severe, and in the Allen et al classification, this category is designated as compressive flexion stages 4 and 5.

Copyright © Congress of Neurological Surgeons. Unauthorized reproduction of this article is prohibited.

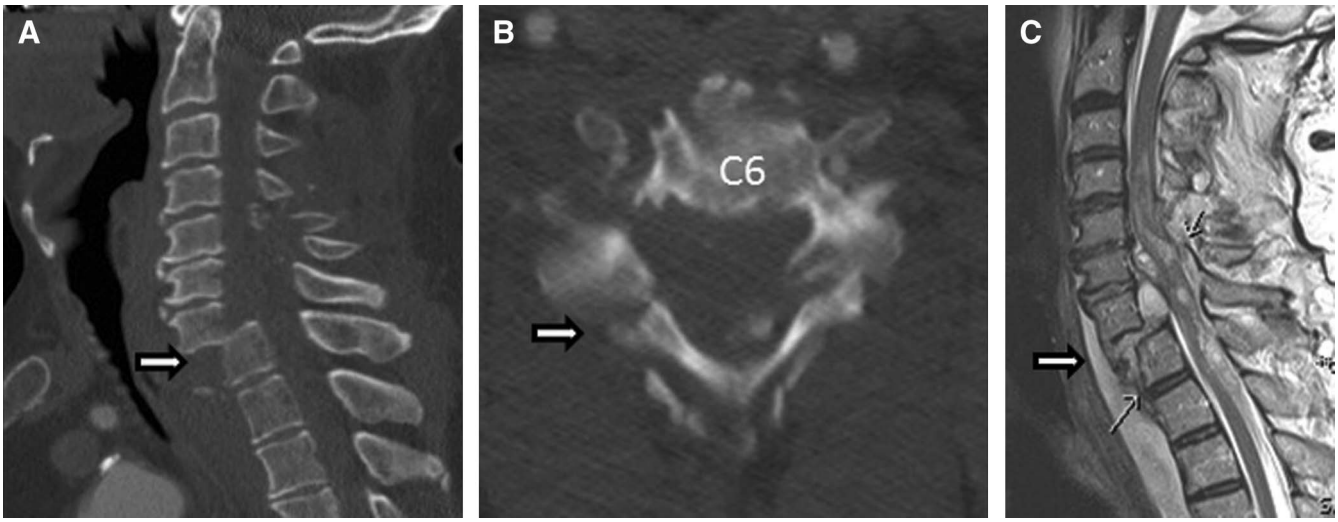

FIGURE 9. *73-year-old male who sustained a free fall down a flight of stairs with his forehead striking a dry wall. Reformatted Sagittal views of CT (**A**) and MRI (**C**) and reformatted CT axial view (**B**) of C6 indicate translation and disruption of posterior arches at C6. This patient also had fractures of posterior arch at C5 and C7 (**A** and **C**). ASIA motor score at admission was 14 and ASIA Impairment Scale (AIS) A. The findings on imaging studies and the history were compatible with a compressive extension injury phylogeny Stage 5 of Allen Classification.*

Flexion-Rotation

Unilateral interfacetal dislocation: A combination of major forces of flexion and rotation is the main pathogenetic mechanism in this category of cervical spine injury. This pattern of injury is also referred to as unilateral locked facet. There may be less than 50% translation of the bodies of the involved motion segment. The ligamentous complex is usually partially damaged. Allen et al designated this injury as distractive flexion stage 2 (DFS2, see above). The locked superior and inferior articulating processes may have small splinter fractures at the tip (Figure 7A).

Extension-Rotation

Pillar fracture: Extension and impaction of the articulating processes in Z-axis results in fracture of the articulating processes. In the Allen Classification, this category is referred to as compressive extension stage 1 (see above). There is no translation

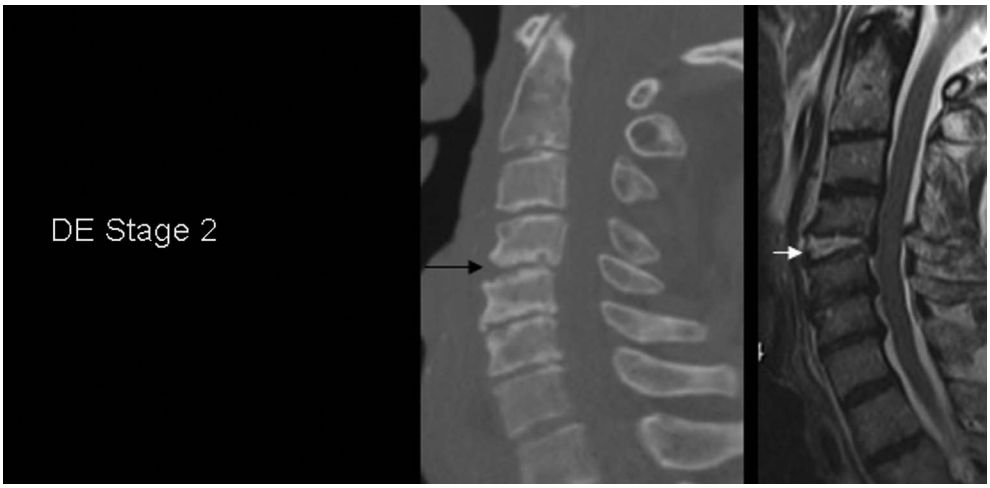

FIGURE 10. *Sagittal reformatted views of cervical spine indicating distractive extension stage 2 of Allen Classification.*

Copyright © Congress of Neurological Surgeons. Unauthorized reproduction of this article is prohibited.

FIGURE 11. *Mildest form of flexion injury proposed by Harris. Sagittal angulation associated with increased interspinous ligament is conjunction with disruption of capsular ligaments.*

and the patient may have radicular symptoms because of impaction upon the neural foramen involved (Figure 8A).

Vertical Compression

a. Jefferson fracture of the atlas: In this class of upper cervical spine injuries, vertical compression along the Y-axis will fracture the C1 arch and lateral dislocation of C1 lateral masses.
b. Burst (bursting, dispersion, axial loading) fracture: Translation of vector forces along the Y-axis via the occipital condyles or sacrum when the cervical spine is in a neutral position will result in a burst fracture with possible retropulsion of fragmented bone into the spinal canal. There may be a bilaminar fracture of the posterior arch. In plain radiographs, a straight cervical spine will differentiate this injury from a tear drop fracture (CF stages 4 and 5), which is a flexion injury. In the Allen Classification, a burst fracture is under the vertical compression category and has a stage 3 character (VCS3, see above) (Figure 5B).

Hyperextension

a. Hyperextension dislocation: Extreme vector forces in the Z-axis will disrupt the ALL and intervertebral disc and put tension on the PLL. There may be end plate avulsion fractures (in up to 60%) of the involved motion segment. Some translation of the vertebral bodies without fracture of the posterior arch is not unusual. Allen et al classified the injury as distractive extension stage 2 (DES2, see above) (Figure 10).
b. Avulsion fracture of anterior arch of the atlas: Hyperextension vector force against the anterior tubercle of atlas via intact longus colli and the atlantoaxial ligament may cause a horizontal fracture of atlas.
c. Extension teardrop fracture of the axis: Translation of hyperextension vector forces via an intact ALL can result in an avulsive triangular fracture of antero-inferior portion of C2. This phenomenon is especially prevalent in patients with cervical spondylosis and osteopenia.
d. Fracture of the posterior arch of the atlas: Impaction of the posterior arch of the atlas between the occiput and the posterior arch of C2 during hyperextension is considered to be the pathogenic mechanism behind this fracture.
e. Laminar fracture: Laminar fractures were considered as compressive extension injury stage 2 (CES2).
f. Traumatic spondylolisthesis (hangman's fracture): This is the classic bilateral fracture of the pars interarticularis of C2 in extreme hyperextension.
g. Hyperextension fracture-dislocation: Extreme hyperextension may cause fracture of the posterior arch through the lateral masses and facets, and in severe degrees, dislocation of 2 subjacent motion segments. This category of fractures corresponds to Allen et al's compressive extension stages 3, 4, and 5 (CES4-5, see above) (Figure 9).

Lateral Flexion

Uncinate process fracture: This fracture occurs along the X-coordinate by extreme lateral flexion of the cervical spine.

Diverse or Imprecisely Understood Mechanisms

a. Atlanto-occipital dissociation: These are described in detail elsewhere in this publication. The exact pathogenic mechanisms of atlantooccipital and atlantoaxial dissociation injuries are unknown.
b. Odontoid fractures: Horizontal transmission of vector forces, flexion, extension, and rotation, from the skull base into the

Copyright © Congress of Neurological Surgeons. Unauthorized reproduction of this article is prohibited.

odontoid process may cause odontoid fractures. These are described in detail elsewhere in this publication.

In summary, Harris added to the classification systems already proposed by Holdsworth and Allen et al.[2,3,7] However, much like the Allen classification system, this 1 is highly detailed with respect to presumed injury mechanism, yet has questionable utility in guiding treatment or predicting outcome. Similar to the Holdsworth and Allen systems, the Harris classification system, when subjected to a validation process by Vaccaro et al,[38] demonstrated an intraclass correlation coefficient of only 0.42. Nonetheless, the descriptive components of this system that describe the anatomic areas of failure (eg, bilateral facet dislocation) have been widely adopted and are commonly used as a means of describing subaxial cervical spine trauma.

White and Panjabi Clinical Checklist

In 1990, White and Punjabi described a formula for evaluating fracture stability. Under normal physiological conditions, cervical spine movements are smooth, effortless, pain-free, and do not produce neurological symptoms. Two fundamental structures of cervical motion segments facilitate abnormal kinematics: discoligamentous complex and the articulating facet joints.[7,38,39,41,42] White and Panjabi's extensive biomechanical investigations reproduced the share of each motion segment in maintaining stability. Based on these cadaveric experiments, ALL and PLL best maintained the stability of the anterior element, and joint capsules and the anatomy of facets were most important in maintaining posterior stability (Figure 1).

The stability check list (Table 1) introduced by White and Panjabi was based on these studies.[43] One should consider the fact that White and Panjabi's checklist was based on radiographs, before the widespread use of CT and MRI. Similarly, some maneuvers, such as stretch testing or dynamic studies, may not be compatible with the present standards of cervical spine clearance in patients with traumatic brain or cervical spine injuries.[11,22,28,29,32,44-52] Nonetheless, many of the principles for determining stability upon which the checklist is built remain widely utilized in clinical practice today, albeit in a less formal manner. The checklist has never been validated nor its reliability measured.

CSISS

In 2007, Anderson[35] and a working group of the Spine Trauma Study Group (STSG) surgeons introduced a new classification system, the CSISS, which considers the premise that instability is not a binary status and that grades of instability must be defined, scored, and considered in any new classification. In this classification, the degree of discoligamentous injury is scored by the degree of skeletal displacement or osseous displacement on computed tomography. A cervical spine motion segment is divided into 4 columns: vertebral body, including ALL, annulus and PLL; right facet joint and capsule; left facet joint and capsule; and laminae including the spinous processes, pedicles, interspinous and supraspinous ligaments (Figures 1 and 12). Depending on the extent of skeletal or fracture line separation (0-5 mm), each column was given a weighted score of 0 to 5, therefore, collective scores of 0 to 20. Scores were given to a young male driver with distractive flexion stage 5 of Allen et al and complete spinal cord injury (Figure 7C). Right and left pillars were each given a maximum score of 5. Anterior column and posterior columns were also given each a score of 5 because of spondyloptosis and widening of the spinous processes of cervical vertebrae 4 and 5, and rupture of ligamentum flavum on the MRI. The total score in this case was 20. The patient had circumferential fusion to ensure long-term stability. Anderson et al recommended surgical fixation for all patients having a score of 7 or more. Validity and reliability of this classification were calculated after 15 surgeons reviewed the clinical and imaging studies of 34 patients. The mean intraobserver and interobserver intraclass correlation coefficients for 15 reviewers were 0.977 and 0.883, respectively. In addition, internal consistency can be inferred from the fact that the higher the score, the worse the injury—every injury over a score of 10 includes significant bony injury and neurological compromise.

Anderson's system provides a detailed analysis of fracture pattern and stability, which may be of use in guiding management decisions. An attempt at establishing reliability and validity has been published. However, the system is complicated, which may interfere with incorporation into routine practice.

TABLE 1. Stability Checklist as Suggested by White and Panjabi[a]

Diagnostic Checklist Elements	Point Value	Individual Clinical Value
Anterior elements destroyed or unable to function	2	
Posterior elements destroyed or unable to function	2	
Relative sagittal plane translation >3.5 mm+	2	
Relative sagittal plane rotation >11 degrees	2	
Positive Stretch test	2	
Cord damage	2	
Root damage	1	
Abnormal disc narrowing	1	
Dangerous loading anticipated		

[a]A total of 5 points or more = unstable + or a translation >20% of the anteroposterior diameter of the involved vertebrae.

Copyright © Congress of Neurological Surgeons. Unauthorized reproduction of this article is prohibited.

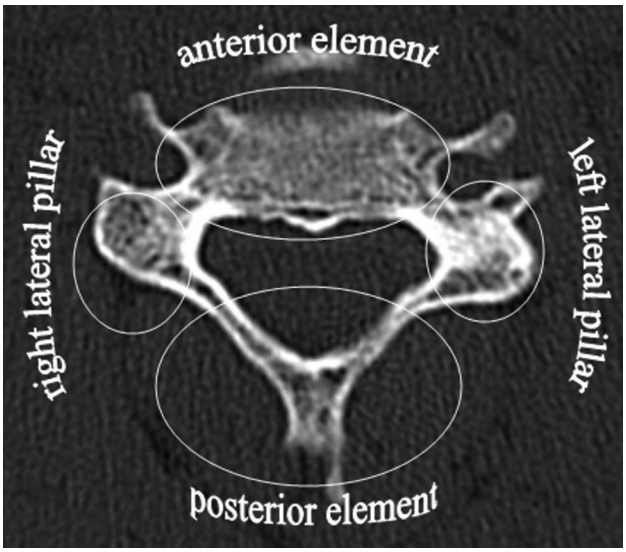

FIGURE 12. *Axial reformatted CT scan of the cervical spine depicting the 4-anatomical pillar concept of Anderson Classification.*

SLIC

SLIC was introduced in 2007 by Vaccaro and the STSG (Table 2).[36-38] The objective behind this classification was to quantify stability. The scale was based on literature reviews, consensus agreements, and limited validity determinations. In order to standardize and quantify injury severity and concomitant disrupted stability of the anterior and posterior elements of a motion segment, a weighted score was given to 3 parameters of morphology, discoligamentous complex (DLC) and neurological examination.

Morphology of a fracture or fracture/dislocation was assessed by a reformatted CT scan of the cervical spine, and the ligamentous injury was graded by review of the MRI or indirectly by computed tomography. Criterion, or more specifically concurrent, validity was determined by seeking agreement between SLIC and the Allen et al. Classification.[7] Compressive flexion injuries (Stages 1-3) were named as "compression" and vertical compression as "burst." Distractive flexion injuries (Stages 2, 3, and 4) were designated as "translation-rotation" and distractive flexion stage 1 as "distraction." Compressive extension stages 1, 2, and 3 are considered as compression, and distractive extension stage 1 was assigned to "distraction," as well. Compressive flexion stages 4 and 5, distractive extension stage 2, and compressive extension stages 4 and 5 were considered as translation-rotation. Reliability and validity of the SLIC and Severity Scale were calculated after 20 spine surgeons reviewed the clinical studies, including imaging, of 11 patients twice within 6 weeks. They graded the injury severity, instability, and recommendation for either surgical or non-surgical management. Inter-rater agreement as assessed by intraclass correlation coefficient of the morphology, DLC, and neurological status scores were 0.49, 0.57, and 0.87, respectively. Intra-rater agreement as assessed by intraclass correlation coefficient of the morphology, DLC, and neurological scores were 0.66, 0.75, and 0.90, respectively. There is somewhat of an implicit consistency in that the worse the injury, the more invasive the treatment, and the worse the patient's condition. In addition, agreement upon treatment indicated using the scoring system has been reported at 74%.

SLIC and Severity Scale in Detail

Morphology (*Figure 13*)

Compression. All the compression fractures, regardless of the flexed or neutral position of the neck at the time of axial loading, are grouped here. This includes the compression and burst fracture of Denis[1] or wedge and burst fractures of Harris[2] and Holdsworth.[3] Compressive flexion S1-3 and vertical compression fractures of Allen et al are grouped in this category.[7] Typically, teardrop fractures and CFS 4-5 with translation are not in this category; however, facet fractures (compressive extension stages 1-3) are allowed (Figure 13A-B).

Distraction. Morphology in this category of injury is anatomic dissociation of the motion segment in the vertical axis with significant injury to discoligamentous complex. In Harris et al[2] classification,

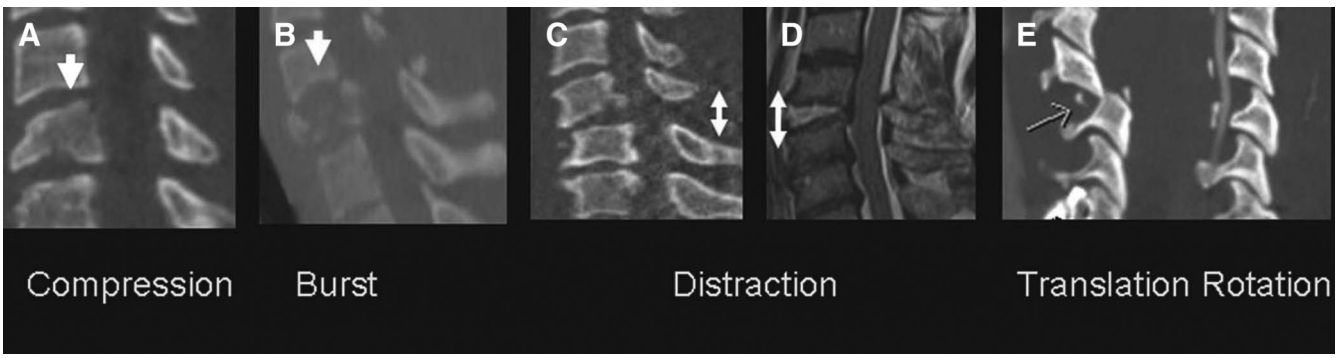

FIGURE 13. *Reformatted sagittal views of CT and MRI depicting the 4 components of morphology in the SLIC and Severity Scale.* **A-B**, *compression and burst.* **C-D**, *distraction.* **E**, *translation rotation.*

Copyright © Congress of Neurological Surgeons. Unauthorized reproduction of this article is prohibited.

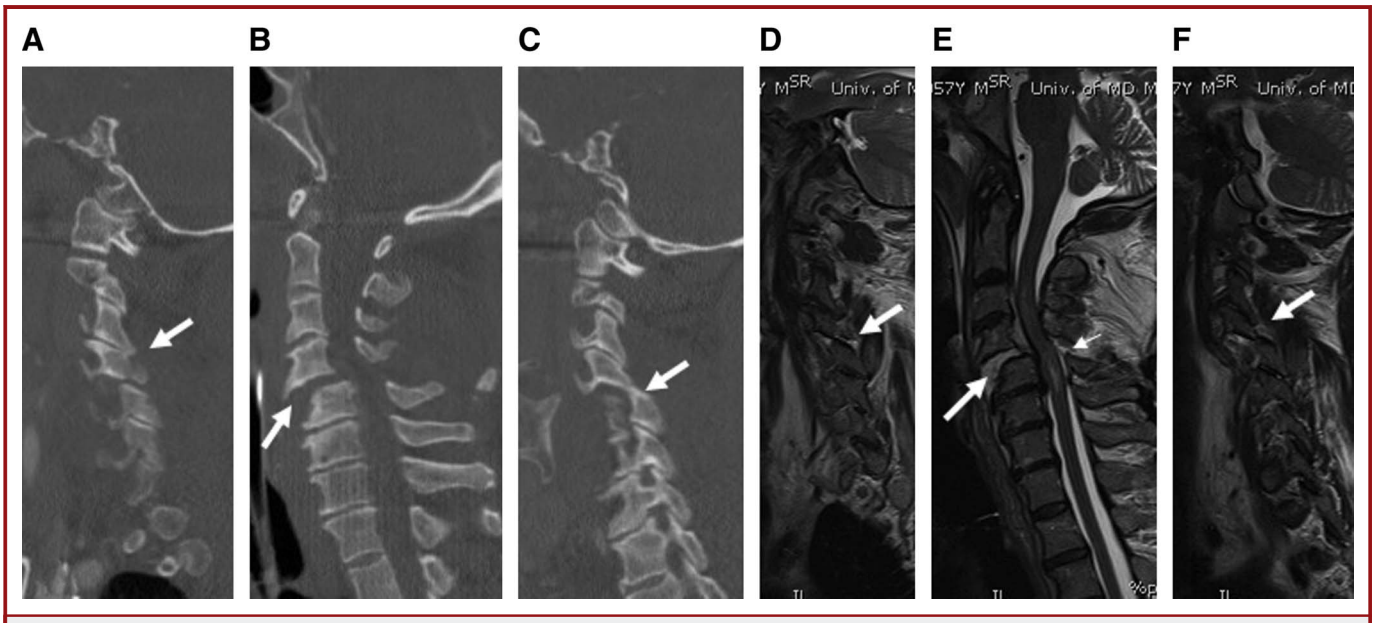

FIGURE 14. *57-y-o male with motor vehicle accident 8 hours prior to admission and manifesting incomplete spinal cord injury in form of acute traumatic central cord syndrome. The SLIC severity score was 10. Sagittal reformatted views of CT and MRI depicting unilateral facet subluxation on the right side (**A**, **D**), significant translation (**B**, **E**) and perched facet on left side (**C**, **F**). Magnetic resonance imaging showed complete disruption of ALL, annulus, PLL, ligamentum flavum, interspinous and supraspinous ligaments.*

this form of injury is hyperflexion sprain or facet subluxation (Figure 13C-D), and in the Allen et al[7] classification, the following injuries are included in this category: distractive flexion stage 1 (DFS1), vertical distraction, and distractive extension stage 1. Fractures of the posterior elements, such as facets and laminae or spinous processes, are not unusual in this category.

Translation Rotation. When evaluating the pattern of injury involving the vertebral bodies of a motion segment, a horizontal translation of more than 3.5 mm or a sagittal angulation of more than 11 degrees signifies major disruption of anterior or posterior ligamentous complex, hence, eligible for the highest[13] weighted score in calculating the SLIC and severity scale. There may or may not be bony damage to the spinal columns (Figure 13E and Figure 14).

Bilateral interfacetal dislocation (bilateral locked facets), flexion teardrop fractures, unilateral interfacetal dislocation, and hyperextension fracture-dislocations of Harris et al[2]; and compressive flexion stage 5, distractive flexion stages 2, 3 and 4, compressive extensions stages 4 and 5, and distractive extension of stage 2 in Allen et al[7] classification fall in this category of SLIC classification and severity scale (Figure 15).

Discoligamentous Complex

The integrity of discoligamentous complex is crucial for maintaining normal bony relationships and providing restraint for the cervical spine against deforming forces while allowing movement of the spine under normal physiological loads. ALL, anterior annulus, posterior annulus, PLL, ligamentum flavum, facet capsules, interspinous and supraspinous ligaments form major components of DLC (Figure 1).[9] The most important structure resisting hyperextension is the ALL, while the joint capsules resist hyperextension.[41,42] Roaf's study of the mechanics of spinal injuries indicated that it was impossible to produce DLC injury with extreme hyperflexion or hyperextension.[53,54] Evaluation of the integrity of the DLC is either by inference, such as locked facets (Figures 11 and 14), or by MRI evidence (Figure 14D-F). Using computed tomography, articular apposition of ≤50% (Figure 14C) or diastesis >2 mm through the facet joint is considered absolute evidence of facet joint disruption. Using T2 weighted or STIR sequences of MRI, one can easily pinpoint disruption of ALL, anterior annulus, disc interspace, PLL, posterior annulus and ligamentum flavum (Figure 14D-F). In patients with cervical spine injury and near normal looking morphology, at times there is sometimes swelling of the paravertebral tissues without clear-cut disruption of the ligaments. These observations are best classified as evidence of indeterminate ligamentous injury until a better understanding of this imaging finding is achieved.

SLIC Score Determination

By adding the maximum score determined and taking into consideration morphology, DLC status and neurology, a SLIC score is determined. The ultimate objective of the SLIC score is to determine the threshold for surgical intervention. SLIC scores 1 to 3 fall under the category of non-surgical and a score of 5 and above falls under the umbrella of surgical fixation. If a patient's SLIC score is 4, the surgeon may decide on either a non-operative or operative approach.

Copyright © Congress of Neurological Surgeons. Unauthorized reproduction of this article is prohibited.

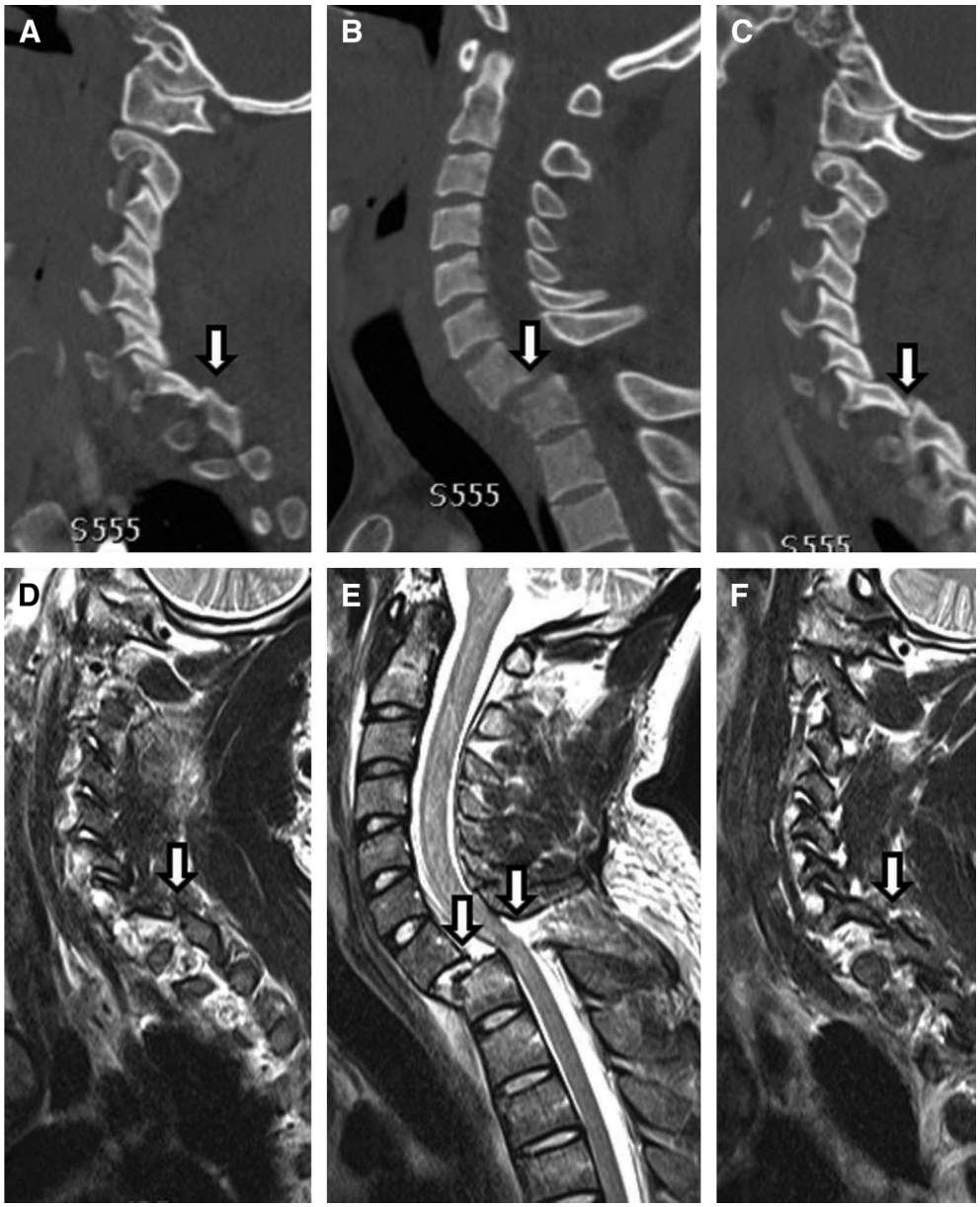

FIGURE 15. *25-year-old male construction worker who sustained a fall from a 25 meter-height. Reformatted sagittal CT and MRI indicate bilateral locked facets (**A**, **C**, **D**, **F**), complete disruption of DLC (**B**, **E**) and compression of spinal cord which has central hematomyelia (see text).*

Clinical Examples

A 25-year old male was admitted to the Trauma Resuscitation Unit (TRU) following a fall from a 25 m height. His American Spinal Injury Association (ASIA) motor score was 43 and ASIA Impairment Scale (AIS) A. Cervical spine computed tomography showed distractive flexion injury stage 3 of the Allen et al classification at the level of C7/T1 (Figure 15A-C arrows). MRI indicated complete disruption of discoligamentous complex (Figure 15D-F arrows). There was persistent spinal cord compression (modifier score 1). The total score in this case was 9. The patient was treated with circumferential (anterior cervical discectomy and fusion and posterior spinal fusion) fusion of the cervical spine. Morphology in this case is eligible for a score of 4 (translation/rotation), DLC a score of 2 (complete disruption), and neurology a score of 2 for complete spinal cord injury.

Copyright © Congress of Neurological Surgeons. Unauthorized reproduction of this article is prohibited.

TABLE 2. Subaxial Injury Classification and Severity Scale as Suggested by Vaccaro and Colleagues[37,38]

Sub-Axial Injury Classification Scale	Points
Morphology	
No abnormality	0
Compression	1
Burst	+1 = 2
Distraction (facet perch, hyperextension)	3
Rotation/translation (facet dislocation, unstable teardrop or advanced stage flexion compression injury)	4
Disco-ligamentous Complex (DLC)	
Intact	0
Indeterminate (isolated interspinous widening. magnetic resonance imaging signal change only)	1
Disrupted (widening of disc space, facet perch or dislocation)	2
Neurological Status	
Intact	0
Root injury	1
Complete cord injury	2
Incomplete cord injury	3
Continuous cord compression in setting of neurological deficit (NeuroModifier)	+1 = 1

The SLIC scale represents the first classification scheme to combine fracture morphology, discoligamentous integrity, and neurological deficit in an attempt to quantify subaxial fracture stability and management. The scale is simple and shows promise for ease of daily use. Partial validation has been performed, but further prospective studies are necessary to confirm reliability amongst different institutions and to establish validity in case management. Compared to the current gold standard, which is a simple descriptive expression of fracture/dislocations and management strategies that are impossible to validate, the SLIC system may be the first of many classifications aimed at scaling injury severity and therefore prescribing a graded system of surgical or conservative management.

TABLE 3. Evidentiary Table: Subaxial Injury Classification Systems

Citation	Description of Study	Evidence Class	Conclusions
Anderson,[35] *J Bone and Joint Surgery Am*, 2007	Report of a new cervical spine injury classification system featuring degrees of instability defined by a scoring system utilizing injury to 4 "columns" of the spine: anterior, posterior, and right and left facets.	I	The CSISS, Cervical Spine Injury Severity Score was shown to be reliable (intraclass correlation coefficients of 0.883 and 0.977 for interobserver and intraobserver, respectively). Internal consistency indicated by worsening of score reflecting worse injury.
Vaccaro,[38] *Spine*, 2007	Report of a novel Subaxial Spine Classification System that includes morphology of the anatomical injury, including the discoligamentous complex and neurological condition of the patient. In addition, this paper also assesses the reliability of earlier proposed systems, including the Allen and Harris scales.	I	This classification system (shown in Table 1) was shown to be reliable overall (overall intraclass correlation coefficient of 0.71). Internal consistency indicated by worsening of score reflecting worse injury. With respect to the Allen and Harris scales, the reliability was shown to be less than would be required to recommend use.
Harris,[2] *OrthopClin North Am*, 1986	This report introduced another mechanistic classification of cervical spine fractures and dislocations based on biomechanical, cadaveric and pathological evidence that vector forces along the "central coordinating system" are fundamental determinants of cervical spine injuries.	III	No measurement of reliability or validity were undertaken. (See Vaccaro above.)
Allen,[7] *Spine*, 1982	This study, based on findings in 165 patients with acute spinal cord injury, created a classification scheme based on the belief that translation of kinetic energy into fractures and dislocations is determined by 2 independent variables: injury vector and the posture of the cervical spine at the time of accident.	III	No measurement of reliability or validity were undertaken. (See Vaccaro above.)

Copyright © Congress of Neurological Surgeons. Unauthorized reproduction of this article is prohibited.

SUMMARY

The challenge confronting providers caring for patients with cervical spine traumatic injuries is how to quantify instability and create an algorithm of treatment in order to protect the spinal cord from further damage, prevent future spinal deformity and mitigate pain and discomfort.[7,38-40,54-61] Biomechanical, cadaveric, and autopsy studies have confirmed the importance of ligamentous integrity of anterior and posterior cervical spine elements for smooth, effortless movements of cervical spine under physiological loads.[9,39-42,54] Due to the lack of appropriate sectional imaging, previous investigators have resorted to major injury vectors (MIV) in order to construct descriptive mechanical classification of cervical spine injuries.[1-4,7,8,10,12,13,16,17,21-23,25,27,29,54,62-65] However, these systems are complicated and difficult to use; their clinical relevance is not intuitive. In addition, their reliability is low, and they probably do not add value to clinical research on spinal cord injury. The only suggestion might be to use the Harris classification system in addition to a more reliable classification for comparison with previously reported studies using this older scheme.

Anatomical injury severity is one of the major independent variables that needs to be quantified for future therapeutic trials. Two partially validated classification systems, the SLIC and severity scale and the CSISS, have tried to scale and score injury severity, taking advantage of sectional imaging.[35,37,38,59,60]

Key Issues For Future Investigation

Novel and quantifiable cervical spine injury classification systems that are easy to remember and can be utilized by different providers are needed in order to design appropriate treatment algorithms and better understand treatment effects of therapeutic trials. The SLIC and severity scale and CSISS classifications need further validation and reliability studies, with careful measurement of internal consistency.

Disclosure

The authors have no personal financial or institutional interest in any of the drugs, materials, or devices described in this article.

REFERENCES

1. Denis F. The three column spine and its significance in the classification of acute thoracolumbar spinal injuries. *Spine (Phila Pa 1976)*. 1983;8(8):817-831.
2. Harris JH Jr, Edeiken-Monroe B, Kopaniky DR. A practical classification of acute cervical spine injuries. *Orthop Clin North Am.* 1986;17(1):15-30.
3. Holdsworth F. Fractures, dislocations, and fracture-dislocations of the spine. *J Bone Joint Surg Am.* 1970;52(8):1534-1551.
4. Mirza SK, Mirza AJ, Chapman JR, Anderson PA. Classifications of thoracic and lumbar fractures: rationale and supporting data. *J Am Acad Orthop Surg.* 2002; 10(5):364-377.
5. Nicoll EA. Fractures of the dorso-lumbar spine. *J Bone Joint Surg Br.* 1949;31B(3): 376-394.
6. Braakman R, Vinken PJ. Unilateral facet interlocking in the lower cervical spine. *J Bone Joint Surg Br.* 1967;49(2):249-257.
7. Allen BL Jr, Ferguson RL, Lehmann TR, O'Brien RP. A mechanistic classification of closed, indirect fractures and dislocations of the lower cervical spine. *Spine (Phila Pa 1976)*. 1982;7(1):1-27.
8. Louis R. Spinal stability as defined by the three-column spine concept. *Anat Clin.* 1985;7(1):33-42.
9. White AA, Panjabi MM. Physical properties and functional biomechanics of the spine. In: *Clinical Biomechanics of the Spine*. Philadelphia, PA: Lippincott Williams And Wilkins; 1990.
10. Ackland HM, Cooper DJ, Malham GM, Stuckey SL. Magnetic resonance imaging for clearing the cervical spine in unconscious intensive care trauma patients. *J Trauma.* 2006;60(3):668-673.
11. Adams JM, Cockburn MI, Difazio LT, Garcia FA, Siegel BK, Bilaniuk JW. Spinal clearance in the difficult trauma patient: a role for screening MRI of the spine. *Am Surg.* 2006;72(1):101-105.
12. Ajani AE, Cooper DJ, Scheinkestel CD, Laidlaw J, Tuxen DV. Optimal assessment of cervical spine trauma in critically ill patients: a prospective evaluation. *Anaesth Intensive Care.* 1998;26(5):487-491.
13. Albrecht RM, Malik S, Kingsley DD, Hart B. Severity of cervical spine ligamentous injury correlates with mechanism of injury, not with severity of blunt head trauma. *Am Surg.* 2003;69(3):261-265.
14. Arnold PM, Brodke DS, Rampersaud YR, et al; Spine Trauma Study Group. Differences between neurosurgeons and orthopedic surgeons in classifying cervical dislocation injuries and making assessment and treatment decisions: a multicenter reliability study. *Am J Orthop (Belle Mead NJ).* 2009;38(10):E156-E161.
15. Baur A, Stabler A, Huber A, Reiser M. Diffusion-weighted magnetic resonance imaging of spinal bone marrow. *Semin Musculoskelet Radiol.* 2001;5(1):35-42.
16. Benzel EC, Hart BL, Ball PA, Baldwin NG, Orrison WW, Espinosa MC. Magnetic resonance imaging for the evaluation of patients with occult cervical spine injury. *J Neurosurg.* 1996;85(5):824-829.
17. Berne JD, Velmahos GC, El-Tawil Q, et al. Value of complete cervical helical computed tomographic scanning in identifying cervical spine injury in the unevaluable blunt trauma patient with multiple injuries: a prospective study. *J Trauma.* 1999;47(5):896-902.
18. Blackmore CC, Ramsey SD, Mann FA, Deyo RA. Cervical spine screening with CT in trauma patients: a cost-effectiveness analysis. *Radiology.* 1999;212(1):117-125.
19. Borchgrevink GE, Smevik O, Nordby A, Rinck PA, Stiles TC, Lereim I. MR imaging and radiography of patients with cervical hyperextension-flexion injuries after car accidents. *Acta Radiol.* 1995;36(4):425-428.
20. Brandt MM, Wahl WL, Yeom K, Kazerooni E, Wang SC. Computed tomographic scanning reduces cost and time of complete spine evaluation. *J Trauma.* 2004;56(5): 1022-1026.
21. Chiu WC, Haan JM, Cushing BM, Kramer ME, Scalea TM. Ligamentous injuries of the cervical spine in unreliable blunt trauma patients: incidence, evaluation, and outcome. *J Trauma.* 2001;50(3):457-463.
22. Como JJ, Thompson MA, Anderson JS, et al. Is magnetic resonance imaging essential in clearing the cervical spine in obtunded patients with blunt trauma? *J Trauma.* 2007;63(3):544-549.
23. D'Alise MD, Benzel EC, Hart BL. Magnetic resonance imaging evaluation of the cervical spine in the comatose or obtunded trauma patient. *J Neurosurg.* 1999; 91(1suppl):54-59.
24. Dekutoski MB, Hayes ML, Utter AP, et al. Pathologic correlation of posterior ligamentous injury with MRI. *Orthopedics*. 2010;33(1):53.
25. Emery SE, Pathria MN, Wilber RG, Masaryk T, Bohlman HH. Magnetic resonance imaging of posttraumatic spinal ligament injury. *J Spinal Disord.* 1989; 2(4):229-233.
26. Flanders AE, Schaefer DM, Doan HT, Mishkin MM, Gonzalez CF, Northrup BE. Acute cervical spine trauma: correlation of MR imaging findings with degree of neurologic deficit. *Radiology*. 1990;177(1):25-33.
27. Klein GR, Vaccaro AR, Albert TJ, et al. Efficacy of magnetic resonance imaging in the evaluation of posterior cervical spine fractures. *Spine (Phila Pa 1976)*. 1999; 24(8):771-774.
28. Menaker J, Philp A, Boswell S, Scalea TM. Computed tomography alone for cervical spine clearance in the unreliable patient—are we there yet? *J Trauma.* 2008;64(4):898-903.
29. Mirvis SE, Diaconis JN, Chirico PA, Reiner BI, Joslyn JN, Militello P. Protocol-driven radiologic evaluation of suspected cervical spine injury: efficacy study. *Radiology*. 1989;170(3 pt 1):831-834.
30. Rihn JA, Fisher C, Harrop J, Morrison W, Yang N, Vaccaro AR. Assessment of the posterior ligamentous complex following acute cervical spine trauma. *J Bone Joint Surg Am*. 2010;92(3):583-589.

Copyright © Congress of Neurological Surgeons. Unauthorized reproduction of this article is prohibited.

31. Tan E, Schweitzer ME, Vaccaro L, Spetell AC. Is computed tomography of nonvisualized C7-T1 cost-effective? *J Spinal Disord.* 1999;12(6):472-476.
32. Tehranzadeh J, Bonk RT, Ansari A, Mesgarzadeh M. Efficacy of limited CT for nonvisualized lower cervical spine in patients with blunt trauma. *Skeletal Radiol.* 1994;23(5):349-352.
33. Vaccaro AR, Falatyn SP, Flanders AE, Balderston RA, Northrup BE, Cotler JM. Magnetic resonance evaluation of the intervertebral disc, spinal ligaments, and spinal cord before and after closed traction reduction of cervical spine dislocations. *Spine (Phila Pa 1976)*. 1999;24(12):1210-1217.
34. Vaccaro AR, Rihn JA, Saravanja D, et al. Injury of the posterior ligamentous complex of the thoracolumbar spine: a prospective evaluation of the diagnostic accuracy of magnetic resonance imaging. *Spine (Phila Pa 1976)*. 2009;34(23): E841-E847.
35. Anderson PA, Moore TA, Davis KW, et al; Spine Trauma Study Group. Cervical spine injury severity score. Assessment of reliability. *J Bone Joint Surg Am.* 2007; 89(5):1057-1065.
36. Patel AA, Dailey A, Brodke DS, et al; Spine Trauma Study Group. Subaxial cervical spine trauma classification: the Subaxial Injury Classification system and case examples. *Neurosurg Focus.* 2008;25(5):E8.
37. Patel AA, Hurlbert RJ, Bono CM, Bessey JT, Yang N, Vaccaro AR. Classification and surgical decision making in acute subaxial cervical spine trauma. *Spine (Phila Pa 1976)*. 2010;35(21 suppl):S228-S234.
38. Vaccaro AR, Hulbert RJ, Patel AA, et al; Spine Trauma Study Group. The subaxial cervical spine injury classification system: a novel approach to recognize the importance of morphology, neurology, and integrity of the disco-ligamentous complex. *Spine (Phila Pa 1976)*. 2007;32(21):2365-2374.
39. Holdsworth FW. Fractures, common dislocations, fractures-dislocations of the spine. *J Bone Joint Surg Br.* 1963;45(1):6-20.
40. Holdsworth FW. Neurological diagnosis and the indications for treatment of paraplegia and tetraplegia, associated with fractures of the spine. *Manit Med Rev.* 1968;48(1):16-18.
41. White AA, Southwick WO, Panjabi MM. Clinical instability in the lower cervical spine: a review of past and current concepts. *Spine*. 1976;1(1):15-27.
42. White AA III, Johnson RM, Panjabi MM, Southwick WO. Biomechanical analysis of clinical stability in the cervical spine. *Clin Orthop Relat Res.* 1975;(109): 85-96.
43. White P, Seymour R, Powell N. MRI assessment of the pre-vertebral soft tissues in acute cervical spine trauma. *Br J Radiol.* 1999;72(860):818-823.
44. Crim JR, Moore K, Brodke D. Clearance of the cervical spine in multitrauma patients: the role of advanced imaging. *Semin Ultrasound CT MR.* 2001;22(4): 283-305.
45. Lockey AS, Handley R, Willett K. 'Clearance' of cervical spine injury in the obtunded patient. *Injury*. 1998;29(7):493-497.
46. Muchow RD, Resnick DK, Abdel MP, Munoz A, Anderson PA. Magnetic resonance imaging (MRI) in the clearance of the cervical spine in blunt trauma: a meta-analysis. *J Trauma.* 2008;64(1):179-189.
47. Nuñez DB Jr, Quencer RM. The role of helical CT in the assessment of cervical spine injuries. *AJR Am J Roentgenol.* 1998;171(4):951-957.
48. Richards PJ. Cervical spine clearance: a review. *Injury*. 2005;36(2):248-269.
49. Schaefer DM, Flanders AE, Osterholm JI, Northrup BE. Prognostic significance of magnetic resonance imaging in the acute phase of cervical spine injury. *J Neurosurg.* 1992;76(2):218-223.
50. Sees DW, Rodriguez Cruz LR, Flaherty SF, Cicero DP. The use of bedside fluoroscopy to evaluate the cervical spine in obtunded trauma patients. *J Trauma.* 1998;45(4):768-771.
51. Shaffer MA, Doris PE. Limitation of the cross table lateral view in detecting cervical spine injuries: a retrospective analysis. *Ann Emerg Med.* 1981;10(10):508-513.
52. Wollard S. Cervical spine clearance in adult trauma patients. *JAAPA*. 2003;16(4): 19-20.
53. Roaf R. A study of the mechanics of spinal surgery. *J Bone Joint Surg Br.* 1960; 42(4):810-823.
54. Roaf R. International classification of spinal injuries. *Paraplegia*. 1972;10(1): 78-84.
55. Dekutoski M, Cohen-Gadol AA. Distractive flexion cervical spine injuries: a clinical spectrum. In: Vaccaro AR, ed. *Fractures of the Cervical, Thoracic, and Lumbar Spine*. New York: Marcel Dekker Inc; 2003:191-205.
56. Dvorak MF, Fisher CG, Fehlings MG, et al. The surgical approach to subaxial cervical spine injuries: an evidence-based algorithm based on the SLIC classification system. *Spine (Phila Pa 1976)*. 2007;32(23):2620-2629.
57. Frankel HL, Hancock DO, Hyslop G, et al. The value of postural reduction in the initial management of closed injuries of the spine with paraplegia and tetraplegia. I. *Paraplegia*. 1969;7(3):179-192.
58. Clinical assessment after acute cervical spinal cord injury. In: Guidelines for the management of acute cervical spine and spinal cord injuries. *Neurosurgery*. 2002;50 (3 suppl):S21-S29.
59. Moore TA, Vaccaro AR, Anderson PA. Classification of lower cervical spine injuries. *Spine (Phila Pa 1976)*. 2006;31(11 suppl):S37-S43.
60. Patel RV, DeLong W Jr, Vresilovic EJ. Evaluation and treatment of spinal injuries in the patient with polytrauma. *Clin Orthop Relat Res.* 2004;(422):43-54.
61. Torg JS, Sennett B, Vegso JJ, Pavlov H. Axial loading injuries to the middle cervical spine segment. An analysis and classification of twenty-five cases. *Am J Sports Med.* 1991;19(1):6-20.
62. Denis F. Spinal instability as defined by the three-column spine concept in acute spinal trauma. *Clin Orthop Relat Res.* 1984;(189):65-76.
63. Katzberg RW, Benedetti PF, Drake CM, et al. Acute cervical spine injuries: prospective MR imaging assessment at a level 1 trauma center. *Radiology*. 1999; 213(1):203-212.
64. Nagel DA, Koogle TA, Piziali RL, Perkash I. Stability of the upper lumbar spine following progressive disruptions and the application of the individual internal and external fixation devices. *J Bone Joint Surg Am.* 1981;63(1):62.
65. Shanmuganathan K, Gullapalli RP, Zhuo J, Mirvis SE. Diffusion tensor MR imaging in cervical spine trauma. *AJNR Am J Neuroradiol.* 2008;29(4):655-659.

Copyright © Congress of Neurological Surgeons. Unauthorized reproduction of this article is prohibited.