Surgical Management of Giant Posterior Communicating Artery Aneurysms

Gregory J. Velat, MD
Joseph M. Zabramski, MD
Peter Nakaji, MD
Robert F. Spetzler, MD

Division of Neurological Surgery, Barrow Neurological Institute, St. Joseph's Hospital and Medical Center, Phoenix, Arizona

Correspondence:
Robert F. Spetzler, MD,
c/o Neuroscience Publications,
Barrow Neurological Institute,
St. Joseph's Hospital and Medical Center, 350 W Thomas Rd,
Phoenix, AZ 85013.
E-mail: neuropub@chw.edu

Received, August 3, 2011.
Accepted, January 4, 2012.
Published Online, January 24, 2012.

Copyright © 2012 by the Congress of Neurological Surgeons

BACKGROUND: Giant posterior communicating artery (PCoA) aneurysms (> 25 mm) are rare lesions associated with a poor prognosis and high rates of morbidity and mortality.

OBJECTIVE: To review the clinical results of giant PCoA aneurysms surgically treated at our institution, focusing on operative nuances.

METHODS: All cases of giant PCoA aneurysms treated surgically at our institution were identified from a prospectively maintained patient database. Patient demographic factors, medical comorbidities, rupture status, neurological presentation, clinical outcomes, and surgical records were critically reviewed.

RESULTS: From 1989 to 2010, 11 patients (10 women) underwent surgical clipping of giant PCoA aneurysms. Presenting signs and symptoms included cranial nerve palsies, diminished mental status, headache, visual changes, and seizures. Five aneurysms were ruptured on admission. All aneurysms were clipped primarily except 1, which was treated by parent artery sacrifice and extracranial-to-intracranial bypass after intraoperative aneurysm rupture. Perioperative morbidity and mortality rates were 36% (4 of 11) and 18.3% (2 of 11), respectively. Excellent or good clinical outcomes, defined as modified Rankin Scale scores ≤ 2, were achieved in 86% (5 of 6) of patients available for long-term clinical follow-up (mean, 12.5 ± 13.6 months).

CONCLUSION: Giant PCoA aneurysms are rare vascular lesions that may present with a variety of neurological signs and symptoms. These lesions can be successfully managed surgically with satisfactory morbidity and mortality rates. To the best of our knowledge, this is the largest surgical series of giant PCoA aneurysms published to date.

KEY WORDS: Aneurysm, Clipping, Giant, Posterior communicating artery, Surgery

Neurosurgery 71[ONS Suppl 1]:ons43–ons51, 2012 DOI: 10.1227/NEU.0b013e31824c05a0

Giant intracranial aneurysms (> 25 mm) are rare vascular lesions, constituting approximately 5% of all intracranial aneurysms.[1] The natural history of giant aneurysms is poor, with estimated morbidity and mortality rates ranging from 68% to 80% with conservative treatment.[2,3] For reasons yet to be elucidated, giant aneurysms involving the posterior communicating artery (PCoA) are particularly uncommon. Drake's[4] original series of 174 giant intracranial aneurysms included only 7 aneurysms (4%) arising from the communicating segment of the internal carotid artery (ICA). Given the proximity of these lesions to critical neural structures, giant PCoA aneurysms can manifest with headache, cranial nerve (CN) palsies, sensorimotor disturbances, visual deficits, and seizure activity.[1,5-7] We present our series of patients with giant PCoA aneurysms treated at our institution over the past 3 decades. We discuss surgical nuances and review perioperative clinical outcomes.

ABBREVIATIONS: CN, cranial nerve; **ICA,** internal carotid artery; **ICG,** indocyanine green; **MCA,** middle cerebral artery; **PCoA,** posterior communicating artery

Supplemental digital content is available for this article. Direct URL citations appear in the printed text and are provided in the HTML and PDF versions of this article on the journal's Web site (www.neurosurgery-online.com).

WHAT IS THIS BOX?
A QR Code is a matrix barcode readable by QR scanners, mobile phones with cameras, and smartphones. **The QR Code above links to Supplemental Digital Content from this article.**

PATIENTS AND METHODS

The Institutional Review Board at our institution approved this study. All patients treated at Barrow Neurological Institute harboring giant (> 25 mm) PCoA aneurysms were reviewed from a prospectively

Copyright © Congress of Neurological Surgeons. Unauthorized reproduction of this article is prohibited.

maintained patient database. Patient demographic factors and neurological presentations, including aneurysm rupture status, were analyzed. Initial Hunt-Hess scores and Fisher bleeding patterns were determined for all patients who presented with ruptured aneurysms. Aneurysm size was determined by calculating maximal cross-sectional diameters from all available imaging studies, including conventional digital subtraction angiography, noncontrasted computed tomography (CT) scans of the head (in cases with significant aneurysmal calcification), magnetic resonance imaging scans (for giant aneurysms associated with significant thrombus), and CT or magnetic resonance angiography. All surgeries were performed by senior surgeons at our institution. Detailed chart reviews were performed to analyze each patient's hospital course and perioperative (30-day) outcomes. Long-term clinical follow-up was attempted for each patient through review of medical records and/or patient telephone interviews.

RESULTS

Eleven patients (10 women) underwent surgical treatment of a giant PCoA aneurysm during the study period spanning 1989 to 2010. Patient demographic information, aneurysm size, aneurysm laterality, rupture status, presenting Hunt-Hess score, initial Fisher grade, presenting neurological status, medical comorbidities, details regarding surgical intervention, hospital course, and discharge neurological status are presented in Table 1. Three patients had CN palsies on admission. Patient 1 presented with an ipsilateral oculomotor palsy. Patient 2 suffered bilateral CN VI palsies after rupture of a giant right PCoA aneurysm that gradually improved after placement of an external ventricular drain to relieve hydrocephalus. Patient 8 presented with a CN III palsy and contralateral motor weakness from significant mass effect after undergoing 2 previous endovascular coiling procedures of a giant recanalized right PCoA aneurysm. New-onset seizures occurred in patient 5, and patient 6 presented with transient ipsilateral monocular blindness. Mean age at the time of treatment was 62.8 ± 10.1 years. Mean aneurysm size was 30.9 ± 7.8 mm.

Five patients (45%) presented with ruptured aneurysms. Mean Hunt-Hess scores and Fisher grades were 2.8 ± 0.8 and 3.2 ± 0.5 for patients presenting with subarachnoid hemorrhage. Four of these patients (80%) underwent placement of an external ventricular drain to treat hydrocephalus at the time of admission. One patient (case 2) required placement of a ventriculoperitoneal shunt for permanent diversion of cerebrospinal fluid. Most aneurysms were located on the left side (7 of 11, 64%).

All patients underwent primary clipping. Aneurysmorrhaphy with ultrasonic aspiration of thrombus was performed in 2 patients (patients 1 and 10) before primary clip reconstruction of the parent artery owing to significant thrombus and atherosclerotic debris along the aneurysm neck. Anterior clinoidectomies were performed in 3 patients (patients 5, 7, and 8) to improve visualization of the aneurysm neck and to augment the course of the supraclinoidal ICA to facilitate temporary aneurysm clip placement. One intraoperative rupture occurred at the time of clipping (patient 9) that necessitated sacrifice of the ICA after a radial artery bypass graft was placed. This case is illustrated below. Two patients with ruptured aneurysms (patients 4 and 8) developed symptomatic vasospasm. Both patients showed clinical improvement with hypervolemia-hypertension-hemodilution therapy.

The perioperative mortality rate was 18.2% (2 of 11 patients). Both patients who died presented with ruptured giant PCoA aneurysms. On postoperative day 1, patient 4 developed significant thrombus in the ipsilateral ICA refractory to intraarterial recombinant tissue plasminogen activator and sustained a hemispheric infarction. The patient's family elected to withdraw care 2 days after surgery. Patient 8 developed multisystem organ failure from septic shock. Care was withdrawn on postoperative day 7. Four patients experienced perioperative complications that prolonged their hospitalization, yielding a morbidity rate of 36% (4 of 11). Patient 3 suffered pneumonia and an ipsilateral basal ganglia infarction after a near-drowning episode at the time of presentation. Because we could not definitively exclude surgery as a cause of the infarction, it was included as a perioperative complication. Three additional patients suffered medical complications, which included myocardial infarction (patient 2), gastrointestinal bleeding (patient 9), and pneumonia (patient 11).

Of the remaining 9 patients, 4 were discharged to a neurorehabilitation facility (3 ruptured aneurysms), and 5 were discharged home from the hospital. Long-term follow-up was available for 6 of the 9 surviving patients (67%; Table 2). The mean follow-up period for surviving patients was 12.5 ± 13.6 months. At long-term follow-up, 5 patients (83%) had modified Rankin Scale scores ≤ 2. Patient 10 had improved left-sided weakness but still required some assistance in performing activities of daily living (modified Rankin Scale score 3).

Surgical Nuances

All aneurysms were approached through a pterional craniotomy with significant drilling of the sphenoid ridge or through a modified orbitozygomatic craniotomy. The senior author has adopted the modified orbitozygomatic craniotomy almost exclusively for aneurysms of the anterior circulation because this approach improves visualization of the circle of Willis without the need for significant brain retraction. Despite the large size of the aneurysms in this series, retractors were used sparingly, as illustrated in Videos 1 and 2 (Supplemental Digital Content 1 and 2, http://links.lww.com/NEU/A469 and http://links.lww.com/NEU/A470). Similar to the surgical treatment of nongiant aneurysms, the basic tenets of aneurysm surgery should be followed during the treatment of giant aneurysms. Proximal and distal control of the parent artery is crucial when such daunting lesions are tackled. Despite the large size of the aneurysms in this series, anterior clinoidectomies were used in only 3 of the 11 cases (27.3%) because proximal control was readily achieved in most patients. Careful review of preoperative imaging studies is helpful in determining which patients may require removal of the clinoid process.

Identification of major arteries distal to the aneurysm origin, especially the anterior choroidal artery, is important before distal temporary aneurysm clips are applied. Ideal placement of a distal

Copyright © Congress of Neurological Surgeons. Unauthorized reproduction of this article is prohibited.

TABLE 1. Clinical Summary of 11 Patients With Posterior Communicating Artery Aneurysms[a]

Patient	Age, y/ Sex	Aneurysm Size, mm, Laterality	Rupture Status	Hunt-Hess, Fisher Grades	Presentation	Medical Comorbidities	Surgery	Hospital Course	Discharge Neurological Status
1	60/F	50, R	N	. . .	R CN III palsy	HTN	Aneurysmorrhaphy, clipping, and cotton reinforcement	Uncomplicated	Home on POD 7 with stable R CN III palsy
2	68/F	40, R	Y	3, 3	GCS 14 (E3, M6, V5) with bilateral CN VI palsies	HTN, COPD	Clip	EVD; postoperative myocardial infarction requiring IABP; VPS for hydrocephalus	Neurorehabilitation on POD 37; GCS score of 14 with impaired cognitive function; resolved CN VI palsies
3	59/F	26, L	Y	4, 3	GCS 9T (E4, M4, VT) with R-sided hemiplegia after nearly drowning	Depression, remote smoking history	Clip	EVD; pneumonia, prolonged mechanical ventilation; L basal ganglia infarction	Neurorehabilitation on POD 20 with stable R HP (2/5) and expressive aphasia
4	74/F	27, L	Y	2, 3	Intact with complaints of headache	HTN	Clip	EVD; vasospasm treated with triple-H therapy	Neurorehabilitation on POD 22 with 4/5 strength bilaterally
5	59/F	26, L	Y	2, 4	GCS 14 (E4, M6, V4) with slight confusion	HTN, glaucoma	Anterior clinoidectomy and clipping	L ICA thrombosis with complete L ICA territory infarction on POD 2	WDC on POD 2 after L hemispheric stroke
6	59/F	26, L	N	. . .	New-onset simple partial seizures	HTN, COPD, PVD	Clip	Uncomplicated	Home on POD 4
7	44/F	30, L	N	. . .	Transient monocular blindness, speech difficulty, and R-sided weakness	current smoker	Anterior clinoidectomy, clipping, and cotton reinforcement of small neck remnant	Uncomplicated	Home on POD 6 neurologically intact with no additional TIAs
8	75/F	27, R	Y	3, 3	Intact	HTN, hypothyroidism, COPD, atrial fibrillation	Anterior clinoidectomy and clipping	EVD; aspiration pneumonia, septic shock, mild R MCA distribution vasospasm treated with triple-H therapy, hyponatremia	WDC on POD 7 secondary to multiorgan failure

(Continues)

Copyright © Congress of Neurological Surgeons. Unauthorized reproduction of this article is prohibited.

TABLE 1. *Continued*

Patient	Age, y/ Sex	Aneurysm Size, mm, Laterality	Rupture Status	Hunt-Hess, Fisher Grades	Presentation	Medical Comorbidities	Surgery	Hospital Course	Discharge Neurological Status
9	71/F	26, R	N	. . .	R CN III palsy with L-sided weakness (3/5 throughout)	Anemia	ICA rupture on initial clipping; radial artery bypass from cervical ICA to M2 branch with segmental ICA sacrifice	GI bleed	Neurorehabilitation on POD 11 with stable R CN III palsy and L-sided weakness
10	50/M	35, L	N	. . .	Intact	HTN, DM type II, hypercholesterolemia morbid obesity	Aneurysmorrhaphy and clipping	Uncomplicated	Home on POD 5 neurologically intact
11	72/F	27, L	N	. . .	Intact with R-sided headaches	Hypothyroidism remote smoking	Clip	Pneumonia	Home on POD 7 neurologically intact with IV antibiotics

[a]COPD, chronic obstructive pulmonary disease; DM, diabetes mellitus; EVD, external ventricular drain; GCS, Glasgow Coma Scale; GI, gastrointestinal; HP, hemiparesis; HTN, hypertension; IABP, intra-aortic balloon pump; ICA, internal carotid artery; M2, second segment of middle cerebral artery; MCA, middle cerebral artery; POD, postoperative day PVD, peripheral vascular disease; TIA, transient ischemic attack; Triple-H, hypervolemia, hemodilution, and hypertension; VPS, ventriculoperitoneal shunt; WDC, withdrawal of care.

temporary aneurysm clip should preserve blood flow through the anterior choroidal artery to minimize the risk of ischemic complications to the basal ganglia and internal capsule. Temporary aneurysm clips were used in all 11 cases. Temporary clipping allows the aneurysm sac to deflate while the permanent aneurysm clips are placed. Before temporary aneurysm clips are applied, the patient should be under adequate burst suppression. Permissive hypertension typically is allowed during temporary clipping. If temporary clips cannot be applied, intravenous adenosine may be administered to achieve transient asystole and hypotension. Adenosine was not used in our series, although it has proved helpful during clipping of other complex intracranial aneurysms.

Aneurysmorrhaphy was performed in 2 cases because of significant calcification of the aneurysm neck in combination with atherosclerotic disease. The senior author has had good success performing aneurysmorrhaphy with an ultrasonic aspirator. Thrombus and debris may be efficiently removed with ultrasonic aspiration until fresh blood is encountered near the neck of the aneurysm. In both cases in this series, permanent clips effectively occluded the aneurysm neck after ultrasonic aspiration. Intraoperatively, aneurysm occlusion and preservation of parent arteries can be confirmed with either indocyanine green (ICG) fluoroscopy or conventional digital subtraction angiogram. Given the rapidity of ICG, the senior author prefers ICG fluoroscopy over cerebral angiography. The major limitation of ICG fluoroscopy is the inability to see flow through vessels outside the microscope field.

Case Illustration 1

Patient 9 was a 71-year-old woman with a giant (26 mm) residual right-sided PCoA aneurysm. In 2008, she had undergone coiling of the aneurysm at an outside institution. Follow-up 1-year angiography revealed significant residual aneurysm filling. The patient then underwent stent coiling of the aneurysm at the outside institution in 2009 with suboptimal results. Several months after the stent coiling procedure, the patient was referred to our institution for surgical evaluation.

She had developed a right-sided CN III palsy and left-sided weakness (3/5 strength) related to coil mass effect on the ipsilateral cerebral peduncle (Figure 1A). Preoperative cerebral angiography showed significant residual filling of the aneurysm (Figure 1B) with thrombosis of the aneurysm dome caused by coil compaction. The origin of the anterior choroidal artery was obscured by the coil mass.

The patient underwent a right-sided modified orbitozygomatic craniotomy for clipping of the residual aneurysm (Video 1, Supplemental Digital Content 1, http://links.lww.com/NEU/A469). Proximal and distal control of the parent ICA was obtained. The endoluminal stent with associated atherosclerotic disease within the ICA was visible (Figure 1D). On placement of a 5-mm permanent clip across the neck, a tear occurred on the ventral surface of the ICA. Temporary proximal and distal ICA clips were applied to stop the bleeding. Cotton was used to reinforce the parent artery tear. Despite repositioning of the

Copyright © Congress of Neurological Surgeons. Unauthorized reproduction of this article is prohibited.

TABLE 2. Long-term Modified Rankin Scale Scores After Surgical Treatment of Giant Intracranial Posterior Communicating Artery Aneurysms[a]

Patient	Follow-up, mo	Neurological Examination	Modified Rankin Scale Score
2	35	Mild cognitive impairment	1
6	2	Intact	0
7	22	Intact	0
9	12	Stable right CN III palsy, improved 4/5 left-sided strength	3
10	2	Intact	0
11	2	Intact	0

[a]CN, cranial nerve.

permanent clip, the tear could not be sufficiently occluded without compromising flow through the parent artery. Intraoperative ICG fluoroscopy during temporary clip occlusion of the distal right ICA demonstrated sufficient cross-filling from the left-sided anterior circulation into the right anterior cerebral artery territory. No significant filling of the right middle cerebral artery (MCA) territory was observed. Subsequently, the decision was made to proceed with a high-flow bypass to revascularize the right MCA territory.

The left radial artery was harvested and used to perform an intracranial bypass between the cervical ICA and an M2 branch.

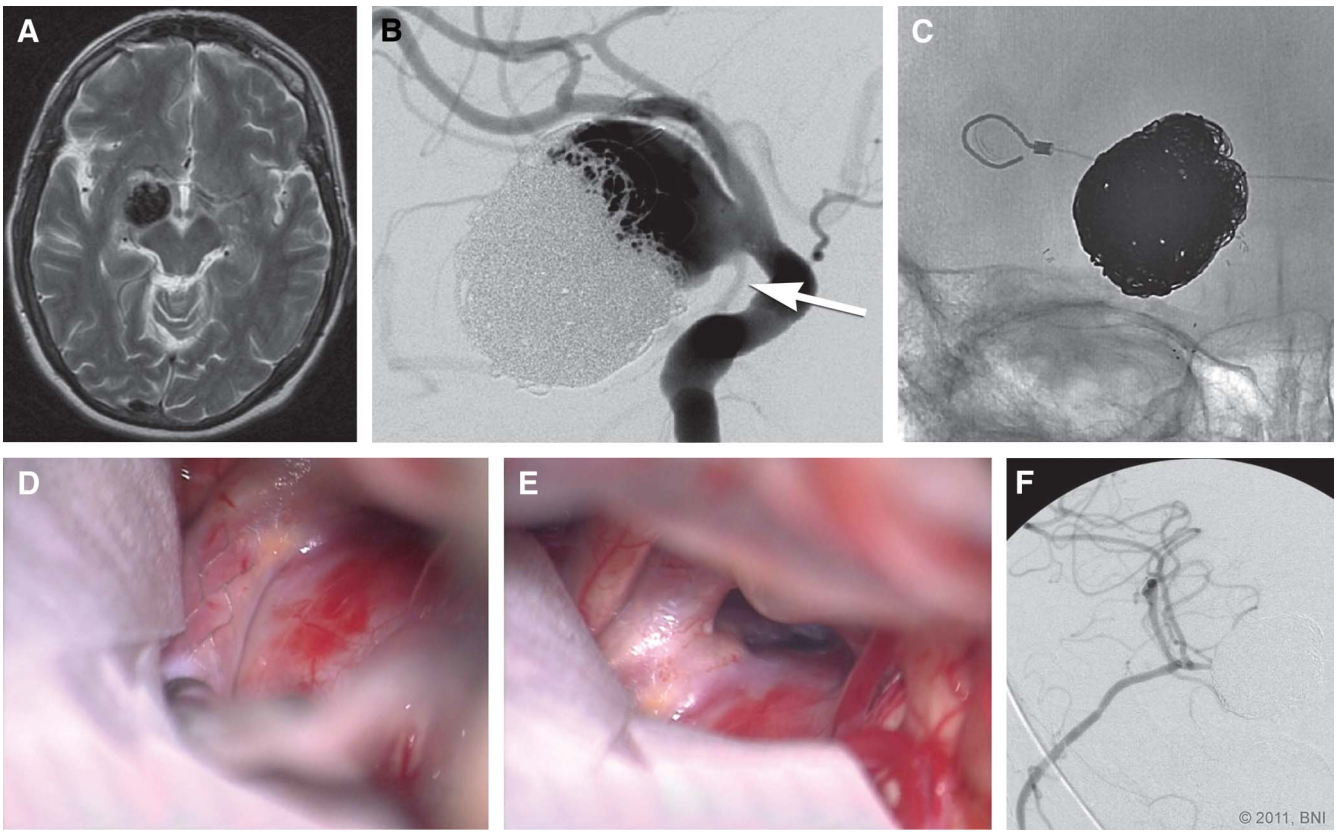

FIGURE 1. **A**, *T2-weighted axial magnetic resonance image showing residual aneurysm and coil mass compressing the right cerebral peduncle.* **B**, *preoperative digital subtraction angiogram showing significant residual filling of the aneurysm neck. The posterior communicating artery (PCoA) artery (arrow) is visualized at the proximal portion of the aneurysm neck.* **C**, *unsubtracted anterior-posterior x-ray showing the proximal and distal stent markers within the right internal carotid artery (ICA).* **D**, *intraoperative photograph shows the aneurysm–parent artery interface. The right ICA stent with associated atherosclerotic disease is visualized.* **E**, *intraoperative photograph showing the origin of the right PCoA along the proximal aneurysm neck.* **F**, *anterior-posterior common carotid artery digital subtraction angiogram shows filling of the right middle cerebral artery territory through the radial artery graft. Flow into the aneurysm was obliterated. Used with permission from Barrow Neurological Institute.*

Copyright © Congress of Neurological Surgeons. Unauthorized reproduction of this article is prohibited.

The sylvian fissure was widely split to expose a robust M2 recipient branch for the bypass. Permanent aneurysm clips were applied along the proximal and distal portions of the ICA to occlude blood flow into the aneurysm. Fluoroscopy with ICG confirmed the patency of the radial artery bypass with filling of the right MCA territory that was further validated by intraoperative cerebral angiography (Figure 1F).

The patient's postoperative course was uneventful except for a gastrointestinal bleed that required blood-product transfusion. She was discharged to a neurorehabilitation unit on postoperative day 11. At 1-year follow-up, the patient had improved neurologically with 4/5 strength in her left arm and leg. Cerebral angiography at that time confirmed patency of the radial artery graft with no residual aneurysm filling.

Case Illustration 2

Patient 10, a 50-year-old man with multiple medical comorbidities, including hypertension, hypercholesterolemia, type II diabetes mellitus, and morbid obesity, was found to have a giant (35 mm) left-sided PCoA aneurysm during an evaluation for headaches. The patient remained neurologically intact. A preoperative noncontrasted head CT confirmed significant calcification of the aneurysm neck (Figure 2A). Cerebral angiography failed to demonstrate filling of the ipsilateral PCoA, which likely thrombosed secondary to altered hemodynamics and atherosclerotic debris (Figure 2B).

The patient underwent a left-sided modified orbitozygomatic craniotomy for clipping of the giant aneurysm (Video 2, Supplemental Digital Content 2, http://links.lww.com/NEU/A470). Proximal and distal control of the parent ICA was obtained. Aneurysmorrhaphy was performed with an ultrasonic aspirator after temporary clip ligation of the proximal and distal ICA just proximal to the origin of the anterior choroidal artery. Ultrasonic aspiration was performed until significant bleeding was encountered, indicating that the bulk of the atherosclerotic debris had been removed. A permanent clip was placed across the aneurysm neck without difficulty. Fluoroscopy with ICG confirmed occlusion of the aneurysm with preserved blood flow through the ICA and anterior choroidal artery. A postclipping CT angiogram of the head confirmed obliteration of the aneurysm and preservation of the ICA and its tributaries (Figure 2C). On postoperative day 5, the patient was discharged home neurologically intact. At the 2-month follow-up examination, the patient remained clinically stable with resolution of his headaches.

DISCUSSION

Giant aneurysms constitute a relatively small percentage of all intracranial aneurysms. They may occur anywhere along the intracranial circulation and more commonly affect the supraclinoidal ICA, MCA, and vertebrobasilar arteries. Giant PCoA aneurysms are rare because aneurysms in this location typically rupture or present with clinical symptoms before attaining giant status. Patients may present with a variety of signs and symptoms related to mass effect on critical neurological structures. "True" PCoA aneurysms, those that arise from the PCoA itself without direct origin from the ICA, are estimated to constitute $< 4\%$ of all intracranial aneurysm.[8] We believe that the actual incidence of these lesions is probably much lower than 4% given the senior author's vast cerebrovascular experience. Several groups have described surgical treatment of true PCoA aneurysms.[9-12]

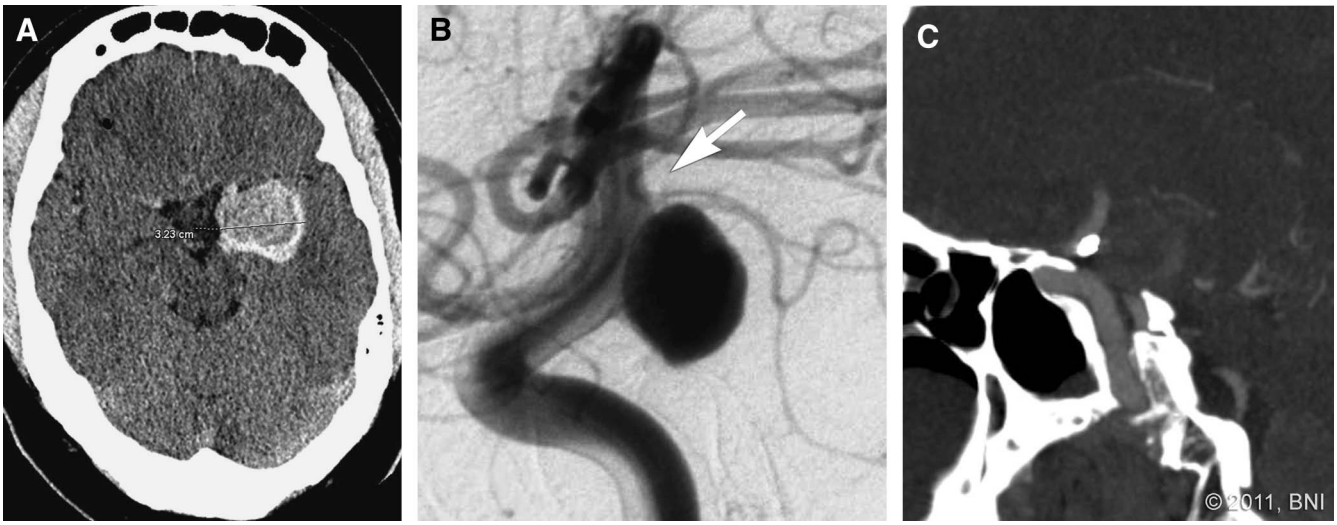

FIGURE 2. **A**, *noncontrasted head computed tomography (CT) shows diffuse calcification of the left posterior communicating artery (PCoA) aneurysm with associated mass effect on the medial left temporal lobe.* **B**, *lateral digital subtraction angiogram showing the left PCoA aneurysm. The PCoA is not visualized. Note the anterior choroidal artery arising distal to the aneurysm origin (arrow).* **C**, *postoperative sagittal CT angiogram showing aneurysm clip placement with no residual aneurysm filling. Used with permission from Barrow Neurological Institute.*

Copyright © Congress of Neurological Surgeons. Unauthorized reproduction of this article is prohibited.

To date, few case reports of giant PCoA aneurysms arising directly from the PCoA itself have been published.[8,13] No true giant PCoA aneurysms were observed in our series. These aneurysms, which are typically fusiform in morphology, are exceedingly rare because they likely form after dissection of the PCoA.

Direct surgical clipping of the aneurysm neck with preservation of the parent artery is an accepted treatment method for giant intracranial aneurysms. After clipping, the aneurysm may be debulked to reduce symptomatic mass effect. Giant PCoA aneurysms are amenable to surgical intervention given their origin off the communicating ICA segment, which typically allows the surgeon to obtain adequate proximal and distal control of the parent artery. Careful preoperative planning is necessary to ensure operative success. A modified orbitozygomatic craniotomy improves visualization of the supraclinoidal ICA and can be further augmented by performing an anterior clinoidectomy. The exact origins of the PCoA and anterior choroidal arteries should be delineated preoperatively with either conventional cerebral angiography or CT/magnetic resonance angiography. Aneurysms associated with significant atherosclerotic disease may have to be opened and debulked before final clip placement. Emergent bypass may be required when the ICA has to be sacrificed, as occurred in one of our patients (case 9) after intraoperative aneurysm rupture. Temporary cardiac arrest with hypothermic cardiac standstill or adenosine may be considered to aid in clip placement, although these measures were not required in this series, largely because temporary clips could be placed both proximally and distally to the aneurysm. After clip placement, perforating vessels should be inspected carefully as with all aneurysms.

Contemporary surgical series have demonstrated acceptable outcomes compared with the natural history of these lesions. Excellent or good clinical function has been observed in 61% to 87% of patients undergoing surgical treatment of giant intracranial aneurysms with perioperative mortality rates ranging from 5% to 22%.[3,14-20] Similar clinical results were achieved in our series. Both perioperative deaths occurred in patients with ruptured giant PCoA aneurysms.

Direct parent artery occlusion through surgical ligation or endovascular coiling may be considered for the treatment of giant intracranial aneurysms affecting the anterior cerebral circulation. Surgical ligation of the common or internal carotid arteries has been proven safe and effective for intracranial aneurysms in numerous studies, many of which were published before modern refinements in microsurgical technique and clip technology.[21-24] This treatment modality relies on thrombosis of the aneurysm through altered intracranial hemodynamics. Before carotid artery ligation, the patient's tolerance of occlusion should be tested to reduce the likelihood of ischemic sequelae. Balloon test occlusion with provocative hypotensive challenge and single-photon emission CT is commonly used to evaluate patient tolerance of carotid artery sacrifice. Supplemental extracranial-to-intracranial bypass may be required for patients who fail physiological occlusion of the carotid artery. It is our institutional policy to attempt salvage of parent arteries supplying intracranial aneurysms whenever possible. Salvage is particularly important for aneurysms along the distal intracranial internal carotid artery where the efficacy of carotid ligation decreases relative to aneurysms along the petrous, cavernous, and ophthalmic segments owing to potential collateralized blood flow. De novo aneurysm formation, estimated to occur in as many as 10% of patients, may also develop after carotid artery sacrifice as a result of altered hemodynamics.[25,26] Parent artery ligation with supplemental extracranial-to-intracranial bypass was performed on patient 9 when a tear developed along the ventral surface of the carotid artery after initial clipping.

Endovascular therapy may be considered for giant intracranial aneurysms, although complication rates and the need for supplemental treatment are high. Early endovascular series reported morbidity and mortality rates up to 42% and 27%, respectively.[27-31] Despite innovations in endovascular devices and techniques, coil obliteration of giant aneurysms is fraught with high complication rates. In a series of 12 patients with giant intracranial aneurysms, Gruber et al[28] treated 3 giant PCoA aneurysms using endovascular techniques. Two aneurysms were coiled and 1 aneurysm was treated through ICA occlusion. The periprocedural mortality rate for these patients was 67%. The sole surviving patient experienced resolution of an oculomotor palsy at the 65-month clinical follow-up with angiographic recurrence of the aneurysm. In a recent series of 39 consecutive patients with giant intracranial aneurysms (10 ruptured) who were treated with endovascular techniques, the periprocedural morbidity and mortality rates were 32% and 16%, respectively.[32] Stent-assisted coiling was necessary to treat 25 aneurysms in this series. Cumulative morbidity and mortality rates were 26% and 29%, respectively, at a mean follow-up of about 25 months. No giant PCoA aneurysms were treated, although the study included 8 paraclinoidal aneurysms. On average, 1.9 treatment sessions were required to treat each aneurysm. Eight patients who tolerated balloon test occlusion underwent endovascular sacrifice of the proximal parent artery supplying the aneurysm. In our series, patient 9 underwent several unsuccessful endovascular procedures to obliterate her giant PCoA aneurysm. Despite stent-assisted coiling, the aneurysm continued to grow and eventually compressed her mesencephalon, resulting in contralateral weakness and an ipsilateral oculomotor palsy.

Recent innovations in endovascular devices have yielded flow-diverting stents such as the Pipeline Embolization Device (ev3, Plymouth, Minnesota) and Silk stent (Balt, Montmorency, France), which may be considered for the treatment of giant intracranial aneurysms. These devices promote stagnation, thrombosis, and eventual neointimal proliferation to occlude intracranial aneurysms. Combined data from recent published series detail the successful treatment of 40 giant aneurysms with flow-diverting stents (14 Pipeline and 26 Silk stents) with relatively low complication profiles.[33-38] Most of the aneurysms in our series were treated before flow diverters became commercially available.

Flow-diverting stents have several limitations. Because prolonged antiplatelet therapy is required to prevent in-stent thrombosis, patients with subarachnoid hemorrhage may face increased risks of hemorrhagic complications after flow diversion. Second, the Pipeline device is approved in the United States only

Copyright © Congress of Neurological Surgeons. Unauthorized reproduction of this article is prohibited.

for large or giant wide-necked intracranial aneurysms arising from the petrous to superior hypophyseal segments of the internal carotid artery. Such restrictions do not apply to the Silk stent, which currently is not available in the United States.

CONCLUSION

This is the largest surgical series of giant PCoA aneurysms reported to date. Nonetheless, it is difficult to draw definitive conclusions from the relatively small sample size. The predominance of female patients in the series introduces the possibility that genetic or hormonal influences may allow these lesions to reach giant status, although it is widely known that PCoA aneurysms are more predominant in female patients. Limitations of this study include its retrospective nature and limited clinical follow-up. Considering the poor natural history of giant intracranial aneurysms, our experience suggests that PCoA aneurysms may be treated surgically with comparatively favorable morbidity and mortality rates.

Disclosure

The authors have no personal financial or institutional interest in any of the drugs, materials, or devices described in this article.

REFERENCES

1. Barrow DL, Alleyne C. Natural history of giant intracranial aneurysms and indications for intervention. *Clin Neurosurg*. 1995;42:214-244.
2. Ljunggren B, Brandt L, Sundbarg G, Saveland H, Cronqvist S, Stridbeck H. Early management of aneurysmal subarachnoid hemorrhage. *Neurosurgery*. 1982;11(3):412-418.
3. Peerless S, Wallace M, Drake C. Giant intracranial aneurysms. In: Youmans JR, ed. *Neurological Surgery: A Comprehensive Reference Guide to the Diagnosis and Management of Neurological Problems*. 3 ed. Philadelphia, PA: WB Saunders; 1990:1764-1806.
4. Drake CG. Giant intracranial aneurysms: experience with surgical treatment in 174 patients. *Clin Neurosurg*. 1979;26:12-95.
5. Gnanalingham KK, Colquhoun I, van Dellen J. Temporal lobe seizures: unusual presentation of a giant unruptured posterior communicating artery aneurysm. *Br J Neurosurg*. 2003;17(4):370-371.
6. Merva W, Jamshidi S, Kurtzke JF. Posterior communicating artery giant aneurysm as a cause of seizures. *Neurology*. 1985;35(4):620-622.
7. Smith KA, Kraus GE, Johnson BA, Spetzler RF. Giant posterior communicating artery aneurysm presenting as third ventricle mass with obstructive hydrocephalus. Case report. *J Neurosurg*. 1994;81(2):299-303.
8. Matsumoto K, Kuriyama M, Tamiya T, Ohmoto T. Direct clip obliteration of a ruptured giant aneurysm of the posterior communicating artery: case report. *Neurosurgery*. 1997;41(4):939-942.
9. Akimura T, Abiko S, Ito H. True posterior communicating artery aneurysm. *Acta Neurol Scand*. 1991;84(3):207-209.
10. Kudo T. An operative complication in a patient with a true posterior communicating artery aneurysm: case report and review of the literature. *Neurosurgery*. 1990;27(4):650-653.
11. Takahashi A, Kamiyama H, Imamura H, Kitagawa M, Abe H. "True" posterior communicating artery aneurysm: report of two cases. *Neurol Med Chir (Tokyo)*. 1992;32(6):338-341.
12. Yoshida M, Watanabe M, Kuramoto S. "True" posterior communicating artery aneurysm. *Surg Neurol*. 1979;11(5):379-381.
13. Kawaguchi S, Noguchi H, Yonezawa T, Hoshida T, Morimoto T, Sakaki T. Giant true posterior communicating artery aneurysm. *J Stroke Cerebrovasc Dis*. 1998;7(4):259-262.
14. Ausman JI, Diaz FG, Sadasivan B, Gonzeles-Portillo M Jr, Malik GM, Deopujari CE. Giant intracranial aneurysm surgery: the role of microvascular reconstruction. *Surg Neurol*. 1990;34(1):8-15.
15. Hosobuchi Y. Giant intracranial aneurysms. In: Wilkins RH, Rengachary SS, eds. *Neurosurgery*. New York, NY: McGraw-Hill; 1985:1404-1414.
16. Kodama N, Suzuki J. Surgical treatment of giant aneurysms. *Neurosurg Rev*. 1982;5(4):155-160.
17. Lawton MT, Spetzler RF. Surgical management of giant intracranial aneurysms: experience with 171 patients. *Clin Neurosurg*. 1995;42:245-266.
18. Sundt TM. Results of surgical management. In: Sundt TM Jr, ed. *Surgical Techniques for Saccular and Giant Intracranial Aneurysms*. Baltimore, MD: Williams and Wilkins; 1990:19-23.
19. Symon L, Vajda J. Surgical experiences with giant intracranial aneurysms. *J Neurosurg*. 1984;61(6):1009-1028.
20. Yasargil M. Giant intracranial aneurysms. In: Yasargil MG, ed. *Microneurosurgery, Volume 2: Clinical Considerations: Surgery of the Intracranial Aneurysms and Results*. New York, NY: Thieme-Stratton; 1984:296-304.
21. Elhammady MS, Wolfe SQ, Farhat H, Ali Aziz-Sultan M, Heros RC. Carotid artery sacrifice for unclippable and uncoilable aneurysms: endovascular occlusion vs common carotid artery ligation. *Neurosurgery*. 2010;67(5):1431-1436.
22. German WJ, Black SP. Cervical ligation for internal carotid aneurysms: an extended follow-up. *J Neurosurg*. 1965;23(6):572-577.
23. Nishioka H. Results of the treatment of intracranial aneurysms by occlusion of the carotid artery in the neck. *J Neurosurg*. 1966;25(6):660-704.
24. Tytus JS, Ward AA Jr. The effect of cervical carotid ligation on giant intracranial aneurysms. *J Neurosurg*. 1970;33(2):184-190.
25. Briganti F, Cirillo S, Caranci F, Esposito F, Maiuri F. Development of "de novo" aneurysms following endovascular procedures. *Neuroradiology*. 2002;44(7):604-609.
26. Lawton MT, Hamilton MG, Morcos JJ, Spetzler RF. Revascularization and aneurysm surgery: current techniques, indications, and outcome. *Neurosurgery*. 1996;38(1):83-92.
27. Gobin YP, Vinuela F, Gurian JH, et al. Treatment of large and giant fusiform intracranial aneurysms with Guglielmi detachable coils. *J Neurosurg*. 1996;84(1):55-62.
28. Gruber A, Killer M, Bavinzski G, Richling B. Clinical and angiographic results of endosaccular coiling treatment of giant and very large intracranial aneurysms: a 7-year, single-center experience. *Neurosurgery*. 1999;45(4):793-803.
29. Lubicz B, Gauvrit JY, Leclerc X, Lejeune JP, Pruvo JP. Giant aneurysms of the internal carotid artery: endovascular treatment and long-term follow-up. *Neuroradiology*. 2003;45(9):650-655.
30. Lubicz B, Leclerc X, Gauvrit JY, Lejeune JP, Pruvo JP. Giant vertebrobasilar aneurysms: endovascular treatment and long-term follow-up. *Neurosurgery*. 2004;55(2):316-323.
31. Sluzewski M, Menovsky T, van Rooij WJ, Wijnalda D. Coiling of very large or giant cerebral aneurysms: long-term clinical and serial angiographic results. *AJNR Am J Neuroradiol*. 2003;24(2):257-262.
32. Jahromi BS, Mocco J, Bang JA, et al. Clinical and angiographic outcome after endovascular management of giant intracranial aneurysms. *Neurosurgery*. 2008;63(4):662-674.
33. Byrne JV, Beltechi R, Yarnold JA, Birks J, Kamran M. Early experience in the treatment of intra-cranial aneurysms by endovascular flow diversion: a multicentre prospective study. *PLoS One*. 2010;5(9):pii: e12492.
34. Leonardi M, Cirillo L, Toni F, et al. Treatment of intracranial aneurysms using flow-diverting silk stents (BALT): a single centre experience. *Interv Neuroradiol*. 2011;17(3):306-315.
35. Lylyk P, Miranda C, Ceratto R, et al. Curative endovascular reconstruction of cerebral aneurysms with the pipeline embolization device: the Buenos Aires experience. *Neurosurgery*. 2009;64(4):632-642.
36. Nelson PK, Lylyk P, Szikora I, Wetzel SG, Wanke I, Fiorella D. The pipeline embolization device for the intracranial treatment of aneurysms trial. *AJNR Am J Neuroradiol*. 2011;32(1):34-40.
37. Szikora I, Berentei Z, Kulcsar Z, et al. Treatment of intracranial aneurysms by functional reconstruction of the parent artery: the Budapest experience with the pipeline embolization device. *AJNR Am J Neuroradiol*. 2010;31(6):1139-1147.
38. Wagner A, Cortsen M, Hauerberg J, Romner B, Wagner MP. Treatment of intracranial aneurysms: reconstruction of the parent artery with flow-diverting (Silk) stent [published online ahead of print September 6, 2011]. *Neuroradiology*. doi:10.1007/s00234-011-0949-9.

Supplemental digital content *is available for this article. Direct URL citations appear in the printed text and are provided in the HTML and PDF versions of this article on the journal's Web site (www.neurosurgery-online.com).*

Copyright © Congress of Neurological Surgeons. Unauthorized reproduction of this article is prohibited.

COMMENTS

The authors report a series of 11 patients treated between 1989 and 2010 by surgical approach for giant posterior communicating aneurysms. This is the largest series to date within the literature.

They have shown that surgery may be performed with acceptable morbidity and mortality in these challenging cases. These surgical techniques require a great amount of experience within the field of vascular neurosurgery, including the ability to perform extracranial-intracranial bypasses in an emergency.

Nowadays, thanks to the development of flow-diverter stents, there is a new and effective therapeutic option for giant aneurysms. Indeed, these aneurysms are very good candidates for flow diversion with or without partial coiling to avoid any delayed complication. More and more authors are reporting very good clinical and anatomic results with the use of this endovascular technique. Long-term follow-up is still needed to precisely define the place of this new option within the therapeutic armamentarium of intracranial aneurysms.

Last but not least, and despite major advances in microneurosurgical techniques and endovascular options for managing patients with giant aneurysms, one must remember that parent artery occlusion can also be performed after a test occlusion. This "simple" treatment has proved, over several decades, that it was safe, effective, and very stable over time.

Boris Lubicz
Brussels, Belgium

Giant aneurysms continue to pose significant challenges for the neurosurgery community. Endovascular approaches have not provided any reasonable alternatives for dangerous microsurgical procedures. The advent of flow diverters may offer an acceptable endovascular approach for giant carotid aneurysms, but definitive confirmation of efficacy and risk reduction is a work in progress. In the experience reported in this review, giant posterior communicating artery aneurysms were treated surgically with relatively high surgical morbidity of $> 50\%$. The added risks of treating these aneurysms after failed endovascular treatment are highlighted in this experience. These 11 patients represent the authors' experience over the last 21 years. Much has changed over that time, and it is possible that present-day results might be better. In my experience, although surgical techniques have not changed dramatically, our results are better because of more careful patient selection. Direct clipping of giant aneurysms is generally pursued only in younger patients with favorable anatomy. With unfavorable anatomy and especially in older patients, proximal occlusion after trial balloon occlusion and extracranial-intracranial bypass may significantly reduce treatment risks.

Robert A. Solomon
New York, New York

The pendulum has shifted significantly in the last decade to treat the aneurysms of all varieties with endovascular techniques. More recent introduction of flow-diverting stents in the treatment of giant aneurysms will definitely aid in their management. Despite these advances, we are not infrequently faced with the challenge of treating these giant and complex aneurysms surgically. Giant aneurysms of the posterior communicating artery are indeed uncommon, as demonstrated by the fact that these authors collected only 11 cases in 21 years. They have added to our understanding of surgical techniques in dealing with these rare but critical aneurysms. It is obvious that cerebrovascular surgeons need to maintain microsurgical skills and pass them along to the next generation to deal with such lesions. However, we need to keep in mind that the aneurysms with highly calcified wall pose significant difficulty in direct clipping. If there has been no hemorrhage or significant deficit, they could be left alone, as we have done in 2 cases with no changes on follow-up studies over quite a few years. Similarly, carotid occlusion also remains a viable option in patients who can tolerate a carotid occlusion test.

Ghaus M. Malik
Detroit Michigan

Copyright © Congress of Neurological Surgeons. Unauthorized reproduction of this article is prohibited.