See the corresponding editorial in this issue, pp 676–678.

J Neurosurg 117:679–686, 2012

The role of radiotherapy following gross-total resection of atypical meningiomas

Clinical article

Ricardo J. Komotar, M.D.,[1] J. Bryan Iorgulescu, B.S.,[2,3] Daniel M. S. Raper, M.B.B.S.,[4] Eric C. Holland, M.D., Ph.D.,[2,3,5,6] Kathryn Beal, M.D.,[7] Mark H. Bilsky, M.D.,[2,3,5] Cameron W. Brennan, M.D.,[2,3,5] Viviane Tabar, M.D.,[2,3,5] Jonathan H. Sherman, M.D.,[8] Yoshiya Yamada, M.D.,[5,7] and Philip H. Gutin, M.D.[2,3,5]

[1]Department of Neurological Surgery, The University of Miami Miller School of Medicine, Miami, Florida; Departments of [2]Neurosurgery, [6]Cell Biology and Genetics, and [7]Radiation Oncology, and [5]Brain Tumor Center, Memorial Sloan–Kettering Cancer Center; [3]Department of Neurological Surgery, Weill Cornell Medical College, New York, New York; [8]Department of Neurosurgery, The George Washington University Medical Center, Washington, DC; and [4]Royal North Shore Hospital, Sydney, Australia

Object. Atypical (WHO Grade II) meningiomas comprise a heterogeneous group of tumors, with histopathology delineated under the guidance of the WHO and a spectrum of clinical outcomes. The role of postoperative radiotherapy for patients with atypical meningiomas who have undergone gross-total resection (GTR) remains unclear. In this paper, the authors sought to clarify this role by reviewing their experience over the past 2 decades.

Methods. The authors retrospectively analyzed all patients at their institution who underwent GTR between 1992 and 2011 with a final histology demonstrating atypical meningioma. Information regarding patients, tumor characteristics, and postoperative adjuvant therapy was gleaned from medical records. Time to recurrence and overall survival were analyzed using univariate, multivariate, and Kaplan-Meier survival analyses.

Results. Forty-five patients who met the inclusion criteria underwent GTR for atypical meningiomas. By a median follow-up of 44.1 months, 22% of atypical meningiomas had recurred. There was no recurrence in 12 (92%) of 13 patients who received postoperative radiotherapy or in 19 (59%) of 32 patients who did not undergo postoperative radiotherapy ($p = 0.085$), demonstrating a strong trend toward improved local control with postoperative radiotherapy. No other factors were significantly associated with recurrence in univariate or multivariate analyses.

Conclusions. This retrospective series supports the observation that postoperative radiotherapy likely results in lower recurrence rates of gross totally resected atypical meningiomas. Although a multicenter prospective trial will ultimately be needed to fully define the role of radiotherapy in managing gross totally resected atypical meningiomas, the authors' results contribute to a growing number of series that support routine postoperative radiotherapy as an adjuvant treatment for these lesions.

(http://thejns.org/doi/abs/10.3171/2012.7.JNS112113)

Key Words • **atypical meningioma** • **outcome** • **radiotherapy** • **surgery** • **oncology**

Atypical meningiomas are reported to account for 20%–35% of all meningiomas and represent an intermediate subtype between benign and anaplastic meningiomas in the WHO classification.[5,39,40,47] Although benign meningiomas (WHO Grade I) are generally slow growing and have a low recurrence rate after GTR,[28,44] atypical meningiomas are more locally aggressive and demonstrate more rapid tumor progression, with 5-year recurrence rates of approximately 40% in the literature in the absence of postoperative radiotherapy.[8,20,34,39] Atypical meningiomas are also associated with significantly increased mortality. Although GTR, when possible, is widely accepted to be the standard of care for benign meningiomas, a purely neurosurgical approach may be inadequate for atypical meningiomas.

The role of postoperative radiotherapy as a standard adjuvant treatment after GTR of atypical meningiomas remains controversial.[1,12,28] Some evidence that a majority of atypical meningiomas exhibit an intact p53 system suggests a radiation-sensitive phenotype and, consequently, a role for adjuvant radiotherapy.[3,25,36] There has been support for early postoperative stereotactic radiotherapy in the majority of patients with atypical meningiomas to

Abbreviations used in this paper: GTR = gross-total resection; OS = overall survival; PFS = progression-free survival.

prevent progression and recurrence, although evidence for this position comes mainly from small, retrospective case series.[1,17,18,32,33,38,42] A recent case series suggested that the addition of postoperative radiation therapy may be associated with lower recurrence rates regardless of the extent of initial resection.[1] Our study aimed to further characterize the efficacy of postoperative radiotherapy in the prevention of recurrence and death after GTR of atypical meningiomas.

Methods

A retrospective analysis was undertaken of all patients at Memorial Sloan–Kettering Cancer Center who underwent resection of atypical meningiomas between 1992 and 2011. This study was approved by Memorial Sloan–Kettering Cancer Center's institutional review board. Patient details were recorded, including sex, age at diagnosis, tumor diameter and location, operative characteristics, recurrence details, use of postoperative radiotherapy, and duration of follow-up. The majority of patients were treated with primary resection at our institution, although 5 patients underwent resection of a recurrent tumor, and 1 patient received whole-brain radiotherapy for acute lymphoblastic leukemia 16 years prior to surgery. A diagnosis of atypical meningioma was confirmed by histological examination of operative specimens in conjunction with imaging findings, operative appearance, and medical notes. Outcomes were also noted, including postoperative radiotherapy, recurrence, postrecurrence treatment, and survival. Gross-total resection was determined in all patients by postoperative MRI in conjunction with the surgeon's impression intraoperatively and corresponds to Simpson Grade I and II excisions. In accordance with previous reports,[1] tumors were divided into the following categories: 1) convexity; 2) parasagittal/falcine; 3) sphenoid ridge; 4) posterior fossa; 5) midline anterior fossa (for example, olfactory groove, planum sphenoidale, and tuberculum); or 6) other categories according to their anatomical location, as identified by neuroradiology. Exclusion criteria included postoperative follow-up shorter than 2 months (2 patients) and patient death before postoperative imaging or recurrence (5 patients).

Time to recurrence was measured from the date of GTR to the date of radiological evidence of recurrent disease, which was determined via Gd-enhanced MRI in all cases. The median follow-up was measured from the date of GTR. Patients underwent follow-up until an end point of recurrence for PFS analysis; patients lost to follow-up or death were censored at the date of last imaging or death. An end point of death was used for OS analysis with cases lost to follow-up censored at the date of last review.

Statistical Analysis

Univariate Cox proportional hazards models and multivariate Cox regression analysis were used to identify risk factors for recurrence. Time to recurrence and time to death were estimated using the Kaplan-Meier method and compared among variables using a log-rank test. A p value ≤ 0.05 was considered statistically significant, and SPSS software was used for all statistical analyses (version 18.0, IBM Corp.).

Patients were simulated with a CT simulator from 1996 onward and with CT guidance prior to that. Patients were treated in the supine position, and an Aquaplast face mask (WFR/Aquaplast Co.) was used for immobilization. Radiation fields were designed based on postoperative imaging findings, including MRI and/or CT with contrast. The tumor cavity was defined to be the clinical target volume, and a 0.5- to 1.0-cm expansion was used to determine the planning target volume. The expansion was typically more generous along dural planes and more limited into brain parenchyma. Typical limitations for critical structures were used when designing radiation plans with the aid of medical physics.

Results

A total of 52 patients who underwent GTR of an atypical meningioma between 1992 and 2011 were treated at Memorial Sloan–Kettering Cancer Center. Forty-five patients remained after excluding patients with postoperative follow-up shorter than 2 months (2 patients, neither tumor recurred) and patients who died without postoperative imaging or recurrence (5 patients, 1 of whom received radiotherapy).

Patient and tumor characteristics are summarized in Table 1. The median follow-up was 44.1 months (mean 56.2 months, range 2.7–225.5 months). Thirteen patients

TABLE 1: Patient and tumor characteristics*

Characteristic	Value
no. of pts	45
no. of male pts (%)	20 (44.4)
age at diagnosis in yrs	
mean	56.1
range	23.3–81.3
follow-up in mos	
median	44.1
range	2.7–225.5
no. alive at last follow-up (%)	40 (88.9)
diameter in cm	
median	4.9
range	2.0–8.9
tumor location (%)	
convexity	27 (60.0)
parasagittal/falcine	6 (13.3)
sphenoid	8 (17.8)
posterior fossa	2 (4.4)
midline anterior fossa	2 (4.4)
other	0 (0)
postoperative therapy (%)	
yes	13 (28.9)
no	32 (71.1)

* pts = patients.

(28.9%) received postoperative adjuvant radiotherapy (median follow-up 49.4 months). Recurrence developed in 14 patients (31.1%), of whom 9 (64.3%) were alive at last follow-up (Table 2 and Fig. 1). The actuarial recurrence rates at 1, 5, and 10 years were 7.9% (95% CI 0%–16.5%), 35.5% (95% CI 17.7%–53.3%), and 55.3% (95% CI 26.3%–84.3%), respectively. The median time to recurrence was 24.0 months (mean 38.0 months, range 8–132 months). Tumor recurred in 7 (25.9%) of 27 patients with convexity, 3 (50.0%) of 6 patients with parasagittal, and 4 (50.0%) of 8 patients with sphenoid meningiomas, reflecting the distribution of primary atypical meningiomas (Table 2). Of the patients with recurrence, 13 had not received prior radiotherapy (92.9%) and experienced recurrence at a median latency of 19.0 months (mean 36.9 months, range 8–132 months). Nine (69.2%) of these patients were alive at last follow-up. One patient who underwent radiotherapy experienced a recurrence 52.5 months post-GTR, received no further treatment, and died 48.6 months later (cause unknown). There were no recurrences in 12 (92.3%) of 13 patients who received fractionated radiotherapy after an initial GTR (Fig. 2). The median radiation dose was 59.4 Gy delivered in daily fractions of 180 or 200 cGy. Radiation therapy was initiated a median of 2 months after surgery and was completed over a median of 6 weeks (range 5.6–10.0 weeks). All patients with recurrent meningiomas survived 1 year postrecurrence, except 1 patient who was alive at last follow-up 4 months after recurrence.

Among the patients who had recurrence without radiotherapy, 6 (46.2%) received radiotherapy postrecurrence, 1 (7.7%) had a second resection, 3 (23.1%) underwent both radiotherapy and resection, and 3 (23.1%) received no further treatment. Five (83.3%) of 6 patients who received radiotherapy for recurrence were still alive at last follow-up (median 20.3 months, range 1.4–67.6 months). All 3 patients who received both radiotherapy and resection for recurrence were alive at last follow-up (median 36.3 months, range 14.3–159.5 months). All patients tolerated the treatment well with minimal, short-term complications that included the following: Grade 1 skin toxicity (dermatitis, erythema) and alopecia of the irradiated site, Grade 0 neurological toxicity, Grade 1 fatigue and headaches. One patient experienced persistent left temporal pain that resolved 18 months postradiotherapy.

Univariate and multivariate analyses were conducted

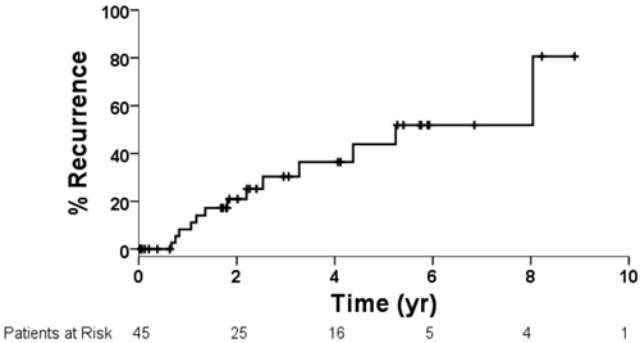

Fig. 1. Kaplan-Meier analysis showing the percentage of patients with atypical meningiomas treated with GTR who experienced recurrence over time (n = 45).

TABLE 2: Outcomes for patients with atypical meningiomas treated with GTR*

Recurrence	Total	Alive (%)	Time to Recurrence (mos)†
no. of pts	14	9/14 (64.3)	24.0
postop RT	1	0 (0)	52.5
no postop RT	13	9/13 (69.2)	19.0
Actuarial Recurrence Rate	%	95% CI	
1-yr	7.9	0–16.5	
5-yr	35.5	17.7–53.3	
10-yr	55.3	26.3–84.3	
Location of Tumor	Total (%)	Recurrence (%)	Recurrence in Location (%)
convexity	27/45 (60.0)	7/14 (50.0)	25.9
parasagittal/falcine	6/45 (13.3)	3/14 (21.4)	50.0
sphenoid	8/45 (17.8)	4/14 (28.6)	50.0
posterior fossa	2/45 (4.4)	0 (0)	0
midline anterior fossa	2/45 (4.4)	0 (0)	0
other	0 (0)	0 (0)	0
Treatment for Recurrence	Total	Alive (%)	Follow-Up (mos)
none	4	1/4 (25.0)	82.5
RT	6	5/6 (83.3)	20.3
resection	1	0 (0)	98.0
RT + resection	3	3/3 (100)	36.3

* RT = radiotherapy.
† Values for the total group and the patients not receiving postoperative RT are medians.

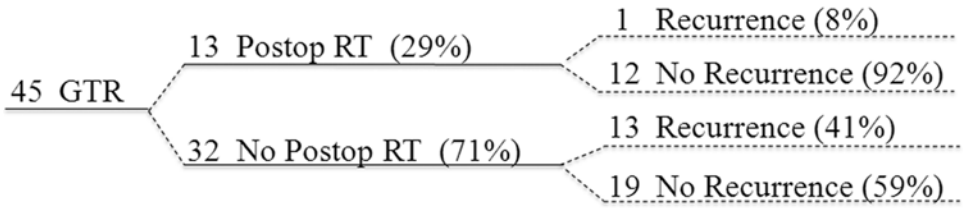

Fig. 2. Depiction of the number of patients with atypical meningiomas treated with GTR who either received postoperative radiotherapy (RT; n = 13) or did not (n = 32), and the subsequent patient group who experienced recurrence.

to assess the following variables for their predictive value for tumor recurrence: use of postoperative radiotherapy, sex, tumor location, tumor diameter, and decade of life. In a univariate analysis, none of these variables was significantly associated with tumor recurrence, although postoperative radiotherapy revealed an association with lower recurrence trending toward significance (HR 5.05 [95% CI 0.65–39.15] for no postoperative radiotherapy, p = 0.12 [Table 3]). This trend was similarly evident in a multivariate analysis (HR 4.97 [95% CI 0.55–44.68] for no postoperative radiotherapy, p = 0.15). Other variables were not associated with recurrence in our multivariate analysis (Table 3).

Discussion

Although most meningiomas are benign, up to 20%–35% of tumors are classified as atypical (Grade II) according to the 2000 WHO classification.[5,39,40,47] This classification is based on a number of histological characteristics, including demonstration of ≥ 4 mitotic figures per 10 hpf or ≤ 3 features associated with higher grade, including architectural sheeting, necrosis, prominent nucleoli, hypercellularity, or high nuclear-to-cytoplasmic ratio.[30,40] Atypical meningiomas may arise spontaneously or transform from benign meningiomas; the latter type is associated with a more precipitous course and shorter OS.[24]

Early reports often classified atypical meningiomas together with malignant or anaplastic meningiomas,[2,26,31] which have been shown to have significantly worse OS and PFS.[17,49] Greater extent of resection was correlated with decreased recurrence rates in these initial series,[15,49] with a 5-year survival of up to 87% in small series.[9,15] Nevertheless, the majority of patients experienced recurrence after either surgery or postoperative radiotherapy,[9,17] with no improvement in PFS postradiotherapy.[26] Modern series that distinguish atypical meningioma from malignant meningioma report longer follow-up with low mortality rates[16] and recurrence-free survival of up to 89% at 5 years in patients treated with postoperative fractionated radiotherapy.[16,32] For patients not receiving routine radiotherapy, 5-year PFS rates of approximately 48% have been reported.[19,34]

The 1993 WHO classification system grouped multiple disparate histological entities into Grade II,[37] contributing to heterogeneous patient outcomes and rendering direct comparison of case series difficult. More recent categorization from 2000 has helped to standardize nomenclature for these lesions,[39,40,48] although some heterogeneity remains.[46] The change of classification has also resulted in a significant increase in tumors classified as Grade II.[42] Analyses of trends in meningioma management from before and after 2000 revealed that meningioma reclassification from "benign" to "atypical" was most commonly due to elevations in estimated mitotic counts.[47]

Prognostic Indicators

A number of prognostic indicators have been proposed from analyses of single-institution case series to help elucidate the remaining heterogeneity in the classification of atypical meningiomas. Histological features indicative of poor outcome include increased cellularity, high mitotic count, poor differentiation, and brain invasion.[2,46,49] Elevated levels of the proliferation marker Ki 67 have been associated with tumor recurrence and lower OS for both atypical meningioma and anaplastic meningiomas.[6,22,46] A variety of genetic abnormalities have been associated with tumor progression and pathogenesis for atypical meningiomas, including loss of chromosome 22; gains and losses of chromosomes 9, 10, 14, and 18; and amplifications on chromosome 17, although specific genes affected by these mutations remain unidentified.[7,8] Other poor prognostic factors of atypical meningioma

TABLE 3: Patient and tumor factors associated with recurrence for atypical meningiomas treated with GTR*

	Univariate		Multivariate	
Factor	HR (95% CI)	p Value	HR (95% CI)	p Value
postop RT	5.05 (0.65–39.15) for no RT	0.12	4.97 (0.55–44.68) for no RT	0.15
age	1.22 (0.81–1.84) per decade	0.34	1.27 (0.71–2.28) per decade	0.42
tumor size	1.08 (0.75–1.55) per cm	0.69	0.98 (0.65–1.47) per cm	0.92
tumor location	NA	0.99	NA	0.97
sex	1.16 (0.39–3.46) for men	0.79	1.21 (0.33–4.43) for men	0.78

* NA = not applicable.

include bone involvement,[34] epidermal growth factor receptor immunoreactivity,[41] non–skull base location, and male sex.[37] Newer imaging techniques, such as diffusion-weighted MRI,[35] diffusion-tensor imaging,[45] or thallium-201 SPECT, may help differentiate benign from atypical meningiomas,[43] although these modalities are unlikely to be widely used in the near future.

Tumor Response by Location

Convexity tumors are the most common atypical meningiomas in most series reporting location in the literature.[1,20] In a survey of 378 meningiomas resected at a single institution over 8 years, the most common locations for Grade II meningiomas were convexity (40%), falcine (18%), sphenoid wing (10%), tuberculum (10%), and olfactory groove (6%).[37] Our cohort displayed a similar distribution, with 60.0% of patients harboring a convexity meningioma. Some authors have highlighted the positive long-term outcomes achievable with GTR for convexity atypical meningiomas,[22,37] suggesting that no adjuvant treatment is necessary for these lesions. However, in our analysis, there was no association in univariate or multivariate analysis between location and outcome (Table 3). Even for convexity atypical meningiomas treated with GTR, there is a potential benefit to postoperative radiotherapy that should be carefully considered.

Response to Radiation Therapy

The published data suggest that the p53 system is intact in atypical meningioma; the p53 pathway is instead deregulated by alterations in p14ARF (cyclin-dependent kinase inhibitor 2A) and MDM2.[3] Therefore, one would expect that these tumors would exhibit some extent of radiation sensitivity.[25] An acquired mutation in p53 may explain atypical meningiomas that recur after radiotherapy.[36] It would ultimately be interesting to compare the p53 status of the recurrent atypical meningiomas with and without radiotherapy. One might posit that atypical meningiomas that recurred after radiotherapy would be p53 mutant while the tumors that recurred without radiotherapy would be p53 wild-type.

Stereotactic radiosurgery has been used for recurrent lesions and as a primary or neoadjuvant treatment.[21,23,29] Other radiotherapy modalities, such as combined proton- and photon-beam conformal radiotherapy or carbon ion radiotherapy, have been used in early phase clinical trials for atypical meningioma with satisfactory safety and efficacy profiles.[4,11] A prospective Phase II study of carbon ion boost in conjunction with photon radiotherapy after Simpson Grade IV or V resection/biopsy of atypical meningioma is currently underway.[10] Nevertheless, radiotherapy alone is insufficient treatment for Grade II meningiomas, which have a high chance of progression after primary radiotherapy.[32,33] There is a growing consensus that favors early postoperative radiotherapy after resection of atypical meningioma based on single institutional series.[34,39] Several series that have reported outcomes after radiotherapy for atypical meningioma did not discern between the use of radiotherapy as primary, adjuvant, or recurrence therapy, obscuring radiotherapy's contribution to decreased risk of recurrence in patients concurrently treated with surgery and/or radiosurgery.[13,38]

Despite significant increases in local control with routine postoperative radiotherapy, early small series demonstrated high recurrence rates, particularly after subtotal resection,[18] suggesting that clinical outcomes are primarily governed by the extent of tumor resection and not the use of adjuvant postoperative radiotherapy. A recent case series by Aghi et al.[1] highlighted the potential for postoperative radiotherapy to reduce rates of recurrence and progression among patients with atypical meningioma who have undergone GTR. In concordance with that study, we found a strong trend toward lower recurrence rates in patients with atypical meningiomas treated with postoperative radiation after GTR (Fig. 3). A recent study of 66 atypical meningiomas treated with GTR reported results similar to those in our series.[27] However, despite a strong trend toward local control with adjuvant radiotherapy, its authors concluded that postoperative radiation therapy is only indicated for atypical meningioma treated with subtotal resection but not for lesions treated with GTR.

Study Limitations

Several factors limit the conclusions that may be drawn from our experience as currently reported. Although there was a difference in rates of recurrence between patients who were treated with postoperative radiotherapy and those who received no adjuvant radiotherapy, the difference did not reach statistical significance, likely due to the small sample size. This is a limitation of most case series reported to date (Table 4). Although 22% of our patients experienced a recurrence by the median follow-up of 44.1 months (representing 71% of total recurrences, postoperative radiotherapy median follow-up 49.4 and 43.9 months for postoperative radiotherapy and no postoperative radiotherapy, respectively), recurrence of an atypical meningioma may occur at a time significantly displaced from the initial resection (1 patient expe-

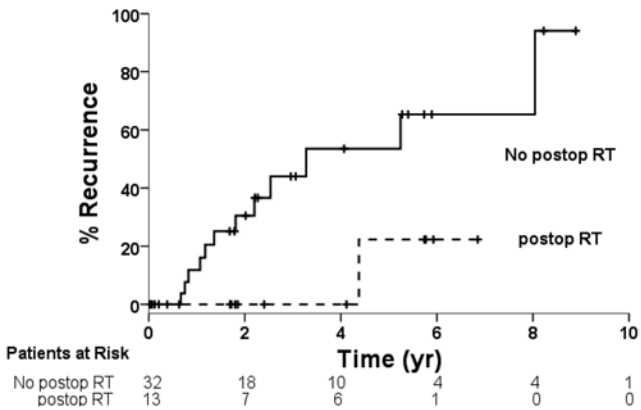

Fig. 3. Kaplan-Meier analysis portraying the percentage of patients with atypical meningiomas treated with GTR who experienced recurrence over time, comparing those who received postoperative radiotherapy (n = 13) with those who did not (n = 32) and revealing a trend toward significantly lower recurrence among those who received radiation therapy (p = 0.085).

TABLE 4: Progression-free and overall survival in atypical meningioma series

Author & Year	No. of Pts	No. of Pts w/ AM	GTR	Postop RT	PFS (%)		OS (%)	
					5-Yr	10-Yr	5-Yr	10-Yr
Alvarez et al., 1987	21	15	15	4	—	—	—	—
Mahmood et al., 1993	25	20	—	—	50	50	60	60
Hoffmann et al., 1995	13	10	7	3	50	—	38	—
Milosevic et al., 1996	59	17	17	59	—	—	28	—
Palma et al., 1997	71	42	14	1	77	55	95	79
Coke et al., 1998	17	9	12	15	—	—	87	58
Goyal et al., 2000	33	33	15	2	71	55	95	79
Hug et al., 2000	31	15	8	8	38	—	89	—
Engenhart-Cabillic et al., 2006	16	11	—	7	—	—	—	—
Ko et al., 2007	49	23	18	12	—	—	—	—
Pasquier et al., 2008	119	82	—	94	58	48	65	51
Yang et al., 2008	74	33	—	—	—	87	—	90
Aghi et al., 2009	108	108	108	8	59	52	—	—
Boskos et al., 2009	24	19	6	24	61	—	54	—
Gabeau-Lacet et al., 2009	47	47	35	11	48	—	86	61
Jo et al., 2010	35	35	11	5	—	—	—	—
Vranic et al., 2010	86	76	36	6	60	55	76	56
Yu et al., 2011	74	74	52	47	—	—	—	—
Mair et al., 2011	114	114	66	30	47	—	—	—

* AM = atypical meningioma; — = not reported.

rienced a recurrence 132 months post-GTR), highlighting the need for prudent routine monitoring to ensure prompt recognition of recurrent disease.

Conclusions

This retrospective case series supports the observation that postoperative radiotherapy may result in lower rates of recurrence of atypical meningiomas that have undergone initial GTR. There was no statistical difference, likely due to low power and a retrospective single-institution experience. However, actuarial recurrence rates at 5 years were close to 42% without radiotherapy and 20% with radiotherapy, and treatment without postoperative radiotherapy was associated with a relative risk of recurrence approximately 5 times greater than with adjuvant postoperative radiotherapy. Recurrences resulted in shortened OS and additional treatment burden, including multiple reoperations, chemotherapeutic regimens, or radiotherapy. Adjuvant radiation therapy should be judiciously used only when a clear benefit is demonstrated, due to the low risk of long-term detrimental effects, including radiation necrosis, deterioration of neurological function, and induction of further tumors. Although a multicenter, prospective trial will ultimately be needed to fully define the role of radiotherapy in the management of patients with atypical meningioma who have a GTR (2 such trials are underway: NCT00626730 and RTOG 0539), our results contribute to a growing number of other series in support of routine postoperative radiotherapy as an adjuvant treatment for these lesions.

Disclosure

The authors report no conflict of interest concerning the materials or methods used in this study or the findings specified in this paper. Dr. Yamada is a consultant for Varian Medical Systems, is on the speakers' bureau for the Institute for Medical Education, and is a board member of the American Brachytherapy Society.

Author contributions to the study and manuscript preparation include the following. Conception and design: Gutin, Komotar, Iorgulescu, Holland, Beal, Bilsky, Brennan, Tabar, Yamada. Acquisition of data: Iorgulescu. Analysis and interpretation of data: Iorgulescu, Raper. Drafting the article: Komotar, Iorgulescu, Raper, Beal, Bilsky. Critically revising the article: all authors. Reviewed submitted version of manuscript: all authors. Statistical analysis: Iorgulescu, Komotoar. Study supervision: Gutin, Komotar.

Acknowledgments

The authors thank Dhanya Anand, M.B.B.S., for her assistance in data collection. They also thank Desert Horse-Grant, Shahiba Ogilvie, and Raquel Sanchez of the Brain Tumor Center at the Memorial Sloan–Kettering Cancer Center for their extraordinary assistance with this project.

References

1. Aghi MK, Carter BS, Cosgrove GR, Ojemann RG, Amin-Hanjani S, Martuza RL, et al: Long-term recurrence rates of atypical meningiomas after gross total resection with or without postoperative adjuvant radiation. **Neurosurgery 64:**56–60, 2009
2. Alvarez F, Roda JM, Pérez Romero M, Morales C, Sarmiento MA, Blázquez MG: Malignant and atypical meningiomas: a reappraisal of clinical, histological, and computed tomographic features. **Neurosurgery 20:**688–694, 1987
3. Amatya VJ, Takeshima Y, Inai K: Methylation of p14(ARF)

gene in meningiomas and its correlation to the p53 expression and mutation. **Mod Pathol 17:**705–710, 2004
4. Boskos C, Feuvret L, Noel G, Habrand JL, Pommier P, Alapetite C, et al: Combined proton and photon conformal radiotherapy for intracranial atypical and malignant meningioma. **Int J Radiat Oncol Biol Phys 75:**399–406, 2009
5. Brat DJ, Parisi JE, Kleinschmidt-DeMasters BK, Yachnis AT, Montine TJ, Boyer PJ, et al: Surgical neuropathology update: a review of changes introduced by the WHO classification of tumours of the central nervous system, 4th edition. **Arch Pathol Lab Med 132:**993–1007, 2008
6. Bruna J, Brell M, Ferrer I, Gimenez-Bonafe P, Tortosa A: Ki-67 proliferative index predicts clinical outcome in patients with atypical or anaplastic meningioma. **Neuropathology 27:**114–120, 2007
7. Chang IB, Cho BM, Moon SM, Park SH, Oh SM, Cho SJ: Loss of heterozygosity at 1p, 7q, 17p, and 22q in meningiomas. **J Korean Neurosurg Soc 48:**14–19, 2010
8. Choy W, Kim W, Nagasawa D, Stramotas S, Yew A, Gopen Q, et al: The molecular genetics and tumor pathogenesis of meningiomas and the future directions of meningioma treatments. **Neurosurg Focus 30(5):**E6, 2011
9. Coke CC, Corn BW, Werner-Wasik M, Xie Y, Curran WJ Jr: Atypical and malignant meningiomas: an outcome report of seventeen cases. **J Neurooncol 39:**65–70, 1998
10. Combs SE, Edler L, Burkholder I, Rieken S, Habermehl D, Jäkel O, et al: Treatment of patients with atypical meningiomas Simpson grade 4 and 5 with a carbon ion boost in combination with postoperative photon radiotherapy: the MARCIE trial. **BMC Cancer 10:**615, 2010
11. Combs SE, Hartmann C, Nikoghosyan A, Jäkel O, Karger CP, Haberer T, et al: Carbon ion radiation therapy for high-risk meningiomas. **Radiother Oncol 95:**54–59, 2010
12. Combs SE, Schulz-Ertner D, Debus J, von Deimling A, Hartmann C: Improved correlation of the neuropathologic classification according to adapted World Health Organization classification and outcome after radiotherapy in patients with atypical and anaplastic meningiomas. **Int J Radiat Oncol Biol Phys 81:**1415–1421, 2011
13. Engenhart-Cabillic R, Farhoud A, Sure U, Heinze S, Henzel M, Mennel HD, et al: Clinicopathologic features of aggressive meningioma emphasizing the role of radiotherapy in treatment. **Strahlenther Onkol 182:**641–646, 2006
14. Gabeau-Lacet D, Engler D, Gupta S, Scangas GA, Betensky RA, Barker FG II, et al: Genomic profiling of atypical meningiomas associates gain of 1q with poor clinical outcome. **J Neuropathol Exp Neurol 68:**1155–1165, 2009
15. Goyal LK, Suh JH, Mohan DS, Prayson RA, Lee J, Barnett GH: Local control and overall survival in atypical meningioma: a retrospective study. **Int J Radiat Oncol Biol Phys 46:**57–61, 2000
16. Harris AE, Lee JY, Omalu B, Flickinger JC, Kondziolka D, Lunsford LD: The effect of radiosurgery during management of aggressive meningiomas. **Surg Neurol 60:**298–305, 2003
17. Hoffmann W, Mühleisen H, Hess CF, Kortmann RD, Schmidt B, Grote EH, et al: Atypical and anaplastic meningiomas—does the new WHO-classification of brain tumours affect the indication for postoperative irradiation? **Acta Neurochir (Wien) 135:**171–178, 1995
18. Hug EB, Devries A, Thornton AF, Munzenride JE, Pardo FS, Hedley-Whyte ET, et al: Management of atypical and malignant meningiomas: role of high-dose, 3D-conformal radiation therapy. **J Neurooncol 48:**151–160, 2000
19. Jo K, Park HJ, Nam DH, Lee JI, Kong DS, Park K, et al: Treatment of atypical meningioma. **J Clin Neurosci 17:**1362–1366, 2010
20. Kane AJ, Sughrue ME, Rutkowski MJ, Shangari G, Fang S, McDermott MW, et al: Anatomic location is a risk factor for atypical and malignant meningiomas. **Cancer 117:**1272–1278, 2011
21. Kano H, Takahashi JA, Katsuki T, Araki N, Oya N, Hiraoka M, et al: Stereotactic radiosurgery for atypical and anaplastic meningiomas. **J Neurooncol 84:**41–47, 2007
22. Ko KW, Nam DH, Kong DS, Lee JI, Park K, Kim JH: Relationship between malignant subtypes of meningioma and clinical outcome. **J Clin Neurosci 14:**747–753, 2007
23. Kondziolka D, Madhok R, Lunsford LD, Mathieu D, Martin JJ, Niranjan A, et al: Stereotactic radiosurgery for convexity meningiomas. Clinical article. **J Neurosurg 111:**458–463, 2009
24. Krayenbühl N, Pravdenkova S, Al-Mefty O: De novo versus transformed atypical and anaplastic meningiomas: comparisons of clinical course, cytogenetics, cytokinetics, and outcome. **Neurosurgery 61:**495–504, 2007
25. Lu C, El-Deiry WS: Targeting p53 for enhanced radio- and chemo-sensitivity. **Apoptosis 14:**597–606, 2009
26. Mahmood A, Caccamo DV, Tomecek FJ, Malik GM: Atypical and malignant meningiomas: a clinicopathological review. **Neurosurgery 33:**955–963, 1993
27. Mair R, Morris K, Scott I, Carroll TA: Radiotherapy for atypical meningiomas. Clinical article. **J Neurosurg 115:**811–819, 2011
28. Marosi C, Hassler M, Roessler K, Reni M, Sant M, Mazza E, et al: Meningioma. **Crit Rev Oncol Hematol 67:**153–171, 2008
29. Mattozo CA, De Salles AAF, Klement IA, Gorgulho A, McArthur D, Ford JM, et al: Stereotactic radiation treatment for recurrent nonbenign meningiomas. **J Neurosurg 106:**846–854, 2007
30. Mawrin C, Perry A: Pathological classification and molecular genetics of meningiomas. **J Neurooncol 99:**379–391, 2010
31. Miao Y, Lu X, Qiu Y, Jiang J, Lin Y: A multivariate analysis of prognostic factors for health-related quality of life in patients with surgically managed meningioma. **J Clin Neurosci 17:**446–449, 2010
32. Milker-Zabel S, Zabel A, Schulz-Ertner D, Schlegel W, Wannenmacher M, Debus J: Fractionated stereotactic radiotherapy in patients with benign or atypical intracranial meningioma: long-term experience and prognostic factors. **Int J Radiat Oncol Biol Phys 61:**809–816, 2005
33. Milosevic MF, Frost PJ, Laperriere NJ, Wong CS, Simpson WJ: Radiotherapy for atypical or malignant intracranial meningioma. **Int J Radiat Oncol Biol Phys 34:**817–822, 1996
34. Modha A, Gutin PH: Diagnosis and treatment of atypical and anaplastic meningiomas: a review. **Neurosurgery 57:**538–550, 2005
35. Nagar VA, Ye JR, Ng WH, Chan YH, Hui F, Lee CK, et al: Diffusion-weighted MR imaging: diagnosing atypical or malignant meningiomas and detecting tumor dedifferentiation. **AJNR Am J Neuroradiol 29:**1147–1152, 2008
36. Ohkoudo M, Sawa H, Hara M, Saruta K, Aiso T, Ohki R, et al: Expression of p53, MDM2 protein and Ki-67 antigen in recurrent meningiomas. **J Neurooncol 38:**41–49, 1998
37. Palma L, Celli P, Franco C, Cervoni L, Cantore G: Long-term prognosis for atypical and malignant meningiomas: a study of 71 surgical cases. **J Neurosurg 86:**793–800, 1997
38. Pasquier D, Bijmolt S, Veninga T, Rezvoy N, Villa S, Krengli M, et al: Atypical and malignant meningioma: outcome and prognostic factors in 119 irradiated patients. A multicenter, retrospective study of the Rare Cancer Network. **Int J Radiat Oncol Biol Phys 71:**1388–1393, 2008
39. Pearson BE, Markert JM, Fisher WS, Guthrie BL, Fiveash JB, Palmer CA, et al: Hitting a moving target: evolution of a treatment paradigm for atypical meningiomas amid changing diagnostic criteria. **Neurosurg Focus 24(5):**E3, 2008
40. Rogers L, Gilbert M, Vogelbaum MA: Intracranial meningiomas of atypical (WHO grade II) histology. **J Neurooncol 99:**393–405, 2010
41. Smith JS, Lal A, Harmon-Smith M, Bollen AW, McDermott

MW: Association between absence of epidermal growth factor receptor immunoreactivity and poor prognosis in patients with atypical meningioma. **J Neurosurg 106:**1034–1040, 2007
42. Smith SJ, Boddu S, Macarthur DC: Atypical meningiomas: WHO moved the goalposts? **Br J Neurosurg 21:**588–592, 2007
43. Takeda T, Nakano T, Asano K, Shimamura N, Ohkuma H: Usefulness of thallium-201 SPECT in the evaluation of tumor natures in intracranial meningiomas. **Neuroradiology 53:**867–873, 2011
44. Tanzler E, Morris CG, Kirwan JM, Amdur RJ, Mendenhall WM: Outcomes of WHO Grade I meningiomas receiving definitive or postoperative radiotherapy. **Int J Radiat Oncol Biol Phys 79:**508–513, 2011
45. Toh CH, Castillo M, Wong AMC, Wei KC, Wong HF, Ng SH, et al: Differentiation between classic and atypical meningiomas with use of diffusion tensor imaging. **AJNR Am J Neuroradiol 29:**1630–1635, 2008
46. Vranic A, Popovic M, Cör A, Prestor B, Pizem J: Mitotic count, brain invasion, and location are independent predictors of recurrence-free survival in primary atypical and malignant meningiomas: a study of 86 patients. **Neurosurgery 67:**1124–1132, 2010
47. Willis J, Smith C, Ironside JW, Erridge S, Whittle IR, Everington D: The accuracy of meningioma grading: a 10-year retrospective audit. **Neuropathol Appl Neurobiol 31:**141–149, 2005
48. Yang SY, Park CK, Park SH, Kim DG, Chung YS, Jung HW: Atypical and anaplastic meningiomas: prognostic implications of clinicopathological features. **J Neurol Neurosurg Psychiatry 79:**574–580, 2008
49. Yu SQ, Wang JS, Ji N, Liu W, Qian K: Clinical characteristics and therapeutic strategies of atypical meningioma. **Chin Med J (Engl) 124:**1094–1096, 2011

Manuscript submitted November 23, 2011.
Accepted July 23, 2012.
Please include this information when citing this paper: published online August 24, 2012; DOI: 10.3171/2012.7.JNS112113.
Address correspondence to: Philip H. Gutin, M.D., Department of Neurosurgery, Memorial Sloan–Kettering Cancer Center, 1275 York Avenue, Room C-703, New York, New York 10065. email: gutinp@mskcc.org.