Neurosurg Focus 33 (3):E8, 2012

The newly diagnosed vestibular schwannoma: radiosurgery, resection, or observation?

Douglas Kondziolka, M.D., F.R.C.S.C.,[1,2] Seyed H. Mousavi, M.D.,[1,2] Hideyuki Kano, M.D., Ph.D.,[1,2] John C. Flickinger, M.D.,[1,3] and L. Dade Lunsford, M.D., F.A.C.S.[1,2]

[1]The Center for Image Guided Neurosurgery and Departments of [2]Neurological Surgery and [3]Radiation Oncology, UPMC, Pittsburgh, Pennsylvania

Object. Management recommendations for patients with smaller-volume or newly diagnosed vestibular schwannomas (< 4 cm^3) need to be based on an understanding of the anticipated natural history of the tumor and the side effects it produces. The natural history can then be compared with the risks and benefits of therapeutic intervention using a minimally invasive strategy such as stereotactic radiosurgery (SRS).

Methods. The authors reviewed the emerging literature stemming from recent recommendations to "wait and scan" (observation) and compared this strategy with published outcomes after early intervention using SRS or results from matched cohort studies of resection and SRS.

Results. Various retrospective studies indicate that vestibular schwannomas grow at a rate of 0–3.9 mm per year and double in volume between 1.65 and 4.4 years. Stereotactic radiosurgery arrests growth in up to 98% of patients when studied at intervals of 10–15 years. Most patients who select "wait and scan" note gradually decreasing hearing function leading to the loss of useful hearing by 5 years. In contrast, current studies indicate that 3–5 years after Gamma Knife surgery, 61%–80% of patients maintain useful hearing (speech discrimination score > 50%, pure tone average < 50).

Conclusions. Based on published data on both volume and hearing preservation for both strategies, the authors devised a management recommendation for patients with small vestibular schwannomas. When resection is not chosen by the patient, the authors believe that early SRS intervention, in contrast to observation, results in long-term tumor control and improved rates of hearing preservation.
(http://thejns.org/doi/abs/10.3171/2012.6.FOCUS12192)

Key Words • **vestibular schwannoma** • **acoustic neuroma** • **outcome** • **radiosurgery** • **observation** • **hearing**

Vestibular schwannomas (acoustic neuromas) are generally slow-growing, intracranial extraaxial benign tumors that usually develop from the vestibular portion of the eighth cranial nerve. The incidence is thought be 1 per 100,000. Although some patients note disequilibrium, vertigo, or tinnitus, progressive unilateral hearing decline is the most common symptom that leads to the diagnosis of a vestibular schwannoma.[22] Because of the earlier use of higher-quality MRI, an increasing number of vestibular schwannomas are diagnosed at a time when patients still have useful or even normal hearing. The anticipated growth pattern (using average diameters) of newly diagnosed vestibular schwannomas has been estimated to be one of the following 3 types: 1) no or very slow growth; 2) slow growth (2 mm/year linear growth on imaging studies); or 3) fast growth (> 8 mm/year). In certain cases a doubling of tumor volume within 12 months has been reported. In fact, the tumor volume doubling time may be a better measure of tumor growth than average tumor diameter.[63] Cystic vestibular schwannomas occasionally demonstrate early enlargement of the cystic component of the tumor. Rarely, intratumoral bleeding may lead to rapid enlargement of the mass.[58]

Since the era of both Cushing and Dandy in the early 20th century, almost all patients with newly diagnosed vestibular schwannomas have undergone attempts at surgical removal of their tumors. Although outcomes in the era of microsurgery greatly improved the quality of life of patients after surgery, the earlier diagnosis of these tumors prompted a comprehensive evaluation of less invasive management strategies. In 1969 SRS was first advocated by Leksell and Norén as a potential alternative surgical procedure.[28] Since then, more than 50,000 patients worldwide have undergone SRS using the Leksell Gamma Knife (AB Elekta). This incision-free procedure, as well as other linear accelerator–based technolo-

Abbreviations used in this paper: GKS = Gamma Knife surgery; LINAC = linear accelerator; SRS = stereotactic radiosurgery; SRT = stereotactic radiotherapy.

gies, has greatly expanded the management options for patients with vestibular schwannomas. Patients no longer need to choose simply between craniotomy or observation, a strategy that only makes sense if such tumors cease to grow after initial recognition and cease to cause additional neurological dysfunction.

Increasingly, patients with small tumors are choosing not to undergo resection in favor of a less invasive approach, either observation or irradiation. We believe that early diagnosis and early SRS provide the highest likelihood of achieving the twin goals of successful management: tumor control and maintenance of existing neurological function. Referring physicians and affected patients need to know the long-term risk/benefit ratio of initial observation versus initial SRS.

Observation: the "Wait and Scan" Option

The basic premise of this hypothesis is 2-fold: 1) that the vestibular schwannomas grew but will not grow further after recognition; and 2) that even if some growth is confirmed over time, generally thought to be many years, the patient will maintain a higher level of function than if early treatment is performed.[3,64] The observation strategy was first proposed for elderly patients or those with significant medical comorbidities with an estimated lifespan of less than the growth/symptom progression rate of the vestibular tumor.[15] The patient is evaluated periodically for symptom assessment, and follow-up MRI scans are obtained to monitor the tumor for signs of growth.[59] The ostensible goal of serial observation is to obviate treatment until growth (or perhaps symptom worsening) is confirmed.[15,48] In the elderly, the goal may be to avoid any treatment during the remaining years of life. In the younger patient, it may be to defer potential complications associated with treatment for as long as possible. In our combined 52-year experience in the management of vestibular schwannomas referred to our center, we have observed that 70% patients have measurable growth within 5 years, increasing to more than 95% by the time 10 years has elapsed. Recent reports continue to define annual tumor growth rates of 1–3 mm/year in at least 1 plane. Extracanalicular tumors may progress at an even faster rate,[12] perhaps related to the easier determination of volumetric changes in larger tumors.

Simple linear tumor measurements are associated with a number of problems in the volumetric assessment of tumor growth.[23] First, measurements are dependent on image type, quality, slice thickness, and contrast administration. During the last 20 years high-definition multiplanar MRI has evolved. Axial T2-weighted 1-mm-slice MRI and T1-weighted contrast-enhanced axial and coronal MRI are the only current methods that provide a reasonable way to measure tumor volumes. Computed tomography scanning is insufficient to allow such volumetric measurements. Second, high-resolution MRI must be performed at annual intervals to plot out a reliable tumor growth rate. Third, measurements must be made in the same planes on each scan to maintain consistency. Most screening MRI scans use a 256 × 256 grid, which indicates a pixel size of 1 mm. Since measurements are made by "eyeballing" the 3 tumor diameters (x, y, and z), it has proven almost impossible to differentiate 1- to 2-mm changes in a single plane. Ideally, it is tumor volume that we truly want to know. The lack of simple volumetric tools such as summated region of interest areas in the MRI scanner software makes tumor volume estimates unreliable.

Varughese et al.[63] described their experience with conservative management of patients who had a vestibular schwannoma between 2000 and 2006. The authors evaluated both linear diameter measurements and provided volumetric calculations. The duration of follow-up was not reported. Volume changes were reported according to the "volume doubling time," which they concluded best described the growth rate of untreated tumors. In that report the tumor volume doubling time was 4.40 years. Other authors have reported that tumor volume doubling times range from 1.65 to 2.3 years. During this observation period, many patients will experience deterioration in hearing or may suddenly lose their hearing even without imaging-defined growth. Many patients will also note the development of symptoms such as tinnitus, vertigo, or disequilibrium.

Varughese et al.[63] concluded that "wait and scan" was a realistic option for patients with small vestibular schwannomas. With more widespread MRI screening of patients who present with unilateral hearing dysfunction, tinnitus, or vestibular disorders, early intervention with a minimally invasive procedure offers an option that improves hearing preservation rates compared with observation.[49,54] The patient and referring physicians should have access to available data to devise a balanced initial management strategy.

Régis et al.[49] performed a study to compare a "wait and scan" strategy with GKS in patients with intracanalicular vestibular schwannomas. Forty-seven patients were in the observation arm, and 34 underwent early GKS (median dose 12 Gy to the 50% isodose). The median follow-up was 34.7 months. Conservative management failed in 35 patients (74%), indicated by documented tumor growth or worsening of hearing. During the observation period, 10 patients (21%) had no change in tumor size, 36 (77%) had tumor growth, and 1 (2%) had a slight decrease in tumor size. The authors also studied the tumor volume doubling time in 35 patients. The doubling time was less than 1 year in 11 patients (31%), 1–3 years in 18 (51%), and longer than 3 years in 6 (17%). In the radiosurgery group, 31 patients (66%) had useful hearing at the time of diagnosis. Twenty-one patients (68%) retained useful hearing, but 10 (32%) lost useful hearing during follow-up. Régis et al. confirmed that tumor control and functional hearing preservation rates were higher in patients who underwent early GKS (88%, 79%, and 60% at 1, 2, and 5 years, respectively). In contrast, in patients who underwent observation, hearing preservation rates were 78%, 43%, and 14% at 1, 2, and 5 years, respectively. In this study the useful hearing preservation rate also was better in patients who underwent SRS (77%, 70%, and 64% at 3, 4, and 5 years, respectively) than in those who underwent "wait and scan" (75%, 52%, and 41% at 3, 4, and 5 years, respectively). This study supports our belief

that observation results in tumor growth and hearing deterioration at a much greater degree than does early SRS, at least early GKS.

Shirato et al.[54] compared observation with fractionated SRT in patients with vestibular schwannomas. Twenty-seven patients were observed, and 50 underwent SRT with mean follow-up periods of 35 and 31 months, respectively. In the SRT group, 37 patients underwent the procedure as primary tumor management and 13 had SRS after a prior resection (all 13 were deaf). In the SRT group, 34 had measureable hearing before treatment compared with 23 of 27 in the observation group. The mean tumor diameter was 18 mm. Eight patients were noted to have tumor enlargement (transient in 6) greater than 2 mm after SRT within the first 2 years. One patient underwent a later resection (2%). Eleven patients (41%) in the observation group required salvage therapy at 21 months or later; 7 (26%) underwent resection; and 4 (15%) had SRT. The mean tumor growth rate was 3.87 mm/year for the observation group and −0.75 mm/year for the SRT group. Preservation of Gardner-Robertson class hearing rates at 3 and 5 years' follow-up were 61% and 31%, respectively, for the observation group compared with 53% at both 3 and 5 years in the SRT group.

In a recent report, Rasmussen et al.[47] compared outcomes of 42 patients following fractionated SRT using mask localization (54 Gy in 27–30 fractions) with a cohort of 409 control individuals who were observed. They noted that fractionated radiotherapy accelerated hearing loss and that cochlear dose was relevant. In the observation group, hearing deterioration was not dependent of tumor growth. By 5 years, half of these patients had lost hearing. The authors believed that their results showed that fractionated radiotherapy was not superior to radiosurgery and that it appeared to accelerate hearing loss rather than prevent it. The use of 54 Gy may indeed be excessive. Mask localization rather than stereotactic frame–based localization may also have contributed to their results.

Between 1990 and 2005, Bakkouri et al.[2] evaluated 386 patients who harbored unilateral vestibular schwannomas. At 1 year, 61 patients were lost to follow-up, and the strategy was discontinued for another 77 patients (24%) due to tumor growth (> 3 mm for 43%). Neurological symptoms that developed included disabling vertigo (in 11 patients [14%]) and hearing deterioration (in 29 [38%]) Six patients requested surgery. The annual tumor growth rate was less than 1 mm/year in 59%, 1–3 mm/year in 29%, and greater than 3 mm/year in 12%. Despite the absence of long-term data, the authors continued to advocate observation for patients whose tumors initially showed a "slow growth rate."

Martin et al.[34] analyzed 320 patients who underwent observation after an intracanalicular tumor or a tumor smaller than 2 cm in diameter was found. The mean follow-up was 43 months, and 276 patients had at least 1 follow-up image. Sixty-two patients (22%) exhibited tumor growth, a rate that increased to 90% within 3 years. The average annual growth rate was 4 mm/year. The authors believed that 65% of the tumors grew slowly (0.5–5 mm/year) and 35% grew rapidly (> 5–17 mm/year). This study also indicated that cystic tumors were more likely to enlarge and to do so at a faster rate.

Hajioff et al.[12] studied 72 patients with unilateral tumors with an extended median follow-up of 121 months. The median tumor diameter growth rate at 10 years was 1 mm/year. The median tumor size at the time of diagnosis was 9.8 mm. The authors found that extracanalicular tumors tended to grow faster than intracanalicular tumors. During the follow-up period, conservative management failed in 25 patients (35%). During the first 5-year follow-up period after diagnosis, conservative treatment failed in 75% of these patients at an average of 37 months, and 1 patient died. During follow-up, 29 patients (40%) exhibited growth of greater than 1 mm/year (50% of cerebellopontine angle tumors and 6% of intracanalicular tumors). Twenty-seven patients (38%) experienced a growth rate of less than 1 mm/year, and 16 (22%) remained unchanged. Audiometric follow-up in 40 patients at 80 months showed that most patients had significant hearing loss even in the absence of measurable tumor growth. Hearing loss was worse in the presence of measurable tumor growth (the mean speech discrimination score deteriorated by 40%).

A review of 47 patients with unilateral intracanalicular schwannomas was performed by Pennings et al.[42] to evaluate hearing function during a period of observation. The mean follow-up was 3.6 years. Nineteen patients (40%) had tumor growth greater than 2 mm (8 patients underwent treatment), 24 (51%) had stable tumors, and 4 (9%) had slight tumor regression. All patients showed hearing degradation during follow-up. The mean pure tone average at the first audiogram was 37.5 dB, which diminished to 50.9 dB at the time of the last audiogram. The speech discrimination scores decreased from 66.2% to 54.5%. Despite the documentation of both tumor progression and hearing deterioration in many patients, the authors continued to recommend observation rather than intervention.

Sughrue et al.[57] performed a literature analysis that combined data of 982 patients from 34 studies. The follow-up period varied from 26 to 52 months. The authors found a mean growth rate of 2.9 mm/year. Patients with slower-growing tumors (< 2.5 mm/year) had higher hearing preservation rates. The authors concluded that the growth rate was a more important predictor of hearing loss than the initial tumor diameter. Figure 1 indicates a decision analysis tree for patients after initial diagnosis.

Stereotactic Radiosurgery: the Minimally Invasive Treatment Option

Stereotactic radiosurgery for vestibular schwannoma using the Gamma Knife has been practiced for more than 40 years. Long-term outcome results have established SRS as an important, minimally invasive alternative to resection. Stereotactic radiosurgery is likely the most common procedure performed for smaller vestibular tumors, although the case volume of patients receiving fractionated radiotherapy is not known. Advanced dose planning software, intraoperative high-resolution MRI, dose optimization, and robotic delivery reflect the evolution of this technology. To reduce risk, various image-guided lin-

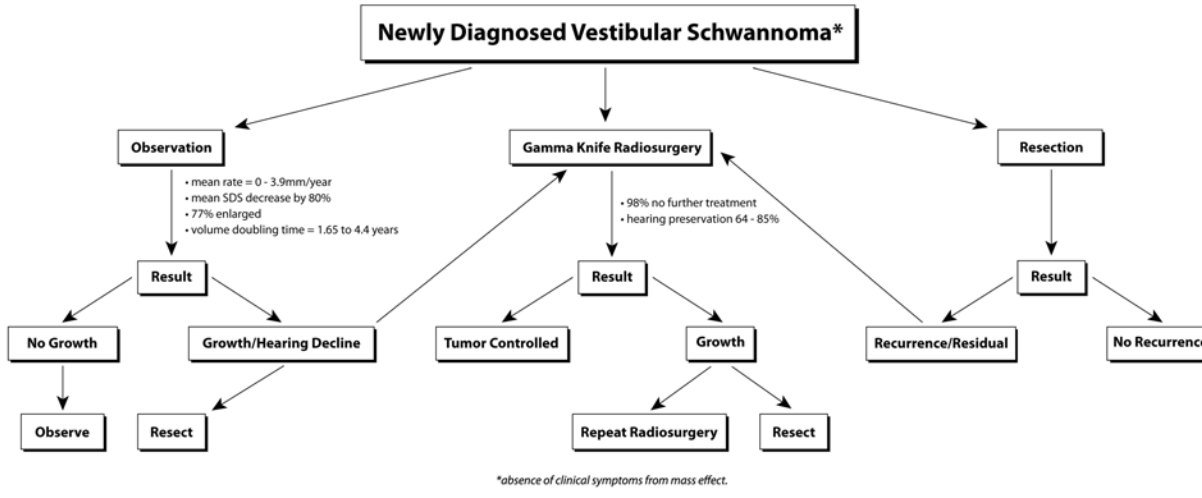

Fig. 1. Decision chart for vestibular schwannoma management. SDS = speech discrimination score.

ear accelerator devices (such as Trilogy, Synergy S, Novalis, and CyberKnife) are often used under fractionation schedules of 3–30 sessions. Proton beam technology is also used to deliver fractionated radiation therapy. The goals of SRS for vestibular schwannoma include prevention of further tumor growth and preservation of existing neurological function.

Optimizing Radiosurgical Dose Planning

Image interpretation, dose planning, and dose delivery are 3 critical components of successful radiosurgery. Complete volumetric conformal and selective tumor radiosurgery improves the rates of facial, cochlear and trigeminal nerve preservation.[29] Reduction of the dose delivered to the brainstem is especially relevant during treatment of larger tumors. Specific GKS techniques include accurate MRI-based definition (or CT-based definition in patients ineligible for MRI) of the tumor volume, use of multiple isocenters, beam weighting, and selective use of beam-blocking patterns to reduce the dose to adjacent critical structures. This degree of conformality can be achieved through multiple isocenter planning, typically by using small beam diameters. A series of 4 mm isocenters are used to create a tapered isodose plan to conform to the intracanalicular portion of the tumor.

Dose Selection

After optimizing the computer dose plan, a maximum and marginal tumor edge dose is prescribed. In GKS a dose of 12–13 Gy is typically prescribed to the 50% (or other) isodose line that conforms to the 3D tumor margin. The most common dose is 12.5 Gy and is most often prescribed to maximize hearing preservation in patients with smaller tumors. We prescribe 12 Gy to the tumor margin of larger tumors. For patients with deafness related to prior resection, we often prescribe 13 Gy to the tumor margin. These marginal doses are associated with a low complication rate and yet maintain a high rate of tumor control. Although experienced centers including the Gamma Knife group from the Hopital Timone in Marseille often use marginal doses of 11 Gy, we suspect that further dose reduction is unlikely to improve hearing preservation rates and may lead to higher rates of tumor progression after many years.[61] Doses in the range of 12–13 Gy at the margin are also used for patients with bilateral (neurofibromatosis Type 2–related) vestibular schwannomas and for patients with contralateral deafness from other causes, for whom hearing preservation is highly desirable.

After prescribing the tumor margin dose, we use computer software to outline adjacent critical structures and then measure the mean dose to the cochlea, semicircular canals, and brainstem. Long-relaxation time (T2) 1-mm axial plane volumetric MRI is necessary to identify the cochlea for dose planning. A mean cochlear dose less than 4.2 Gy may be important for hearing preservation,[19] a finding confirmed by others.[13,61] The majority of the tumor volume receives a radiobiological dose up to 4 times the biologically equivalent dose delivered by fractionated image-guided radiation therapy. The maximum radiosurgical dose of 25 Gy may be radiobiologically equivalent to 100 Gy of fractionated radiation. The SRS technology must also be able to restrict the dose to adjacent structures by having a very sharp dose gradient at the tumor edge. While many radiosurgical centers have evolved toward similar dose selection parameters, the doses and regimens chosen for fractionated radiotherapy continue to vary.

Gamma Knife Surgery: Clinical Results

Long-term results of GKS for vestibular schwannomas have been documented.[5,8,14,24,27,33] Recent reports suggest a tumor control rate of 93%–100% after radiosurgery.[5–11,14,16–18,21,24–27,29–33,38,41,43,45,46] Kondziolka et al.[26] studied 5- to 10-year outcomes in 162 patients with vestibular schwannomas who had undergone radiosurgery at the University of Pittsburgh. In this study a long-term 98% tumor control rate was reported. In further analysis of this cohort, the median follow-up for the 136 patients still living at the time of the study was 10.2 years. Serial imaging studies obtained after radiosurgery in 157

patients showed a decrease in tumor size in 114 patients (73%), no change in 40 patients (25.5%), and an increase in 3 patients who later underwent resection (1.9%).[26,27] No patient developed a radiation-associated malignant or benign tumor (defined as a histologically confirmed and distinct neoplasm arising in the initial radiation field after at least 2 years have passed). In patients younger than 40 years with minimum 4-year follow-up, all remained employed and active.[32] Only 2% of patients required tumor resection after radiosurgery. Norén,[41] in his 28-year experience with radiosurgery for vestibular schwannomas, reported a 95% long-term tumor control rate. Niranjan et al.[40] analyzed the outcome of intracanalicular tumor radiosurgery performed at the University of Pittsburgh. All patients had imaging-documented tumor growth control.

Hearing Preservation

Preradiosurgery hearing can now be preserved in 60%–90% of patients. The best hearing preservation rates are found in patients with smaller tumors. In a long-term (5- to 10-year follow-up) study conducted at the University of Pittsburgh, 51% of patients had no change in hearing.[7,26] All patients who were treated with a margin dose of 14 Gy or less maintained a serviceable level of hearing after intracanalicular tumor radiosurgery.[40] Among patients treated after 1992, the 5-year actuarial rates of hearing level preservation and speech preservation were 75.2% and 89.2%, respectively, for 89 patients treated with a 13-Gy tumor margin dose.

In a longer-term assessment of hearing at a median of 6 years, the same Gardner-Robertson level was preserved in 71%, serviceable hearing was confirmed in 74%, and any testable hearing was present in 95%. For intracanalicular tumors, these rates were 84%, 92%, and 100%, respectively. Our recent research has shown that the mean cochlear dose is important for hearing preservation. Seventy-seven patients with serviceable hearing (Gardner-Robertson Classes I and II) underwent GKS between 2004 and 2007.[19] This interval reflects a period when newer dose planning systems facilitate measurements of dose delivered to critical structures such as the cochlea, trigeminal nerve, and brainstem. The median tumor volume was 0.75 cm^3 (range 0.07–7.7 cm^3), and the median marginal dose was 12.5 Gy (range 12–13 Gy). At diagnosis, a longer distance from the lateral tumor to the end of the internal auditory canal correlated with better hearing. At a median of 20 months, no patient required any additional management. Serviceable hearing was preserved in 71% of patients but in 89% of patients who had Class I hearing (46 patients). Significant prognostic factors for serviceable hearing preservation were Gardner-Robertson Class I, pre-SRS speech discrimination scores of 80% or more, pre-SRS pure tone averages of less than 20 dB, patient age younger than 60 years, intracanalicular tumor location, and tumor volumes less than 0.75 cm^3. All 12 patients younger than 60 years old with a cochlear dose of less than 4.2 Gy maintained serviceable hearing at 2 years. An average cochlea dose of less than 4.2 Gy was associated with better hearing, a finding similar to the dose of 4 Gy noted from Marseille. Younger age is also important for hearing preservation with age under 60 (Pittsburgh group[19]) or 50 (Marseille group[61]) being relevant.

Recently, Hasegawa et al.[13] provided data on 117 patients who underwent GKS and had a median follow-up of 7 years. The tumor control rate was 97.5%, which is similar to that reported by other centers. The cochlear dose again proved important. In a subset of patients with Grade I hearing who were treated using current techniques, the 3- and 5-year hearing preservation rates were 80% and 70%, respectively.

In 2010, Yang et al.[66] performed a systematic literature review of the results of GKS hearing preservation. Forty-five articles that included 4234 patients provided the data. The mean follow-up was 44 months. Overall, the hearing preservation rate was 61% with a dose of 13 Gy or lower, and 50.4% at more than 13 Gy. Neither patient age nor tumor volume correlated with hearing preservation.

Facial Nerve and Trigeminal Nerve Preservation

Facial and trigeminal nerve function can now be preserved in the majority of patients (> 95%). In a study using MRI-based dose planning, a 13-Gy tumor margin dose was associated with a 0% risk of new facial weakness and a 3.1% risk of trigeminal sensory loss (5-year actuarial rates). A margin dose of less than 14 Gy was associated with a 2.5% risk of new facial weakness and a 3.9% risk of trigeminal sensory loss.[8] No patient who underwent radiosurgery for an intracanalicular tumor developed new facial or trigeminal neuropathies. In the current 12- to 13-Gy dose range, any degree of facial weakness is exceedingly rare.

Linear Accelerator Radiosurgery: Clinical Results

Suh et al.[59] evaluated 29 patients treated with a modified linear accelerator stereotactic radiosurgery system. The median margin dose was 1600 cGy. The 5-year local disease control rate was 94%. Long-term complications included new or progressive trigeminal and facial nerve deficits (estimated 5-year incidence) of 15% and 32%, respectively. Subjective hearing reduction or loss occurred in 14 (74%) of the 19 patients who had useful hearing prior to treatment. Since there was a high risk of cranial neuropathy, these authors did not recommend using only CT-based planning and high prescription doses. Spiegelmann et al.[56] reported their results of LINAC radiosurgery for 44 patients with vestibular schwannomas. After a mean follow-up period of 32 months (range 12–60 months), 98% of the tumors were controlled. The actuarial hearing preservation rate was 71%. New transient facial neuropathy developed in 24% of the patients and persisted to a mild degree in 8%. The University of Florida group published clinical outcomes in a series of 390 patients, with a high control rate and a facial neuropathy rate of 0.7% using current techniques and dose.[10]

Stereotactic Radiation Therapy: Clinical Results

Stereotactic radiation therapy or fractionated SRT refers to the delivery of a standard fractionation scheme of

radiation, used with rigidly applied or relocatable stereotactic-guiding devices. Many LINAC-based radiosurgery centers (driven by the desire to reduce complication rates) use dose fractionation for vestibular schwannomas.[18,36,44,52–55,59,60] Ishihara et al.[18] reported a 94% tumor control rate at a median follow-up of 31.9 months in a series of 38 patients who underwent CyberKnife radiosurgery for vestibular schwannoma. One patient developed transient facial paresis (2.6%) and another developed trigeminal nerve neuropathy (2.6%). Fuss et al.[11] described 51 patients with vestibular schwannomas who were treated with SRT. The mean follow-up period was 42 months, and the actuarial 5-year tumor control rate was 95%. One patient developed a transient facial nerve paresis, and 2 noted new trigeminal dysesthesias. Chung et al.,[4] using SRT for 25 patients with useful hearing, reported 57% hearing preservation at 2 years. The mean pre- and post-SRT speech recognition threshold was 20 and 38 dB, respectively. The mean proportion of pre- and post-SRT speech discrimination was 91% and 59%, respectively.

Sawamura et al.[53] treated 101 patients with vestibular schwannomas using fractionated SRT to a total dose of 40–50 Gy, administered in 20–25 fractions over a 5- to 6-week period. The median follow-up period was 45 months, and the actuarial 5-year tumor control rate was 91.4%. The actuarial 5-year rate of useful hearing preservation (Gardner-Robertson Class I or II) was 71%. The complications of fractionated SRT included transient facial nerve palsy (4%), trigeminal neuropathy (14%), and balance disturbance (17%). Eleven patients (11%) developed progressive communicating hydrocephalus after SRT and required a shunt.

Meijer et al.[35] performed a single-institution trial to study whether fractionated stereotactic radiation therapy is superior to single-session LINAC-based radiosurgery. They assessed treatment-related toxicity and local tumor control in patients with vestibular schwannomas. These authors analyzed 129 patients with vestibular schwannomas who were treated at an LINAC-based radiosurgery facility. Stereotactic radiation therapy was performed in 80 patients with a relocatable guidance device using 5 sessions that delivered either 4 or 5 Gy to the tumor margin at the 80% isodose. Forty-nine patients had SRS of 1 × 10 Gy and later 1 × 12.5 Gy at the 80% isodose using a stereotactic frame. There was no statistically significant difference between the single-fraction group and the fractionated group with respect to mean tumor diameter (2.6 vs 2.5 cm) or mean follow-up time (both 33 months). Outcome differences between the single-session group and the fractionated treatment group with respect to 5-year local control probability (100% vs 94%), 5-year facial nerve preservation probability (93% vs 97%), and 5-year hearing preservation probability (75% vs 61%) were not statistically significant.

Andrews et al.[1] published the Thomas Jefferson University experience using stereotactic radiotherapy at a total dose of 50.4 or 46.8 Gy. In patients with Class I or II hearing, the median follow-up was 65 weeks. Although no patient had later tumor growth, the hearing preservation rates were better at the lower dose. At 3 years, the hearing preservation rate was 55%–60%, and no patient with Class II hearing maintained hearing if they received the 50-Gy dose.[1] Based on these findings, the group reported the use of even lower doses to try to improve hearing outcomes (D. W. Andrews, personal communication, meeting of the Acoustic Neuroma Association, 2011). As noted above, Rasmussen et al.[47] concluded that fractionated radiotherapy at a dose of 54 Gy (higher than used in the Thomas Jefferson University report), appeared to accelerate hearing loss.

Kapoor et al.[20] published outcomes after fractionated SRT from Johns Hopkins Hospital in 496 patients, of whom 385 had follow-up. Radiation was administered in five 5-Gy fractions or ten 3-Gy fractions. Resection was later performed in 3%. Attempted hearing preservation is often given as a reason why some centers choose to use fractionated radiotherapy, but hearing results were not provided.

The Risk of Delayed Malignancy

The risk of a benign or malignant secondary tumor development after SRS has been suggested as a reason to continue observation rather than to perform early radiosurgery. After fractionated external-beam radiation therapy, this risk may be as high as 2%, as has been reported many years after such radiation therapy for pituitary tumors.[39] Delayed oncogenesis following radiosurgery is rare because the target and regional tissue volume irradiated are small, the procedure results in only a single radiation exposure, and the high central dose more likely leads to cell death rather than cell transmutation. There are case reports after radiosurgery or radiotherapy.[62,65] Although we quote to our radiosurgery patients a less than 1:1000 risk of secondary tumor formation over a 5- to 30-year follow-up period, this figure is almost certainly too high.[39] Neither the incidence nor the prevalence of secondary radiation-related tumors is known despite the more than 40 years of radiosurgery experience using the Gamma Knife. Rowe et al.[51] reviewed their experience in 5000 patients treated with SRS and 30,000 patient-years of follow-up. More than 1200 patients had delayed assessments beyond 10 years. The authors detected a single new brain astrocytoma but anticipated 2.47 cases based on population incidence statistics.

Comparison of GKS and Resection: Level 2 Studies

Patients with small vestibular schwannomas may choose resection as their initial form of care or after a period of observation when growth or new symptoms develop. Results after surgery are dependent on surgeon experience. There can be strong opinions about the different treatment choices. Thus, we reviewed the available comparative literature. Despite these available reports, patient selection bias, personal choice, physician skill, and quality of data collection all remain important variables that can affect outcome. There is a large case-series literature on outcomes after resection that continues to evolve. Individual outcomes are dependent on the factors noted earlier, including surgeon goals for each patient.

Unfortunately, it is likely that a randomized clinical trial will probably never be completed to compare resection with radiosurgery for vestibular schwannomas. However, there are several well-matched (Level 2) cohort studies that compare outcomes for patients with tumors smaller than 2.5 cm in extracanalicular diameter. Karpinos et al.[21] analyzed 96 patients with unilateral vestibular schwannomas treated using the Leksell Gamma Knife or microsurgery and concluded that radiosurgery was associated with a lower rate of immediate and long-term development of facial and trigeminal neuropathy, postoperative complications, and hospital stay. Radiosurgery yielded better measurable hearing preservation than microsurgery and equivalent serviceable hearing preservation rate and tumor growth control.

Between 1990 and 1991, Pollock et al.[46] studied 87 patients who were treated treated at the University of Pittsburgh and had unilateral, previously unoperated vestibular schwannomas with an average diameter of less than 3 cm. In this matched cohort trial preoperative patient characteristics and average tumor size were similar between the treatment groups. Microsurgical or radiosurgical techniques were used by experienced surgeons in both treatment groups. The treatment groups were compared based on cranial nerve preservation, tumor control, postoperative complications, patient symptoms, length of hospital stay, total management charges, effect on employment status, and overall patient satisfaction. Stereotactic radiosurgery was more effective in preserving normal postoperative facial function and hearing preservation with less treatment associated morbidity. Effect on preoperative symptoms was similar between the treatment groups. Postoperative functional outcomes and patients' satisfaction were greater after radiosurgery when compared with microsurgery. Patients returned to independent functioning sooner after radiosurgery. Hospital length of stay and total management charges were less in the radiosurgical group.

In a similar study of patients with vestibular schwannomas, Régis et al.[50] used objective results and questionnaire answers to compare the results of radiosurgery (97 consecutive patients) with a microsurgery group (110 patients who fulfilled the inclusion criteria). Questionnaire answers indicated that 100% of patients who underwent GKS compared with 63% of patients who underwent microsurgery had no new facial motor disturbance. The mean hospitalization stay was 3 days after radiosurgery and 23 days after microsurgery. All working patients who underwent SRS kept the same professional activity, compared with 56% in the microsurgery arm. The mean time away from work was 7 days for the SRS group compared with 130 days for the microsurgery group. Among patients whose preoperative hearing level was Class I according to the Gardner-Robertson scale, 70% had preserved functional hearing after radiosurgery (Class I or II), compared with only 37.5% in the microsurgery group. At 4 years of follow-up, GKS provided better functional outcomes than microsurgery. It was concluded that radiosurgery was an effective and less costly management strategy for unilateral vestibular schwannomas smaller than 3 cm in diameter, and it should be considered a primary management option.

In another study, Myrseth et al.[38] compared the quality of life outcomes for 189 patients treated with either microsurgery or radiosurgery, who harbored vestibular schwannomas that were less than 30 mm in diameter. The outcome analysis included assessments of tumor control, cranial nerve preservation rates, and complications. The results showed that cranial nerve function and overall patient outcomes were better in the radiosurgery group. The results reveal that from the patients' perspective, radiosurgery provides a more desirable outcome than microsurgery. A second 2009 report confirmed these findings.[37] Pollock et al.[45] prospectively collected data on patients undergoing either resection or GKS at the Mayo Clinic and found similar or better outcomes after radiosurgery, including quality of life measures.

Conclusions

Numerous studies show that vestibular schwannomas have variable growth rates. Tumor volume in some patients may be linear; in others it may be stepwise. By 10 years most clinical experience demonstrates that the vast majority of patients will have tumor growth. As the tumor grows, cranial nerve function, especially hearing, is likely to deteriorate. Hearing loss may progress even without imaging-defined growth. Linear growth measurements are not sensitive to 3D changes in tumor volume, which may be better understood according to the tumor volume doubling time calculation. Stereotactic radiosurgery arrests the growth of almost all vestibular schwannomas. When performed at experienced centers, cranial nerve function is preserved and quality of life is enhanced. When applied early after tumor diagnosis, useful hearing is much more likely to be preserved. Fractionated radiotherapy techniques have shown less consistent outcomes. Matched cohort studies show that radiosurgery has either better or similar outcomes to resection, depending on the outcome measured. The "wait and scan" option has been advocated in recent years, especially since the minimally invasive strategy of radiosurgery emerged. We believe that "wait and scan" only makes sense in patients whose medical comorbidities indicate a high likelihood of death from other causes in the next 5 years of life.

Disclosure

Dr. Kondziolka is a consultant for AB Elekta. Dr. Lunsford owns stock in and is a consultant for AB Elekta.

Author contributions to the study and manuscript preparation include the following. Conception and design: Kondziolka, Lunsford. Analysis and interpretation of data: Kano, Flickinger, Mousavi. Drafting the article: Kondziolka, Lunsford, Flickinger, Mousavi. Critically revising the article: Lunsford, Kano, Flickinger. Reviewed submitted version of manuscript: Kondziolka, Lunsford. Approved the final version of the manuscript on behalf of all authors: Kondziolka.

References

1. Andrews DW, Werner-Wasik M, Den RB, Paek SH, Downes-Phillips B, Willcox TO, et al: Toward dose optimization for fractionated stereotactic radiotherapy for acoustic neuromas: comparison of two dose cohorts. **Int J Radiat Oncol Biol Phys 74:**419–426, 2009

2. Bakkouri WE, Kania RE, Guichard JP, Lot G, Herman P, Huy PT: Conservative management of 386 cases of unilateral vestibular schwannoma: tumor growth and consequences for treatment. Clinical article. **J Neurosurg 110:**662–669, 2009
3. Charabi S, Tos M, Thomsen J, Charabi B, Mantoni M: Vestibular schwannoma growth—long-term results. **Acta Otolaryngol Suppl 543:**7–10, 2000
4. Chung HT, Ma R, Toyota B, Clark B, Robar J, McKenzie M: Audiologic and treatment outcomes after linear accelerator-based stereotactic irradiation for acoustic neuroma. **Int J Radiat Oncol Biol Phys 59:**1116–1121, 2004
5. Chung WY, Liu KD, Shiau CY, Wu HM, Wang LW, Guo WY, et al: Gamma knife surgery for vestibular schwannoma: 10-year experience of 195 cases. **J Neurosurg 102 Suppl:**87–96, 2005
6. Delbrouck C, Hassid S, Massager N, Choufani G, David P, Devriendt D, et al: Preservation of hearing in vestibular schwannomas treated by radiosurgery using Leksell Gamma Knife: preliminary report of a prospective Belgian clinical study. **Acta Otorhinolaryngol Belg 57:**197–204, 2003
7. Flickinger JC, Kondziolka D, Niranjan A, Lunsford LD: Results of acoustic neuroma radiosurgery: an analysis of 5 years' experience using current methods. **J Neurosurg 94:**1–6, 2001
8. Flickinger JC, Kondziolka D, Niranjan A, Maitz A, Voynov G, Lunsford LD: Acoustic neuroma radiosurgery with marginal tumor doses of 12 to 13 Gy. **Int J Radiat Oncol Biol Phys 60:** 225–230, 2004
9. Flickinger JC, Kondziolka D, Pollock BE, Lunsford LD: Evolution in technique for vestibular schwannoma radiosurgery and effect on outcome. **Int J Radiat Oncol Biol Phys 36:**275–280, 1996
10. Friedman WA, Bradshaw P, Myers A, Bova FJ: Linear accelerator radiosurgery for vestibular schwannomas. **J Neurosurg 105:**657–661, 2006
11. Fuss M, Debus J, Lohr F, Huber P, Rhein B, Engenhart-Cabillic R, et al: Conventionally fractionated stereotactic radiotherapy (FSRT) for acoustic neuromas. **Int J Radiat Oncol Biol Phys 48:**1381–1387, 2000
12. Hajioff D, Raut VV, Walsh RM, Bath AP, Bance ML, Guha A, et al: Conservative management of vestibular schwannomas: third review of a 10-year prospective study. **Clin Otolaryngol 33:**255–259, 2008
13. Hasegawa T, Kida Y, Kato T, Iizuka H, Yamamoto T: Factors associated with hearing preservation after Gamma Knife surgery for vestibular schwannomas in patients who retain serviceable hearing. Clinical article. **J Neurosurg 115:**1078–1086, 2011
14. Hasegawa T, Kida Y, Kobayashi T, Yoshimoto M, Mori Y, Yoshida J: Long-term outcomes in patients with vestibular schwannomas treated using gamma knife surgery: 10-year follow up. **J Neurosurg 102:**10–16, 2005
15. Hoistad DL, Melnik G, Mamikoglu B, Battista R, O'Connor CA, Wiet RJ: Update on conservative management of acoustic neuroma. **Otol Neurotol 22:**682–685, 2001
16. Horstmann GA, Van Eck AT: Gamma knife model C with the automatic positioning system and its impact on the treatment of vestibular schwannomas. **J Neurosurg 97 (5 Suppl):** 450–455, 2002
17. Inoue HK: Low-dose radiosurgery for large vestibular schwannomas: long-term results of functional preservation. **J Neurosurg 102 Suppl:**111–113, 2005
18. Ishihara H, Saito K, Nishizaki T, Kajiwara K, Nomura S, Yoshikawa K, et al: CyberKnife radiosurgery for vestibular schwannoma. **Minim Invasive Neurosurg 47:**290–293, 2004
19. Kano H, Kondziolka D, Khan A, Flickinger JC, Lunsford LD: Predictors of hearing preservation after stereotactic radiosurgery for acoustic neuroma. Clinical article. **J Neurosurg 111:**863–873, 2009
20. Kapoor S, Batra S, Carson K, Shuck J, Kharkar S, Gandhi R, et al: Long-term outcomes of vestibular schwannomas treated with fractionated stereotactic radiotherapy: an institutional experience. **Int J Radiat Oncol Biol Phys 81:**647–653, 2011
21. Karpinos M, Teh BS, Zeck O, Carpenter LS, Phan C, Mai WY, et al: Treatment of acoustic neuroma: stereotactic radiosurgery vs. microsurgery. **Int J Radiat Oncol Biol Phys 54:** 1410–1421, 2002
22. Kentala E, Pyykkö I: Clinical picture of vestibular schwannoma. **Auris Nasus Larynx 28:**15–22, 2001
23. Kondziolka D: Editorial. Vestibular schwannomas. **J Neurosurg 116:**703–705, 2012
24. Kondziolka D, Lunsford LD, Flickinger JC: Acoustic neuroma radiosurgery. Origins, contemporary use and future expectations. **Neurochirurgie 50:**427–435, 2004
25. Kondziolka D, Lunsford LD, Flickinger JC: Gamma knife radiosurgery for vestibular schwannomas. **Neurosurg Clin N Am 11:**651–658, 2000
26. Kondziolka D, Lunsford LD, McLaughlin MR, Flickinger JC: Long-term outcomes after radiosurgery for acoustic neuromas. **N Engl J Med 339:**1426–1433, 1998
27. Kondziolka D, Nathoo N, Flickinger JC, Niranjan A, Maitz AH, Lunsford LD: Long-term results after radiosurgery for benign intracranial tumors. **Neurosurgery 53:**815–822, 2003
28. Leksell L: A note on the treatment of acoustic tumours. **Acta Chir Scand 137:**763–765, 1971
29. Linskey ME: Stereotactic radiosurgery versus stereotactic radiotherapy for patients with vestibular schwannoma: a Leksell Gamma Knife Society 2000 debate. **J Neurosurg 93 (Suppl 3):**90–95, 2000
30. Linskey ME, Johnstone PA: Radiation tolerance of normal temporal bone structures: implications for gamma knife stereotactic radiosurgery. **Int J Radiat Oncol Biol Phys 57:**196–200, 2003
31. Linskey ME, Lunsford LD, Flickinger JC: Tumor control after stereotactic radiosurgery in neurofibromatosis patients with bilateral acoustic tumors. **Neurosurgery 31:**829–839, 1992
32. Lobato-Polo J, Kondziolka D, Zorro O, Kano H, Flickinger JC, Lunsford LD: Gamma knife radiosurgery in younger patients with vestibular schwannomas. **Neurosurgery 65:**294–301, 2009
33. Lunsford LD, Niranjan A, Flickinger JC, Maitz A, Kondziolka D: Radiosurgery of vestibular schwannomas: summary of experience in 829 cases. **J Neurosurg 102 Suppl:**195–199, 2005
34. Martin TP, Senthil L, Chavda SV, Walsh R, Irving RM: A protocol for the conservative management of vestibular schwannomas. **Otol Neurotol 30:**381–385, 2009
35. Meijer OW, Vandertop WP, Baayen JC, Slotman BJ: Single-fraction vs. fractionated linac-based stereotactic radiosurgery for vestibular schwannoma: a single-institution study. **Int J Radiat Oncol Biol Phys 56:**1390–1396, 2003
36. Meijer OW, Wolbers JG, Baayen JC, Slotman BJ: Fractionated stereotactic radiation therapy and single high-dose radiosurgery for acoustic neuroma: early results of a prospective clinical study. **Int J Radiat Oncol Biol Phys 46:**45–49, 2000
37. Myrseth E, Møller P, Pedersen PH, Lund-Johansen M: Vestibular schwannoma: surgery or gamma knife radiosurgery? A prospective, nonrandomized study. **Neurosurgery 64:**654–663, 2009
38. Myrseth E, Møller P, Pedersen PH, Vassbotn FS, Wentzel-Larsen T, Lund-Johansen M: Vestibular schwannomas: clinical results and quality of life after microsurgery or gamma knife radiosurgery. **Neurosurgery 56:**927–935, 2005
39. Niranjan A, Kondziolka D, Lunsford LD: Neoplastic transformation after radiosurgery or radiotherapy: risk and realities. **Otolaryngol Clin North Am 42:**717–729, 2009
40. Niranjan A, Mathieu D, Flickinger JC, Kondziolka D, Lunsford LD: Hearing preservation after intracanalicular vestibular schwannoma radiosurgery. **Neurosurgery 63:**1054–1063, 2008

41. Norén G: Long-term complications following gamma knife radiosurgery of vestibular schwannomas. **Stereotact Funct Neurosurg 70 (Suppl 1):**65–73, 1998
42. Pennings RJ, Morris DP, Clarke L, Allen S, Walling S, Bance ML: Natural history of hearing deterioration in intracanalicular vestibular schwannoma. **Neurosurgery 68:**68–77, 2011
43. Petit JH, Hudes RS, Chen TT, Eisenberg HM, Simard JM, Chin LS: Reduced-dose radiosurgery for vestibular schwannomas. **Neurosurgery 49:**1299–1307, 2001
44. Poen JC, Golby AJ, Forster KM, Martin DP, Chinn DM, Hancock SL, et al: Fractionated stereotactic radiosurgery and preservation of hearing in patients with vestibular schwannoma: a preliminary report. **Neurosurgery 45:**1299–1307, 1999
45. Pollock BE, Driscoll CL, Foote RL, Link MJ, Gorman DA, Bauch CD, et al: Patient outcomes after vestibular schwannoma management: a prospective comparison of microsurgical resection and stereotactic radiosurgery. **Neurosurgery 59:** 77–85, 2006
46. Pollock BE, Lunsford LD, Kondziolka D, Flickinger JC, Bissonette DJ, Kelsey SF, et al: Outcome analysis of acoustic neuroma management: a comparison of microsurgery and stereotactic radiosurgery. **Neurosurgery 36:**215–229, 1995
47. Rasmussen R, Claesson M, Stangerup S, Roed H, Christensen IJ, Caye-Thomasen P, et al: Fractionated stereotactic radiotherapy of vestibular schwannomas accelerates hearing loss. **Int J Radiat Oncol Biol Phys** [epub ahead of print], 2012
48. Raut VV, Walsh RM, Bath AP, Bance ML, Guha A, Tator CH, et al: Conservative management of vestibular schwannomas—second review of a prospective longitudinal study. **Clin Otolaryngol Allied Sci 29:**505–514, 2004
49. Régis J, Carron R, Park MC, Soumare O, Delsanti C, Thomassin JM, et al: Wait-and-see strategy compared with proactive Gamma Knife surgery in patients with intracanalicular vestibular schwannomas. Clinical article. **J Neurosurg 113 Suppl:**105–111, 2010
50. Régis J, Pellet W, Delsanti C, Dufour H, Roche PH, Thomassin JM, et al: Functional outcome after gamma knife surgery or microsurgery for vestibular schwannomas. **J Neurosurg 97:** 1091–1100, 2002
51. Rowe J, Grainger A, Walton L, Silcocks P, Radatz M, Kemeny A: Risk of malignancy after gamma knife stereotactic radiosurgery. **Neurosurgery 60:**60–66, 2007
52. Sakamoto T, Shirato H, Takeichi N, Aoyama H, Fukuda S, Miyasaka K: Annual rate of hearing loss falls after fractionated stereotactic irradiation for vestibular schwannoma. **Radiother Oncol 60:**45–48, 2001
53. Sawamura Y, Shirato H, Sakamoto T, Aoyama H, Suzuki K, Onimaru R, et al: Management of vestibular schwannoma by fractionated stereotactic radiotherapy and associated cerebrospinal fluid malabsorption. **J Neurosurg 99:**685–692, 2003
54. Shirato H, Sakamoto T, Sawamura Y, Kagei K, Isu T, Kato T, et al: Comparison between observation policy and fractionated stereotactic radiotherapy (SRT) as an initial management for vestibular schwannoma. **Int J Radiat Oncol Biol Phys 44:**545–550, 1999
55. Shirato H, Sakamoto T, Takeichi N, Aoyama H, Suzuki K, Kagei K, et al: Fractionated stereotactic radiotherapy for vestibular schwannoma (VS): comparison between cystic-type and solid-type VS. **Int J Radiat Oncol Biol Phys 48:**1395–1401, 2000
56. Spiegelmann R, Lidar Z, Gofman J, Alezra D, Hadani M, Pfeffer R: Linear accelerator radiosurgery for vestibular schwannoma. **J Neurosurg 94:**7–13, 2001
57. Sughrue ME, Yang I, Aranda D, Lobo K, Pitts LH, Cheung SW, et al: The natural history of untreated sporadic vestibular schwannomas: a comprehensive review of hearing outcomes. Clinical article. **J Neurosurg 112:**163–167, 2010
58. Sugihara S, Kinoshita T, Matsusue E, Fujii S, Ogawa T: Multicystic acoustic schwannoma with intratumoral hemorrhage: a report of two cases. **Magn Reson Med Sci 3:**101–104, 2004
59. Suh JH, Barnett GH, Sohn JW, Kupelian PA, Cohen BH: Results of linear accelerator-based stereotactic radiosurgery for recurrent and newly diagnosed acoustic neuromas. **Int J Cancer 90:**145–151, 2000
60. Szumacher E, Schwartz ML, Tsao M, Jaywant S, Franssen E, Wong CS, et al: Fractionated stereotactic radiotherapy for the treatment of vestibular schwannomas: combined experience of the Toronto-Sunnybrook Regional Cancer Centre and the Princess Margaret Hospital. **Int J Radiat Oncol Biol Phys 53:**987–991, 2002
61. Tamura M, Carron R, Yomo S, Arkha Y, Muraciolle X, Porcheron D, et al: Hearing preservation after gamma knife radiosurgery for vestibular schwannomas presenting with high-level hearing. **Neurosurgery 64:**289–296, 2009
62. Tanbouzi Husseini S, Piccirillo E, Taibah A, Paties CT, Rizzoli R, Sanna M: Malignancy in vestibular schwannoma after stereotactic radiotherapy: a case report and review of the literature. **Laryngoscope 121:**923–928, 2011
63. Varughese JK, Breivik CN, Wentzel-Larsen T, Lund-Johansen M: Growth of untreated vestibular schwannoma: a prospective study. Clinical article. **J Neurosurg 116:**706–712, 2012
64. Walsh RM, Bath AP, Bance ML, Keller A, Tator CH, Rutka JA: The role of conservative management of vestibular schwannomas. **Clin Otolaryngol Allied Sci 25:**28–39, 2000
65. Yanamadala V, Williamson R, Fusco D, Eschbacher J, Weisskopf P, Porter R: Malignant transformation of a vestibular schwannoma after gamma knife radiosurgery: case report and review of the literature. **World Neurosurg** [epub ahead of print], 2012
66. Yang I, Sughrue ME, Han SJ, Aranda D, Pitts LH, Cheung SW, et al: A comprehensive analysis of hearing preservation after radiosurgery for vestibular schwannoma. Clinical article. **J Neurosurg 112:**851–859, 2010

Manuscript submitted May 15, 2012.
Accepted June 19, 2012.
Please include this information when citing this paper: DOI: 10.3171/2012.6.FOCUS12192.
Address correspondence to: Douglas Kondziolka, M.D., Department of Neurological Surgery, University of Pittsburgh, 200 Lothrop Street, Suite B-400, Pittsburgh, Pennsylvania 15213. email: kondziolkads@upmc.edu.