Stereotactic Radiosurgery for Arteriovenous Malformations Located in Deep Critical Regions

Gábor Nagy, MD, PhD*‡
Ottó Major, MD, PhD‡
Jeremy G. Rowe, MA, DM*
Matthias W.R. Radatz, MD*
Timothy J. Hodgson, FRCR§
Stuart C. Coley, MD§
Andras A. Kemeny, FRCS, MD*

*The National Centre for Stereotactic Radiosurgery, Royal Hallamshire Hospital, Sheffield, United Kingdom; ‡National Institute of Neurosciences, Budapest, Hungary; §Department of Radiology, Royal Hallamshire Hospital, Sheffield, United Kingdom

Correspondence:
Andras A. Kemeny, FRCS, MD,
The National Centre for Stereotactic Radiosurgery,
Royal Hallamshire Hospital,
Glossop Road,
Sheffield, S10 2JF, United Kingdom.
E-mail: aakemeny@gmail.com

Received, July 18, 2011.
Accepted, November 30, 2011.
Published Online, December 19, 2011.

Copyright © 2011 by the Congress of Neurological Surgeons

BACKGROUND: Radiosurgery is widely used to treat deep eloquent arteriovenous malformations (AVMs).

OBJECTIVE: To evaluate how anatomic location, AVM size, and treatment parameters define outcome.

METHODS: Retrospective analysis of 356 thalamic/basal ganglia and 160 brainstem AVMs treated with gamma knife radiosurgery.

RESULTS: Median volume was 2 cm^3 (range, 0.02-50) for supratentorial and 0.5 cm^3 (range, 0.01-40) for brainstem AVMs; the marginal treatment doses were 17.5 to 25 Gy. After single treatment, obliteration was achieved in 65% of the brainstem, in 69% of the supratentorial, and 40% of the peritectal AVMs. Obliteration of lesions <4 cm^3 was better in the brainstem (70%) and in the supratentorium (80%), but not in the peritectal region (40%). Complications were rare (6%–15%) and mild ($\leq$modified Rankin scale [MRS] 2). Rebleed rate increased with size, but was not higher than before treatment. AVMs >4 cm^3 in the brainstem were treated with unacceptable morbidity and low cure rate. Obliteration of large supratentorial AVMs was 65% to 47% with more complications $\geq$MRS3. Repeat radiosurgical treatment led to obliteration in 66% of the cases with minor morbidity.

CONCLUSION: Deep eloquent AVMs <4 cm^3 can be treated safely and effectively with radiosurgery. Obliteration of peritectal AVMs is significantly lower after a single treatment. However, morbidity is low, and repeat treatment leads to good obliteration. Radiosurgical treatment >4 cm^3 in the brainstem is not recommended. Supratentorial deep AVMs >8 cm^3 can be treated with radiosurgery with higher risk and lower obliteration rate. However, these lesions are difficult to treat with other treatment modalities, and a 50% success rate makes radiosurgery a good alternative even in this challenging group.

KEY WORDS: Arteriovenous malformation, Brainstem, Radiosurgery, Thalamus/basal ganglia

Neurosurgery 70:1458–1471, 2012 DOI: 10.1227/NEU.0b013e318246a4d0 www.neurosurgery-online.com

Deep highly eloquent arteriovenous malformations (AVMs), located either in the thalamus/basal ganglia or in the brainstem, behave more aggressively than other AVMs. Deep location has been found to be an independent risk factor for hemorrhage,[1-7] and the majority of these lesions present with hemorrhage, leaving 62% to 85.5% of the surviving patients with permanent neurological deficits.[8-10] The natural history is therefore dire: conservatively managed thalamic/basal ganglia AVMs have a 43% 10-year mortality[8] and brainstem AVMs have a similarly bad prognosis.[11,12]

ABBREVIATIONS: AVM, arteriovenous malformations; **MRS,** modified Rankin scale

Because of their deep critical location and multiple small feeders, these lesions are often unattractive for both surgical and endovascular treatments, and therefore referred for radiosurgery. Radiosurgery induces progressive hyalinization, proliferation of myofibroblasts, and subsequent thrombo-obliteration, leading to complete radiological obliteration in 50% to 80% of the AVMs within 2 to 4 years with low morbidity,[13-15] depending on size and location.[16] Being a minimally invasive and low-risk treatment, it serves a real management alternative for these challenging lesions. However, given that the annual rebleed

CME

SANS LifeLong Learning and NEUROSURGERY offer CME for subscribers that complete questions about featured articles. Questions are located on the SANS website (http://sans.cns.org/). Please read the featured article and then log into SANS for this educational offering.

Copyright © Congress of Neurological Surgeons. Unauthorized reproduction of this article is prohibited.

risk after the presenting hemorrhage may reach 34% initially,[4] the latency period between radiosurgery and obliteration carries significant additional risk of morbidity and mortality, prompting an earlier definitive management by some critics of radiosurgery.[17]

Most of the published large radiosurgical series include only few deep AVMs and do not analyze them separately,[14,18-20] and the few articles published specifically focusing on this AVM group are based on a relatively low number of patients (less than a hundred), allowing only limited analysis.[8,10,21-27] Moreover, in the widely used grading systems,[16,28] for example, there is no distinction between the outcomes of brainstem and thalamic/basal ganglia lesions. Can we consider these 2 groups similar? Do they constitute a homogenous population or do particular anatomic subgroups behave differently? Answering these questions requires large patient populations; therefore, aiming to address these issues we analyzed 356 patients with AVM in the thalamic/basal ganglia and 160 in the brainstem treated in Sheffield during the past 20 years. We wanted to know how anatomic location and size affect outcome and to find the optimal technical parameters and the limitations of radiosurgery.

PATIENTS AND METHODS

Patient Population and Anatomic Considerations

Since 1986, over 10 000 patients have been treated in Sheffield, with about 4350 of them having AVMs. Of these, we selected for retrospective analysis those treated between 1985 and 2008, with 356 deep supratentorial (thalamus/basal ganglia) lesions (420 treatments) and 160 brainstem lesions (197 treatments). There was a slight male preponderance (55%). We defined 4 groups for analysis: thalamic/basal ganglia (located in the thalamus, basal ganglia, internal capsule, third ventricle, the medial periventricular region of the lateral ventricles, and splenium), "peritectal diencephalon" (supratentorial lesions close to the quadrigeminal cistern including the medial pulvinar and pineal region, superior to basal veins), midbrain/tectal, and pontine/medullar (including the middle cerebellar peduncle, anterior to the plane of fourth ventricle) location (Table 1, Figure 1). 26% of the midbrain/tectal lesions were cisternal, 42% were partially parenchymal (superficial), and 32% were deep parenchymal. Thirty-nine percent of the lesions located in the pons/medulla were cisternal, 30.5% were partially parenchymal, and 30.5% were deep parenchymal. The median lesion volumes (range) were 2.01 (0.018-49.74), 1.32 (0.028-13), 0.53 (0.009-18.3), and 0.47 cm^3 (0.0165-39) in the thalamic/basal ganglia, peritectal, midbrain, and pontine/medullar groups, respectively.

Previous surgery was performed (mainly restricted to clot evacuation) on 7.8%, 3.8%, 3.8%, and 7%, and embolization attempt on 8.1%, 5.7%, 5.1%, and 1.4% of the thalamic/basal ganglia, peritectal, midbrain, and pontine/medullar patients, respectively.

Treatment Details

Focus (KULA based software modified in-house) was used for dose planning before 1994, and GammaPlan (Elekta AB, Stockholm, Sweden) thereafter. Treatment was initially performed with an early gamma knife model (RBS 5000, Nucletec, Geneva, Switzerland), which was replaced by Gamma Knife Model C (Elekta AB, Stockholm, Sweden) in 2001. Stereotactic catheter angiography was performed for all treatments. Magnetic resonance imaging (MRI) was gradually introduced for treatment planning of AVMs after 1996, and since 2001 no treatment has been planned without axial imaging. Our standard marginal dose is 25 Gy for AVMs, and what we used initially irrespective of size and location. More recently, we have been reducing doses for the eloquently placed lesions (as the material in this article), for large lesions, for patients younger than 16 years, and for patients previously undergoing radiotherapy, but rarely below 17.5 Gy.[20] Detailed treatment parameters are given in the Results section.

TABLE 1. Localization and Presentation of Deep Eloquent Arteriovenous Malformations Treated Between 1985 and 2008 With Gamma Knife Radiosurgery in Sheffield

	No.	%
Location		
Thalamic/basal ganglia	303	
Thalamic	161	53
Basal ganglia	56	18.5
Capsular	20	6.5
Lateral ventricle	21	7
Third ventricle	9	3
Splenium	15	5
Hypothalamus	6	2
Undefined	25	8
Peritectal diencephalon	53	
Pineal	21	40
Medial pulvinar	32	60
Brainstem	160	
Midbrain	84	52.5
Other brainstem	76	47.5
Cerebellopontine angle	42	26.25
Pontine	24	15
Fourth ventricle	7	4.25
Pontomedullar	3	2
Presentation		
Thalamic/basal ganglia		
Hemorrhage	232	81
Seizures	16	5
Focal neurological deficit	26	9
Headaches	3	1
Incidental	12	4
Peritectal diencephalon		
Hemorrhage	43	81
Focal neurological deficit	4	7.5
Headaches	1	2
Incidental	5	9.5
Midbrain		
Hemorrhage	68	87
Focal neurological deficit	7	9
Headaches	1	1.3
Incidental	2	2.7
Pons/medulla		
Hemorrhage	55	78.5
Focal neurological deficit	14	20
Trigeminal neuralgia	7	10
Incidental	1	1.5

Follow-Up and Statistical Analysis

Our current protocol is to perform first an MRI and Magnetic Resonance Digital Substraction Angiography 2 years after treatment.[29,30]

Copyright © Congress of Neurological Surgeons. Unauthorized reproduction of this article is prohibited.

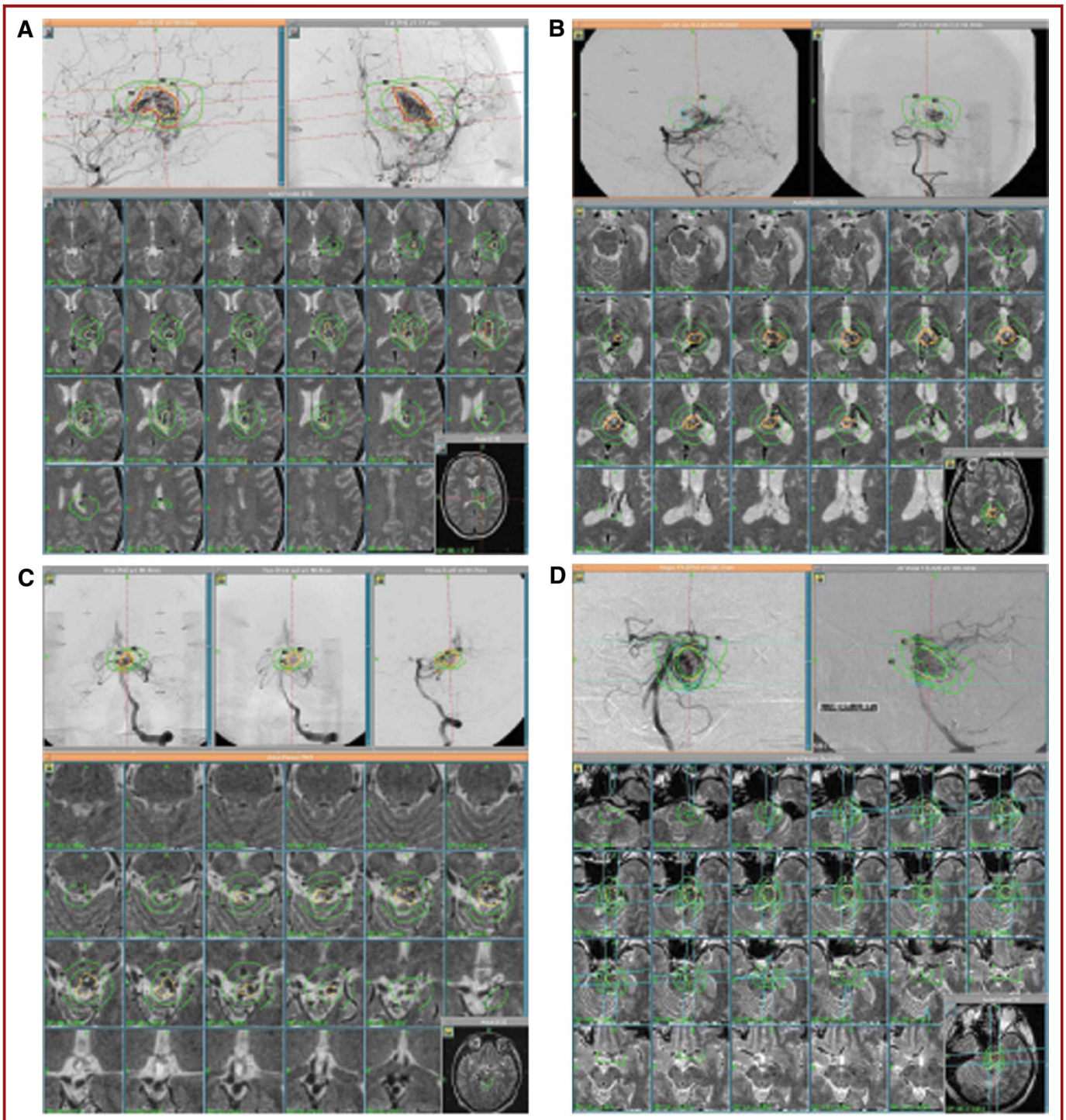

FIGURE 1. *Examples of anatomic subgroups of deep eloquent AVMs with their treatment plan. Thalamus/basal ganglia (A), peritectal diencephalon (B), midbrain/tectum (C), and pons/medulla (D).*

Copyright © Congress of Neurological Surgeons. Unauthorized reproduction of this article is prohibited.

If these show no residual, catheter angiography is performed at 2 years. If persisting nidus is demonstrated on MRI scanning, catheter angiography is performed 3 to 4 years after treatment, and patients with persisting nidus are scheduled for further treatment at approximately 4 years. We also recommend regular clinical follow-up every 6 months until obliteration in uncomplicated cases. Follow-up imaging is reviewed by our multidisciplinary team consisting of expert radiosurgeons and neuroradiologists and recorded in the clinical notes and our prospective radiosurgical database. All follow-up information was obtained from clinical notes and our database. Of the 356 patients treated with thalamic/basal ganglia (including peritectal) AVMs, 321 had available follow-up information, 267 with full radiological follow-up. Of the 160 patients treated with brainstem lesions, 140 had follow-up information, 108 having full radiological follow-up.

Annual hemorrhage rates were calculated by dividing the number of hemorrhages with the number of observation years. Posttreatment hemorrhage rates for nonobliterated AVMs were counted with the follow-up years from the treatment to the last available clinical information. For obliterated AVMs, we used an average posttreatment year estimated from the last known nonobliterated state and the first detection of obliteration with the assumption that AVMs do not fully obliterate within the first year after treatment (eg, if an AVM was shown to be obliterated 2 years after treatment, we calculated with 1.5 years, and if the 2-year follow-up image showed residual nidus, but the 4-year angiogram demonstrated obliteration, we calculated with 3 years).

We grade obliteration response with the following grades: 0, no detectable changes; 1, only minimal changes; 2, partial response with substantial reduction in nidus size ("near total" obliteration – persisting early draining vein with or without hardly detectable nidus – is graded as 2+); 3, some residual abnormal vasculature without early draining vein; and 4, complete radiological obliteration. For simplicity, we use 3 categories in this study: Gr0-1 (less than 25% of nidus reduction), Gr2 (substantial reduction in nidus size, but early draining vein persists), and Gr3-4 (safe), as described.[20]

For statistical analysis of size dependence we defined discrete size intervals as the following: the smallest lesions were no larger than 1 cm in diameter (volume, 0.52 cm^3), followed by the 1- to 2-cm (0.52-4 cm^3), and 2- to 2.5-cm (4-8 cm^3) size groups, and the largest size group included all lesions larger than 2.5 cm (8 cm^3). The only exception was the peritectal group, where it seemed reasonable to pool the second and third size ranges into a single 1- to 2.5-cm range (0.52-8 cm^3). Of note, large numbers only allowed detailed analysis of size dependence in the thalamic/basal ganglia group. We used Mann-Whitney *U*, Fisher exact/ χ^2 test, and 2-tailed Spearman correlation for statistical analysis, and 95% confidence intervals are given, as appropriate.

RESULTS

Presentation, Pretreatment Hemorrhages, and Morbidity

The majority of patients (at least 80%) presented with hemorrhages (Table 1) with a median age of presentation (range) of 27 (4-69), 30 (3-72), 40 (3-67), and 37.5 years (0.15-67) in the thalamic/basal ganglia, peritectal, midbrain, and pontine/medullar groups, respectively. Thalamic/basal ganglia lesions presented and bled significantly earlier than both brainstem groups ($P < .001$).

The percentage of hemorrhagic presentation was higher in smaller lesions (Table 2). The annual first pretreatment hemorrhage rates were between 2% and 3% with a tendency of higher rates in smaller thalamic/basal ganglia lesions in comparison with other locations and to larger lesions in the thalamus/basal ganglia (Table 3, Figure 2). The median age at treatment was 32 (5-72), 36 (9-73), 40 (11-67), and 43 years (5-70) in the thalamic/basal ganglia, peritectal, midbrain, and pontine/medullar groups, respectively. The mean time between presentation and treatment was 4 years in the supratentorial group and 2 years in the brainstem group. This delay allowed us to calculate pretreatment rebleed rates, which were higher in all groups and increased with size in the thalamic/basal ganglia group (Table 3, Figure 2).

TABLE 2. Percentage of Patients With Hemorrhage Before Treatment in Different Subgroups[a]

	<0.52 cm^3	0.52 to 4 cm^3	4 to 8 cm^3	>8 cm^3
Midbrain	95	92	70	50
Peritectal	83	79.5		50
Pons/medulla	90.5	78	67	40
Thal/BG	96	87.5	74	69

[a]Values are percentages. Thal/BG, thalamus/basal ganglia.

At the time of the treatment, 40% to 60% of patients had neurological deficits (measured by the modified Rankin scale [MRS][31]), mainly as a result of previous hemorrhages, less frequently due to focal neurological deficit without hemorrhages, or as a result of previous intervention, with the rate and severity depending on location (Figure 3).

Obliteration

Obliteration rates in the midbrain and in the peritectal region were approximately half of the obliteration rates found in the pons/medulla and in the thalamus/basal ganglia 2 years after the treatment. Conversely, hardly any response (Gr0-1) was seen in more midbrain and peritectal lesions than in the pons/medulla and thalamus/basal ganglia (Figure 4, left panel). At 4 years, 41% of the midbrain, 42.5% of the peritectal, 65% of the pontine/medullar, and 69% of the thalamic/basal ganglia lesions were obliterated, while the proportion of those lesions that hardly responded remained high in the midbrain (19.6%) and in the peritectal group (15%), but low in the pons/medulla (6%) and thalamus/basal ganglia (8%). The difference in obliteration rates at 4 years was significant (nonparametric analysis of variance, $P < .001$; posttest showed significant difference between thalamic/basal ganglia and midbrain, $P < .01$) (Figure 4, right).

Correlation was also found between size and obliteration: a clear tendency to lower obliteration rates is demonstrated in larger lesions in all anatomic locations, which is significant in the thalamic/basal ganglia group ($P < .001$) (Table 4). Of note, none of the few brainstem and peritectal lesions larger than 8 cm^3 were obliterated. The spatial relation to parenchyma and cisterna in the brainstem did not correlate to obliteration rates (not shown).

Copyright © Congress of Neurological Surgeons. Unauthorized reproduction of this article is prohibited.

TABLE 3. Annual Hemorrhage Rates Before and After the First Radiosurgical Treatment[a]

	1st Ever Before Treatment	Rebleed Before Treatment	Posttreatment
Thal/BG			
<0.52 cm³	3.05%, CI: 2.35-3.75 (72 bleeds in 2354 y)	7.9%, CI: 2.55-13.3 (8 bleeds in 101 y)	1.3%, CI: 0-3.13 (2 bleeds in 153 y)
0.52 to 4 cm³	3.05%, CI: 2.4-3.7 (89 bleeds in 2923 y)	10%, CI: 6.5-13.5 (26 bleeds in 259 y)	2.89%, CI: 1.02-4.77 (9 bleeds in 311 y)
4 to 8 cm³	2.55%, CI: 1.-3.4 (33 bleeds in 1287 y)	9.25%, CI: 5.85-12.65 (26 bleeds in 281 y)	5.95%, CI: 2.51-9.39 (11 bleeds in 185 y)
>8 cm³	2.2%, CI: 1.45-2.95 (32 bleeds in 1459 y)	16.25%, CI: 11.7-20.9 (41 bleeds in 252 y)	9.2%, CI: 5.88-12.55 (27 bleeds in 293 y)
Peritectal	2.3%, CI: 1.6-3.0 (43 bleeds in 1845 y)	5.1%, CI: 1.1-9.2 (6 bleeds in 117 y)	0.98%, CI: 0-2.34 (2 bleeds in 204 y)
Midbrain	2.2%, CI: 1.7-2.7 (68 bleeds in 3061 y)	11%, CI: 5.7-16.3 (15 bleeds in 136 y)	3.6%, CI: 1.5-5.71 (11 bleeds in 305 y)
Pons/medulla	2%, CI: 1.5-2.5 (55 bleeds in 2716 y)	6.5%, CI: 2.1-10.8 (8 bleeds in 124 y)	2.28%, CI: 0.29-4.28 (5 bleeds in 219 y)

[a]Thal/BG, thalamus/basal ganglia; CI, confidence interval; y, patient years.

Recurrent nidi were demonstrated in 2 of the cases previously considered obliterated based on catheter angiography performed at 4 years, 10 (a thalamic lesion), and 12 years (a pineal region lesion) after the treatment. The pineal lesion was treated and cured with a second radiosurgery, and the thalamic lesion was embolized.

Adverse Radiation Effects

Adverse radiation effects typically developed within the first 2 years (except in 4 patients), not earlier than 6 months after treatment. Rate and severity were size and location dependent (Table 5). No side effects greater than MRS1 were observed in the smallest AVM groups, but treatment of lesions larger than 8 cm³ resulted in high complication rates (about 50% permanent morbidity in the brainstem and peritectal lesions, and 35% in the thalamic/basal ganglia lesions, with11% >MRS2). The only radiation-induced death occurred to a patient with a 1.2 cm³ pontomedullar lesion treated before MRI was introduced for planning: the patient developed tetraparesis caused by radiation-induced edema and subsequently died of a pulmonary embolism 1 year after treatment.

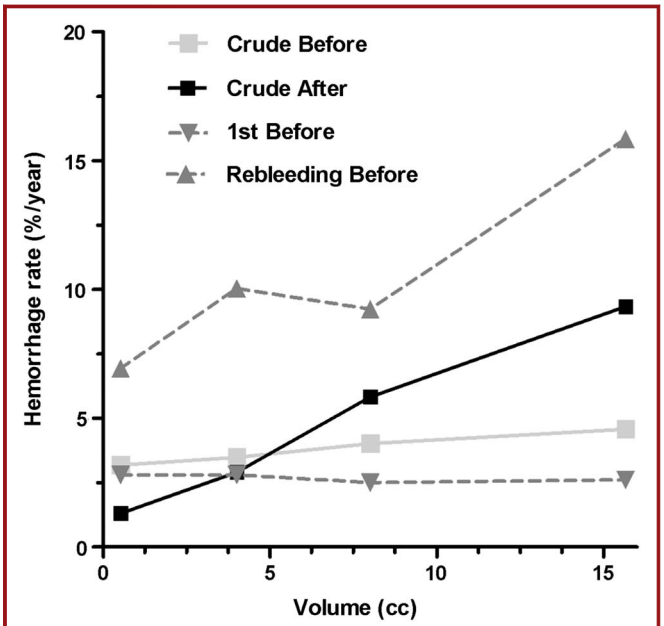

FIGURE 2. *Crude annual hemorrhage rates before (light gray), and after (black) radiosurgery, and pretreatment rates of first ever and rebleed rates (gray dotted lines) in the thalamic/basal ganglia group.*

Hemorrhages After Treatment

Posttreatment hemorrhage rates were lower than rebleed rates in all groups (Table 3, Figure 2). It has previously been estimated that 726 patient years would be required to detect significance in 1%/year change in hemorrhage rate[32]; therefore, significant decrease was only detected in the largest ruptured thalamic/basal ganglia group (odds ratio: 0.55, 95% confidence interval: 0.32-0.92, $P < .05$). None of the rare unruptured AVMs smaller than 4 cm³ bled after the treatment, and bleeding rate is not higher than the annual pretreatment first ever bleed rate (2.55%) in unruptured

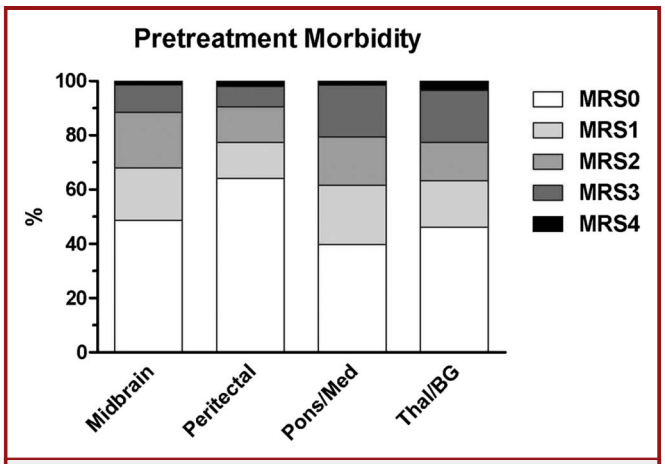

FIGURE 3. *Permanent neurological deficits at the time of treatment in different anatomic subgroups of arteriovenous malformations. The most neurologically intact patients are found in the peritectal group (64%) and the less in the pons/medulla group (40%). The proportion of more severe deficits (MRS3-4) is higher in the pons/medulla and the thalamic/basal ganglia group (20%) in comparison with midbrain and peritectal lesions (10%). MRS, modified Rankin scale.*

Copyright © Congress of Neurological Surgeons. Unauthorized reproduction of this article is prohibited.

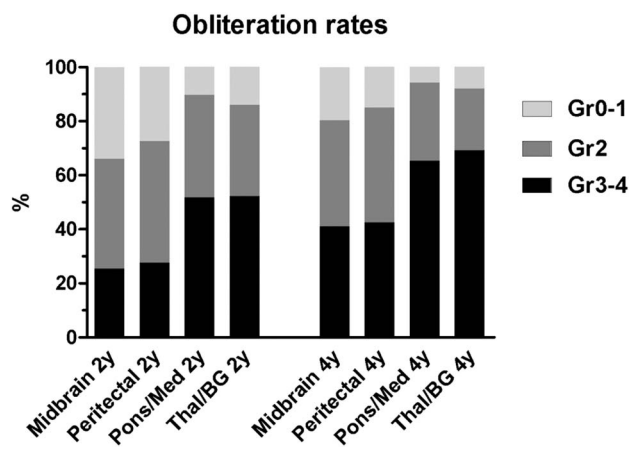

FIGURE 4. *Obliteration rates of arteriovenous malformations in different anatomic subgroups. The left panel shows obliteration at 2 years (midbrain: n = 71; peritectal: n = 40; pontine/medullar: n = 58; thalamic/basal ganglia: n = 243), and the right panel shows obliteration at 4 years (midbrain: n = 56; peritectal: n = 40; pontine/medullar: n = 52; thalamic/basal ganglia: n = 227) after radiosurgery. Gr0-1 (light gray): no or hardly any response, Gr2 (gray): partial response, Gr3-4 (black): obliterated, no early draining vein is visible.*

thalamic/basal ganglia lesions with 4 to 8 cm^3 volume. The only group where annual posttreatment hemorrhage rate was higher than the expected first ever bleed rate was unruptured thalamic/basal ganglia lesions >8 cm^3 (8.2% vs 2.2%).

Deaths and permanent neurological deficits caused by posttreatment hemorrhages were rare in most groups, except in the largest thalamic/basal ganglia group (44% of those patients who bled after treatment died) (Table 6). Of the 12 patients who died of a hemorrhage after treatment in this group, 6 died within 3 years after either the first or the second treatment; these deaths were "unavoidable." However, the other 6 deaths occurred many years later in patients who either refused subsequent treatment or were not considered suitable for a second session (mainly according to our earlier, more conservative approach) and therefore might have been avoided with a second treatment.

Four patients with previous evidence of complete obliteration by catheter angiography (all with thalamic/basal ganglia lesions) experienced hemorrhage 3 to 8 years after demonstration of obliteration at the site of their lesions, without evidence of recurrent nidus. One of these patients died, and the disappearance of the nidus was confirmed by autopsy.

TABLE 4. Obliteration of Arteriovenous Malformations in Distinct Locations with Different Size[a,b]

	<0.52 cm^3	0.52 to 4 cm^3	4 to 8 cm^3	>8 cm^3
Midbrain	53.6 (28)	38.9 (18)	16.7 (6)	0 (4)
Peritectal	70 (10)	34.5 (29)		0 (1)
Pons/medulla	70 (30)	68.8 (16)	67 (3)	0 (3)
Thal/BG	88.1 (59)	72.1 (86)	64.5 (31)	47.1 (51)

[a]Thal/BG, thalamus/basal ganglia.
[b]Values are percentages (number of treated lesions).

TABLE 5. The Rate of Adverse Radiation Effects in Different Size and Anatomic Subgroups[a,b]

	<0.52 cm^3	0.52 to 4 cm^3	4 to 8 cm^3	>8 cm^3
Midbrain (n)	(35)	(24)	(9)	(4)
Temporary	0	8	0	25
MRS1	0	4	11	0
MRS2	0	4	33	0
MRS3	0	0	0	0
MRS4	0	0	0	0
Peritectal (n)	(11)	(32)		(1)
Temporary	0	0		0
MRS1	9	6		100
MRS2	0	3		0
MRS3	0	0		0
MRS4	0	0		0
Pons/medulla (n)	(36)	(22)	(2)	(5)
Temporary	0	4.5	0	0
MRS1	11	14.5	0	0
MRS2	0	0	50	40
MRS3	0	0	50	20
MRS4	0	0	0	0
Thal/BG (n)	(66)	(94)	(43)	(55)
Temporary	1.5	1	5	5.5
MRS1	6	6	14	13
MRS2	0	4	9	11
MRS3	0	0	4.5	9
MRS4	0	0	0	2

[a]Thal/BG, thalamus/basal ganglia.
[b]Permanent deficits are indicated as Gr1-4 decline in modified Rankin scale (MRS).[31]

Outcomes After Single Radiosurgical Session

The outcome of radiosurgery depends on obliteration and permanent morbidity caused either by the treatment or posttreatment hemorrhages. We adapted a standardized outcome scale that uses 6 grades depending on obliteration and the severity of neurological deficit.[19] Figure 5 summarizes the outcomes in different subgroups after the first treatment. Clearly, location is one of the main predictors of outcome. Likewise, significant correlation between size and outcome grade is demonstrated ($P < .001$) in the thalamic/basal ganglia group. However, we found no correlation between age and outcome grade in any of the groups. Spetzler-Martin grade[28] and radiosurgery-based AVM scores[16] were found less useful for outcome prediction (not shown).

Further Treatments

Twenty-seven patients with midbrain lesion underwent a second radiosurgical treatment, 8 having follow-up angiogram at 4 years, demonstrating an 87.5% obliteration rate. None of the

Copyright © Congress of Neurological Surgeons. Unauthorized reproduction of this article is prohibited.

TABLE 6. Rates of Permanent Morbidity and Mortality Caused by Posttreatment Hemorrhages in Different Subgroups[a,b]

	<0.52 cm³	0.52 to 4 cm³	4 to 8 cm³	>8 cm³
Midbrain (n)	(35)	(24)	(9)	(4)
MRS1	0	0	11	0
MRS2	0	0	0	0
MRS3	0	0	0	0
MRS4	0	0	0	0
Mortality	0	4	11	0
Peritectal (n)	(11)	(32)		(1)
MRS1	0	0		0
MRS2	0	0		0
MRS3	0	0		0
MRS4	0	0		0
Mortality	0	3		0
Pons/medulla (n)	(36)	(22)	(2)	(5)
MRS1	0	0	0	20
MRS2	0	0	0	0
MRS3	0	0	0	0
MRS4	0	0	0	0
Mortality	3	0	0	20
Thal/BG (n)	(66)	(94)	(43)	(55)
MRS1	0	0	0	0
MRS2	0	0	2	2
MRS3	0	2	2	4
MRS4	0	0	0	0
Mortality	0	3	9	19

[a]Thal/BG, thalamus/basal ganglia.
[b]Morbidity is indicated as Gr1-4 decline in modified Rankin scale (MRS).[31]

patients treated with a second session experienced side effects. Thirteen patients with peritectal lesion were treated, 7 of the 9 lesions being obliterated (78%), with 10% experiencing a Gr1 permanent side effect. In the 8 patients treated with pontine/medullar lesions for the second time, no permanent side effects were seen, and 4 of the 6 lesions (67%) were obliterated. Thalamic/basal ganglia lesions were treated in 40 patients for the second time, with a 57% obliteration rate (12/21) and 8% radiation-induced permanent complication rate (Gr1 and 2, in 1-1 patients). The median time interval between the first and second treatment was 5 years (range, 2-17) in all groups except the pontine/medullar group (4.5 years; range, 4-6).

Two patients with midbrain (one was treated 2.5 years after the previous treatment), 1 patient with peritectal, 1 with pontomedullar, and 3 with thalamic/basal ganglia lesions were treated for the third time. Radiological end point is available for the patient with the pontomedullar lesion (obliterated, with MRS2 side effect), and 1 patient with a thalamic lesion (tiny persistent fistula remained, and the patient developed necrotic cyst).

Two thalamic/basal ganglia lesions underwent postradiosurgical embolization; one of them was partially embolized after a hemorrhage (this patient was left with dysphasia and hemiparesis after embolization attempt), and a tiny residual fistula was successfully treated in another case. Surgery was performed on 3 patients with

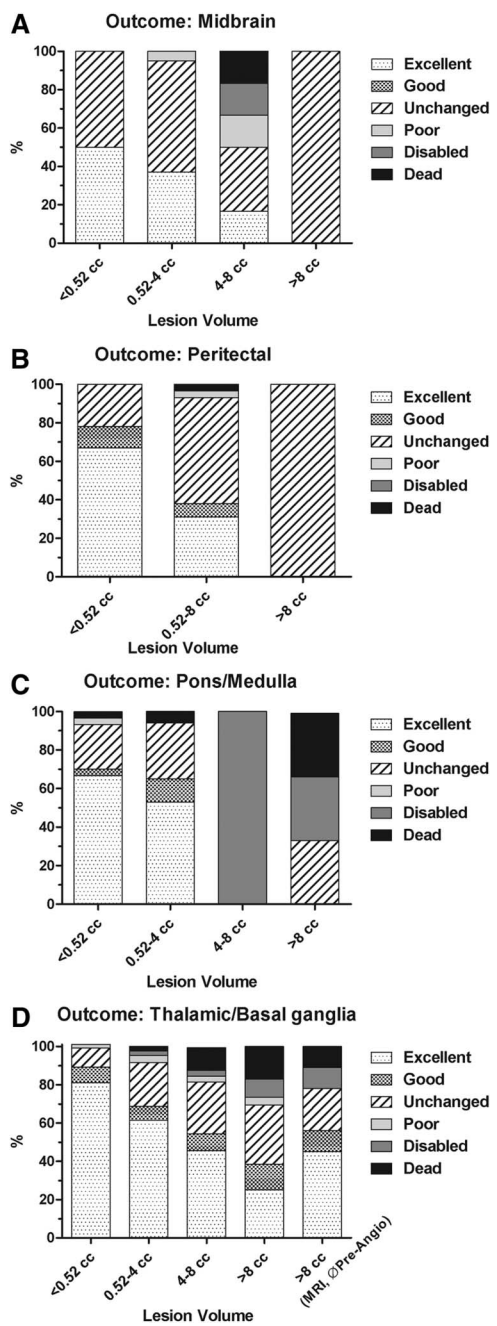

FIGURE 5. *Patient outcomes after the first radiosurgical treatment of arteriovenous malformations in the midbrain (A), peritectal diencephalon (B), pons/medulla (C), and thalamus/basal ganglia (D). Excellent: complete obliteration without permanent new neurological deficit. Good, complete obliteration with new permanent minor neurological deficit; Unchanged, incomplete obliteration without new permanent neurological deficit; Poor, incomplete obliteration, new permanent minor neurological deficit; Disabled, new permanent major neurological deficit that interferes with the patient's preoperative level of functioning, regardless of obliteration.*[19]

Copyright © Congress of Neurological Surgeons. Unauthorized reproduction of this article is prohibited.

thalamic/basal ganglia lesions after radiosurgery. One patient bled 1 day after radiosurgery, and surgical clot evacuation was performed without removing the AVM (the patient recovered without persisting deficits, and the lesion was obliterated 4 years after radiosurgery), 1 lesion was removed after the second postradiosurgical bleed at 2 years and was left with hemiparesis, and a 3 patient preferred surgery rather than a second radiosurgical session (after the complete removal of her posterior thalamic AVM, she was left with hemianopia and hemiparesis). None of the brainstem lesions underwent postradiosurgical embolization or surgery.

Treatment Parameters and Outcome

Treatment parameters were similar in the different anatomic subgroups (Table 7). Reflecting our intention at treatment, a clear tendency is apparent to "undertreat" larger lesions with lower radiation doses and smaller treatment volumes. No significant correlation is demonstrated between radiation dose within our standard dose range, treatment volume, and outcome. The only notable finding is that small midbrain lesions obliterated with higher rates (60% vs 40%) when our standard full marginal dose (25 Gy) was given.

Improving planning techniques did not change the overall outcome of radiosurgical treatment of small AVMs (except for the higher complication rates and the only radiation-induced death in the brainstem group with early treatment planning without MR imaging). However, there was a nonsignificant tendency of increased obliteration rate in those patients treated without MRI planning (44% vs 36%). Introduction of MRI improved obliteration slightly from 45% to 56% only in the largest thalamic/basal ganglia group without changing the rate of adverse radiation effects.

Prior embolization had rarely been attempted on small lesions, and only 15% of the largest thalamic/basal ganglia lesions had undergone previous partial embolization. Obliteration in this limited number of patients was poor, 29%, in contrast to 52% of nonembolized large lesions. Our limited experience (n = 9) with the most optimal treatment strategy for large thalamic/basal ganglia AVMs (addition of MRI to planning, and the lack of prior embolization) is shown in Figure 5D.

DISCUSSION

Hemorrhage and Morbidity Rates of Deep Eloquent AVMs

Deep and infratentorial location and deep venous drainage are widely accepted to be associated with higher annual AVM bleeding rates,[1-4,6,7,34] which was found in 5% to 8% of such previously unruptured AVMs.[4,7] Thus, it is not surprising that 70% to 90% of these AVMs present with hemorrhage, the rate being higher than the approximately 50% hemorrhagic presentation in unselected population.[8,9,23,34,35] Previous hemorrhage was also

TABLE 7. Treatment Parameters in Different Subgroups (Mean ± SD)[a]

	<0.52 cm³	0.52 to 4 cm³	4 to 8 cm³	>8 cm³
Midbrain				
Lesion, cm³	0.2 ± 0.14	1.1 ± 0.66	5.85 ± 0.92	14.9 ± 3.6
Treatment, cm³	0.4 ± 0.37	1.1 ± 0.71	4.95 ± 1.56	9.1 ± 3.3
PITV	2	1	0.85	0.61
Margin dose, Gy	23.2 ± 2	22.7 ± 2	20 ± 4	18.1 ± 2
Peak dose, Gy	42.2 ± 7	43.5 ± 6	40.5 ± 10	36.25 ± 5
Peritectal				
Lesion, cm³	0.24 ± 0.17	1.63 ± 0.92	5.75 ± 1.35	10.5 ± 3.5
Treatment, cm³	0.32 ± 0.2	1.81 ± 1.1	4.92 ± 1.23	7 ± 2
PITV	1.4	1.11	0.85	0.66
Margin dose, Gy	24.8 ± 7	22.6 ± 2	22.8 ± 3	20 ± 7
Peak dose, Gy	46.5 ± 7	44.7 ± 5	45.5 ± 0.7	40 ± 14
Pons/Med				
Lesion, cm³	0.26 ± 0.15	1.6 ± 0.9	6.7 ± 0.89	21.1 ± 10.8
Treatment, cm³	0.32 ± 0.17	1.6 ± 0.9	3.88 ± 1.7	7.61 ± 1.7
PITV	1.25	1	0.575	0.36
Margin dose, Gy	23.2 ± 2	21.8 ± 3	21 ± 3.6	22.5 ± 3.5
Peak dose, Gy	45 ± 7	44.9 ± 7	42 ± 7.2	45 ± 7
Thal/BG				
Lesion, cm³	0.2 ± 0.13	1.56 ± 0.95	5.8 ± 1	15.66 ± 7.7
Treatment, cm³	0.4 ± 0.35	1.86 ± 1.2	5.4 ± 1.3	10.74 ± 4.5
PITV	2	1.2	0.93	0.69
Margin dose, Gy	23.7 ± 2	23.2 ± 2	22.25 ± 3	21.2 ± 3
Peak dose,Gy	42.2 ± 7.5	44.6 ± 6.5	44.5 ± 6.5	43.5 ± 7

[a]PITV, treatment volume (prescription isodose) divided by lesion (target) volume[33]; Thal/BG, thalamus/basal ganglia.

Copyright © Congress of Neurological Surgeons. Unauthorized reproduction of this article is prohibited.

found to be an independent risk factor for future hemorrhage at least within the first 5 years[5,6,11] in deep AVMs, initially being as high as 34%.[4] Moreover, morbidity of hemorrhages was reported to be higher for deep eloquent AVMs, 70% to 85.5% of the patients were left with permanent neurological deficits after hemorrhage,[9-12] and mortality may even reach 43% within less than 10 years with conservative management.[8]

The largest thalamic/basal ganglia series studying the natural history so far enrolled about 100 patients,[8,9] and even less is known about the natural history of brainstem AVMs.[12] Being a national center offering service for about 60 million people in the United Kingdom and treating 2 to 300 AVMs a year for more than 20 years, we treated 356 thalamic/basal ganglia and 160 brainstem AVMs. Analysis of the pretreatment history of these deep eloquent AVMs, we believe, adds relevant information to our current knowledge about their natural history. A selection bias is unavoidable by reviewing such retrospective material, because we have no information about the mortality of initial hemorrhage, and another fraction of the patients were not referred either because they had been cured by other treatment modalities, or were considered incurable.

As a general rule, we found that smaller lesions more likely presented with hemorrhages (Table 2). However, we found only a nonsignificant tendency to higher bleed rates in smaller lesions (Table 3). Interestingly, the age at first hemorrhage was significantly (10 years) younger in the thalamic/basal ganglia group than in other groups. Our data support the view that smaller lesions only present with hemorrhage more frequently because they remain otherwise obscure, owing to their small size, but not because they would have a higher original bleeding rate.[1,36] However, a clear tendency of increasing rebleed rates was observed with increasing size in the thalamic/basal ganglia group (from 6.9% to 15.8%) (Table 3, Figure 2), in agreement with a recent study.[37] Rebleed rate was increased in all anatomic groups (5%–11%, depending on location), supporting the finding of several other groups that previous hemorrhage is a risk factor for further hemorrhages. The mean time between first hemorrhage and treatment was 2 to 4 years; therefore, we do not know whether the higher rebleed rate would have decreased after 5 years, as suggested by many studies.[5,6,11] It is also important to mention that our data may underestimate rebleed rates assuming an approximately 10% to 30% mortality.[38-40]

At the time of treatment, 40% to 60% of patients had persisting neurological deficits, mainly as a result of previous hemorrhages, with the rate depending on location (Figure 3).

Management Dilemma 1: Radiosurgery and Other Treatment Modalities

The aim of AVM management is the complete elimination of the pathological shunt with lower morbidity rate than the morbidity of the natural history. Unfortunately, not only is the natural history of deep eloquent AVMs more aggressive, but their management is also more hazardous. The desired instant cure with low morbidity can only be achieved in highly selected cases of this subgroup of AVMs with single-stage surgery or embolization.[17,41] In these series, complete resection of thalamic/basal ganglia AVMs was achieved with 2.4% mortality and 0% to 33% permanent morbidity,[17] whereas, in the brainstem, complete removal was at best 13% to 89%, with mortality reaching 30% and morbidity 14% to 40%.[42] Thus, only small ruptured lesions with existing significant preoperative deficits in the thalamus/basal ganglia[43] or small pial brainstem AVMs[41] are considered to be good surgical candidates even by the most experienced surgeons. Embolization alone is rarely curative, but may be useful as presurgical treatment,[17,41,44] and, even with multimodality treatment, complete angiographic obliteration is only 52% with about 20% morbidity in the posterior fossa.[41] Therefore, some suggest that none of the current treatment modalities are sufficiently efficacious in the treatment of deep Spetzler-Martin grade IV-V AVMs.[44]

Radiosurgery is widely accepted as a first-line treatment for these lesions, with 43% to 85% reported obliteration rates at 4 years after a single treatment, depending on size.[8,21-27] The overall outcome, however, is worse than for cortical lesions.[16,45] A prediction model estimated permanent postradiosurgery morbidity of 44% for pontine/midbrain, 12% to 15% for thalamic/basal ganglia, and only 7.4% for medullary AVMs with 1-cm diameter, and even higher rates for larger lesions.[45,46] In reality, the rate of permanent adverse radiation effects are reported to be lower, being 4% to 12% in patients treated with thalamic/basal ganglia AVMs[8,10,23,25,26] and 6% to 12% in brainstem AVMs.[21,24-26]

A major concern regarding radiosurgery is hemorrhage during latency period. Postradiosurgical bleed rate during latency period has been reported to be not higher than preradiosurgical bleed rate,[8,10,21,26] similar to cortical AVMs.[24,32,47] Overall, posttreatment hemorrhage-related morbidity has generally been reported to be 5%, but mortality of the posttreatment hemorrhages can be as high as 50% to 80%, resulting in 7% to 12% overall mortality in some series.[10,21,23,25] Thus, excellent outcomes range from 40% to 70%, depending on size,[10,25] but factors defining outcome have not yet been reliably specified.

Management Dilemma 2: Indications and Limitations for Radiosurgery

We analyzed outcomes of radiosurgical treatment on 321 patients with thalamic/basal ganglia and 140 with brainstem AVMs and found that the 2 major determinants for outcome were location and size. Based on our results, we can draw the following conclusions.

1. AVMs <4 cm^3 in the midbrain and <8 cm^3 in the peritectal diencephalon have low obliteration rates after single treatment. However, complication rates are very low, and a second radiosurgical session results in almost 80% to 90% obliteration rate with low morbidity; therefore, we advocate radiosurgical treatment for these lesions. We can only speculate on the reason for lower obliteration rates at the tectal region. A simple explanation would be that these lesions are more often found in the cistern and not surrounded by brain parenchyma.

Copyright © Congress of Neurological Surgeons. Unauthorized reproduction of this article is prohibited.

However, our data do not support this theory because we found no correlation between obliteration rate and the location of the tectal AVMs in relation to the cistern. Alternatively, the angioarchitecture of these lesions appears somewhat different, because they have less defined nidus with "mossy" structure, or the pathological vessels are less radiosensitive at this location. Obliteration tends to be higher with the maximum 25 Gy prescription isodose and with older angio-only based treatment planning, both pointing toward "overtreatment" and therefore supporting either theory. Currently, we have added CT angiography to our conventional catheter angiography and MRI for planning the treatment of these AVMs, which appears to display more sensitively a larger "cloudy" area defined as the nidus. It will be interesting to see whether our current planning technique improves obliteration rate in comparison with this historical material. Maruyama et al[24] analyzed the tectal region, but they found a higher complication rate without decreased obliteration rate. Validation of our observation is therefore needed from other radiosurgical centers.

2. Radiosurgical treatment of pontine/medullar and thalamic/basal ganglia AVMs <4 cm^3 is safe and effective.
3. All of our treatment efforts for brainstem lesions >4 cm^3 failed, even with improving treatment planning.
4. Outcome of thalamic/basal ganglia lesions >4 cm^3 is more contentious: excellent/good outcomes can be achieved with a single session in about 50% of the patients under optimal treatment conditions (introduction of axial planning (MRI) and the lack of preradiosurgery embolization).[48]
5. Our other recent study on the radiosurgical treatment of large AVMs[49] and preliminary results of staged volume radiosurgery[50] demonstrate the importance of optimal treatment planning for large AVMs. While the high complication rate has not been reduced with improving planning techniques of single-stage radiosurgery, it may be reduced in the future with staged volume radiosurgery.[50,51] Jones et al[51] recommended staging for deep eloquent AVMs >5 cm^3, which is close to the volume range for increasing side effects in our study.
6. A second radiosurgical session results in 60% to 90% obliteration rates with less than 10% mild treatment-specific complications, similar to other published series about unselected AVMs.[52,53]
7. Posttreatment hemorrhage rates were lower than pretreatment rates, with low mortality and permanent morbidity in lesions <4 cm^3, but with increased mortality and morbidity in the larger lesions (Figure 2, Tables 3 and 6). Of note, without the distinction between first ever hemorrhage and rebleed rates, results are misleading, because posttreatment hemorrhage rates were higher than crude pretreatment hemorrhage rates in the large thalamic/basal ganglia groups. In fact, once the AVM has bled, posttreatment bleed rates should be compared with pretreatment rebleed rates (Figure 2).
8. The high rebleed rate in the largest thalamic/basal ganglia AVMs is of concern. However, optimal radiosurgical treatment of such ruptured AVMs should be considered because of their poor natural history, unless complete surgical elimination is possible.

Management Dilemma 3: Unruptured Deep AVMs

It is debated whether unruptured AVMs should be managed actively.[54-56] Advocates of conservative management argue that treatment has higher morbidity than the short-term morbidity of natural history. However, the cumulative lifetime risk of hemorrhage-related morbidity and mortality – especially in younger patients – may be higher than treatment-induced morbidity, as pointed out by others.[57,58] This question is particularly sensitive in deep eloquent AVMs, because of both hemorrhage- and treatment-related high morbidities; and, reflecting on this dilemma, opposing strategies are published about the management of Spetzler-Martin grade IV and V AVMs: some consider active treatment justifiable only in exceptional cases,[59] whereas others advocate aggressive management because of the poor natural history.[60]

Although the proportion of unruptured AVMs smaller than 4 cm^3 is relatively low in this material, none of them bled after radiosurgery. Therefore, we believe that radiosurgery–being safe and effective – can be confidently recommended for deep small unruptured AVMs. Large AVMs are more problematic. Their natural history seems to be very poor: a conservative estimation of the cumulative hemorrhage risk of this AVM group is 40% at 20 years and 70% at 40 years after diagnosis.[6] Calculating with 20% mortality and 40% major morbidity of hemorrhages,[61] 8% and 14% of the patients are dead, and 16% and 30% are left with major impairment 20 and 40 years after diagnosis, respectively. Moreover, this is probably an underestimation because a large study found 43% 10-year mortality of conservatively managed thalamic/basal ganglia AVMs.[8] Our other recent study (Nagy et al, in publication) demonstrated that once an unruptured deep AVM was diagnosed, the first ever bleed rate increased from 1.5% to 7% annually, not differing significantly from the annual posttreatment bleed risk (9.2%, Table 3). Both overall disabling (>MRS2) permanent posttreatment morbidity and mortality are 12% in unruptured thalamic/basal ganglia AVMs larger than 4 cm^3. Thus, both natural history and active management have poor prognosis in this group. In our opinion, active management may be considered for young patients after a very frank consenting procedure.

CONCLUSION

The major determinants of radiosurgical outcome of deep eloquent AVMs are size and location. Radiosurgery for such AVMs smaller than 4 cm^3 is safe and effective in all anatomic subgroups. Obliteration rate is significantly lower in midbrain and peritectal diencephalon, but morbidity is mild and low, and repeat radiosurgery is effective. Brainstem lesions larger than 4 cm^3 have poor outcome; therefore, radiosurgery alone is seldom recommended. Only half of the thalamic/basal ganglia AVMs larger than 4 cm^3 are cured with excellent to good outcome with single-stage radiosurgical treatment, but a second radiosurgical

Copyright © Congress of Neurological Surgeons. Unauthorized reproduction of this article is prohibited.

session is curable in another two-thirds of the patients with low risk. Overall, posttreatment morbidity and mortality of these large thalamic/basal ganglia lesions are significantly increased. Thus, the outcome of single-stage radiosurgical treatment is disappointing, but so is their natural history. It is hoped that the recently introduced staged volume radiosurgery may improve outcome in this group, and therefore radiosurgery can be offered after careful consent with balancing the risks and benefits.

Disclosures

The authors have not received funding for this work from any of the following organizations: National Institutes of Health; Wellcome Trust; Howard Hughes Medical Institute; and other foundation(s) requiring open access. The authors have no personal financial or institutional interest in any of the drugs, materials, or devices described in this article.

REFERENCE

1. Kader A, Young WL, Pile-Spellman J, et al. The Influence of hemodynamic and anatomic factors on hemorrhage from cerebral arteriovenous malformations. *Neurosurgery*. 1994;34(5):801-808.
2. Turjman F, Massoud TF, Viñuela F, Sayre JW, Guglielmi G, Duckwiler G. Correlation of the angioarchitectural features of cerebral arteriovenous malformations with clinical presentation of hemorrhage. *Neurosurgery*. 1995;37(5):856-862.
3. Khaw AV, Mohr JP, Sciacca RR, et al. Association of infratentorial brain arteriovenous malformations with hemorrhage at initial presentation. *Stroke*. 2004; 35(3):660-663.
4. Stapf C, Mast H, Sciacca RR, et al. Predictors of hemorrhage in patients with untreated brain arteriovenous malformation. *Neurology*. 2006;66(9):1350-1355.
5. Yamada S, Takagi Y, Nozaki K, Kikuta K, Hashimoto N. Risk factors for subsequent hemorrhage in patients with cerebral arteriovenous malformations. *J Neurosurg*. 2007;107(5):965-972.
6. Hernesniemi JA, Dashti R, Juvela S, Väärt K, Niemelä M, Laakso A. Natural history of brain arteriovenous malformations: a long-term follow-up study of risk of hemorrhage in 238 patients. *Neurosurgery*. 2008;63(5):823-831.
7. da Costa L, Wallace MC, ter Brugge KG, O'Kelly C, Willinsky RA, Tymianski M. The natural history and predictive features of hemorrhage from brain arteriovenous malformations. *Stroke*. 2009;40(1):100-105.
8. Sasaki T, Kurita H, Saito I, et al. Arteriovenous malformations in the basal ganglia and thalamus: management and results in 101 cases. *J Neurosurg*. 1998;88(2):285-292.
9. Fleetwood IG, Marcellus ML, Levy RP, Marks MP, Steinberg GK. Deep arteriovenous malformations of the basal ganglia and thalamus: natural history. *J Neurosurg*. 2003;98(4):747-750.
10. Andrade-Souza YM, Zadeh G, Scora D, Tsao MN, Schwartz ML. Radiosurgery for basal ganglia, internal capsule, and thalamus arteriovenous malformation: clinical outcome. *Neurosurgery*. 2005;56(1):56-64.
11. Fults D, Kelly DL Jr. Natural history of arteriovenous malformations of the brain: a clinical study. *Neurosurgery*. 1984;15(5):658-662.
12. Abe M, Kjellberg RN, Adams RD. Clinical presentations of vascular malformations of the brain stem: comparison of angiographically positive and negative types. *J Neurol Neurosurg Psychiatry*. 1989;52(2):167-175.
13. Schneider BF, Eberhard DA, Steiner LE. Histopathology of arteriovenous malformations after gamma knife radiosurgery. *J Neurosurg*. 1997;87(3):352-357.
14. Steiner L, Sheehan J, Lindquist C, Stroila M, Steiner M. Gamma knife surgery for cerebral vascular malformations, tumors, and functional disorders. In: Schmidek H, Roberts D, eds. *Schmidek and Sweet's Operative Neurosurgical Techniques: Indications, Methods, and Results*. 5th ed. Philadelphia, PA: WB Saunders; 2005:530-576.
15. Szeifert GT, Timperley WR, Forster DM, Kemeny AA. Histopathological changes in cerebral arteriovenous malformations following Gamma Knife radiosurgery. *Prog Neurol Surg*. 2007;20:212-219.
16. Pollock BE, Flickinger JC. A proposed radiosurgery-based grading system for arteriovenous malformations. *J Neurosurg*. 2002;96(1):79-85.
17. Gross BA, Duckworth EAM, Getch CC, Bendok BR, Batjer HH. Challenging traditional beliefs: microsurgery for arteriovenous malformations of the basal ganglia and thalamus. *Neurosurgery*. 2008;63(3):393-411.
18. Lunsford LD, Kondziolka D, Flickinger JC, et al. Stereotactic radiosurgery for arteriovenous malformations of the brain. *J Neurosurg*. 1991;75(4):512-524.
19. Pollock BE, Flickinger JC, Lunsford LD, Maitz A, Kondziolka D. Factors associated with successful arteriovenous malformation radiosurgery. *Neurosurgery*. 1998;42(6):1239-1244.
20. Kemeny AA, Radatz MW, Rowe JG, Walton L, Hampshire A. Gamma knife radiosurgery for cerebral arteriovenous malformations. *Acta Neurochir Suppl*. 2004; 91:55-63.
21. Kurita H, Kawamoto S, Sasaki T, et al. Results of radiosurgery for brain stem arteriovenous malformations. *J Neurol Neurosurg Psychiatry*. 2000;68(5):563-570.
22. Massager N, Régis J, Kondziolka D, Njee T, Levivier M. Gamma knife radiosurgery for brainstem arteriovenous malformations: preliminary results. *J Neurosurg*. 2000;93(suppl 3):102-103.
23. Nicolato A, Foroni R, Crocco A, et al. Gamma knife radiosurgery in the management of arteriovenous malformations of the Basal Ganglia region of the brain. *Minim Invasive Neurosurg*. 2002;45(4):211-223.
24. Maruyama K, Kawahara N, Shin M, et al. The risk of hemorrhage after radiosurgery for cerebral arteriovenous malformations. *N Engl J Med*. 2005;352(2):146-153.
25. Pollock BE, Gorman DA, Brown PD. Radiosurgery for arteriovenous malformations of the basal ganglia, thalamus, and brainstem. *J Neurosurg*. 2004;100(2):210-214.
26. Zabel-du Bois A, Milker-Zabel S, Huber P, Schlegel W, Debus J. Stereotactic linac-based radiosurgery in the treatment of cerebral arteriovenous malformations located deep, involving corpus callosum, motor cortex, or brainstem. *Int J Radiat Oncol Biol Phys*. 2006;64(4):1044-1048.
27. Kiran NAS, Kale SS, Kasliwal MK, et al. Gamma knife radiosurgery for arteriovenous malformations of basal ganglia, thalamus and brainstem—a retrospective study comparing the results with that for AVMs at other intracranial locations. *Acta Neurochir (Wien)*. 2009;151(12):1575-1582.
28. Spetzler RF, Martin NA. A proposed grading system for arteriovenous malformations. *J Neurosurg*. 1986;65(4):476-483.
29. Coley SC, Wild JM, Wilkinson ID, Griffiths PD. Neurovascular MRI with dynamic contrast-enhanced subtraction angiography. *Neuroradiology*. 2003; 45(12):843-850.
30. Mori H, Aoki S, Okubo T, et al. Two-dimensional thick-slice MR digital subtraction angiography in the assessment of small to medium-size intracranial arteriovenous malformations. *Neuroradiology*. 2003;45(1):27-33.
31. van Swieten JC, Koudstal PJ, Visser MC, Schouten HJ, van Gijn J. Interobserver agreement for the assessment of handicap in stroke patients. *Stroke*. 1988;19(5): 604-607.
32. Friedman WA, Blatt DL, Bova FJ, Buatti JM, Mendenhall WM, Kublis PS. The risk of hemorrhage after radiosurgery for arteriovenous malformations. *J Neurosurg*. 1996;84(6):912-919.
33. Shaw E, Kline R, Gillin M, et al. Radiation Therapy Oncology Group: radiosurgery quality assurance guidelines. *Int J Radiat Oncol Biol Phys*. 1993;27(5):1231-1239.
34. Mast H, Young WL, Koennecke HC, et al. Risk of spontaneous haemorrhage after diagnosis of cerebral arteriovenous malformation. *Lancet*. 1997;350(9084): 1065-1068.
35. Al-Shahi R, Bhattacharya JJ, Currie DG, et al. Prospective, population-based detection of intracranial vascular malformations in adults. The Scottish Intracranial Vascular Malformation Study (SIVMS). *Stroke*. 2003;34(5): 1163-1169.
36. Crawford PM, West CR, Chadwick DW, Shaw MD. Arteriovenous malformation of the brain: natural history in unoperated patients. *J Neurol Neurosurg Psychiatry*. 1986;49(1):1-10.
37. Laakso A, Dashti R, Juvela S, Isarakul P, Niemelä M, Hernesniemi J. Risk of hemorrhage in patients with untreated Spetzler-Martin grade IV and V arteriovenous malformations: a long-term follow-up study in 63 patients. *Neurosurgery*. 2011;68(2):372-377.
38. Hillman J. Population-based analysis of arteriovenous malformation treatment. *J Neurosurg*. 2001;95(4):633-637.
39. Brown RD Jr, Wiebers DO, Forbes G, et al. The natural history of unruptured intracranial arteriovenous malformations. *J Neurosurg*. 1988;68(3):352-357.
40. ApSimon HT, Reef H, Phadke RV, Popovic EA. A population-based study of brain arteriovenous malformation. Long-term treatment outcomes. *Stroke*. 2002; 33(12):2794-2800.

Copyright © Congress of Neurological Surgeons. Unauthorized reproduction of this article is prohibited.

41. Kelly ME, Guzman R, Sinclair J, et al. Multimodality treatment of posterior fossa arteriovenous malformations. *J Neurosurg*. 2008;108(6):1152-1161.
42. Chandler JP, Grenier Y, Getch CC, Russel EJ, Batjer HH. Posterior fossa arteriovenous malformations. In: Sekhar L, Fessler RG, eds. *Atlas of Neurosurgical Techniques. Brain*. New York, NY: Thieme; 2006:275-284.
43. Duckworth EA, Gross B, Batjer HH. Thalamic and basal ganglia arteriovenous malformations: redefining "inoperable". *Neurosurgery*. 2008;63(1 suppl 1): ONS63-ONS69.
44. Lawton MT, Hamilton MG, Spetzler RF. Multimodality treatment of deep arteriovenous malformations: thalamus, basal ganglia, and brain stem. *Neurosurgery*. 1995;37(1):29-36.
45. Flickinger JC, Kondziolka D, Lunsford LD, et al. Development of a model to predict permanent symptomatic postradiosurgery injury for arteriovenous malformation patients. *Int J Radiat Oncol Biol Phys*. 2000;46(5):1143-1148.
46. Flickinger JC, Kondziolka D, Niranjan A, Lunsford LD. Dose selection in stereotactic radiosurgery. *Prog Neurol Surg*. 2007;20:28-42.
47. Pollock BE, Flickinger JC, Lunsford LD, Bissonette DJ, Kondziolka D. Hemorrhage risk after stereotactic radiosurgery of cerebral arteriovenous malformations. *Neurosurgery*. 1996;38(4):652-661.
48. Andrade-Souza YM, Ramani M, Scora D, Tsao MN, terBrugge K, Schwartz ML. Embolization before radiosurgery reduces the obliteration rate of arteriovenous malformations. *Neurosurgery*. 2007;60(3):443-452.
49. Nagy G, Rowe JG, Radatz MW, Hodgson TJ, Coley SC, Kemeny AA. A historical analysis of single-stage gamma knife radiosurgical treatment for large arteriovenous malformations: evolution and outcomes. *Acta Neurochir (Wien)*. 2012;154(3): 383-394.
50. Sirin S, Kondziolka D, Niranjan A, Flickinger JC, Maitz AH, Lunsford LD. Prospective staged volume radiosurgery for large arteriovenous malformations: indications and outcomes in otherwise untreatable patients. *Neurosurgery*. 2006; 58(1):17-27.
51. Jones J, Jang S, Getch CC, Kepka AG, Marymont MH. Advances in the radiosurgical treatment of large inoperable arteriovenous malformations. *Neurosurg Focus*. 2007;23(6):E7.
52. Karlsson B, Kihlstrom L, Lindquist C, Steiner L. Gamma knife surgery for previously irradiated arteriovenous malformations. *Neurosurgery*. 1998;42(1):1-6.
53. Maesawa S, Flickinger JC, Kondziolka D, Lunsford LD. Repeated radiosurgery for incompletely obliterated arteriovenous malformations. *J Neurosurg*. 2000;92(6): 961-970.
54. Stapf C, Mohr JP. Unruptured brain arteriovenous malformations should be treated conservatively: yes. *Stroke*. 2007;38(12):3308-3309.
55. Stapf C, Mohr JP, Choi JH, Hartmann A, Mast H. Invasive treatment of unruptured brain arteriovenous malformations is experimental therapy. *Curr Opin Neurol*. 2006;19(1):63-68.
56. Wedderburn JC, van Beijnum J, Bhattacharya JJ, et al. Outcome after interventional or conservative management of unruptured brain arteriovenous malformations: a prospective, population-based cohort study. *Lancet Neurol*. 2008;7(3):223-230.
57. Cockroft KM. Unruptured brain arteriovenous malformations should be treated conservatively: no. *Stroke*. 2007;38(12):3310-3311.
58. Laakso A, Dashti R, Seppänen J, et al. Long-term excess mortality in 623 patients with brain arteriovenous malformations. *Neurosurgery*. 2008;63(2):244-255.
59. Spetzler RF, Ponce FA. A 3-tier classification of cerebral arteriovenous malformations. *J Neurosurg*. 2011;114(3):842-849.
60. Jayaraman MV, Marcellus ML, Do HM, et al. Hemorrhage rate in patients with Spetzler-Martin grades IV and V arteriovenous malformations: is treatment justified? *Stroke*. 2007;38(2):325-329.
61. Ondra SL, Troupp H, George ED, Schwab K. The natural history of symptomatic arteriovenous malformations of the brain: a 24-year follow-up assessment. *J Neurosurg*. 1990;73(3):387-391.

COMMENTS

This is a report destined to be a classic in arteriovenous malformation (AVM) radiosurgery. We have to congratulate the authors for the thorough and thoughtful review of their material. These deep-seated AVMs with deep venous drainage and occupying highly eloquent areas of the brain have high morbidity and mortality, as the authors mentioned in their introduction, possibly reaching 34% risk of bleeding per year. They are providing with this selected analysis of their 416 AVM patients information of utmost importance for our communication with patients harboring these centrally located lesions. As all retrospective data, the authors lacked follow-up in all their patients, but they present here a remarkable percentage of patients followed clinically (close to 90%) and radiologically (approximately 70%). This is probably the best that is achievable by any group treating AVMs and having such a large number of patients.

The authors showed that the great majority of these AVMs present with hemorrhage, approximately 80% in all of the 4 categories into which they divided their cases, confirming the high risk these lesions represent to patients. It is well accepted that these lesions are poor candidates for surgery and embolization because of their location and difficult access to feeders by endovascular approach. The authors are presenting AVMs of small volume, classically accepted for radiosurgery with the Gamma-Knife. Their results reflect what is known regarding volume, eloquence, and doses of radiosurgery treatment. They were consistent, however, on delivering a narrow range of radiation dose based on location and clearly compromised the dose based on volume. This reflected on their observed obliteration rate, which decreases as the volume increases. However, they ascertain that in their initial experience they gave the same dose to all AVMs (25Gy) and yet observed less obliteration for the larger lesions.

Interesting is the significantly increased bleeding rate in larger unruptured lesions, either in brainstem and thalamus/basal ganglia. There are many reasons possibly contributing for these findings. The first could be a consequence of multiple isocenter technique with inhomogeneous dose distribution inside of the target (hot spots), possibly modifying the hemodynamic of the AVM unpredictably during the obliteration waiting period, explaining the initial increased rate of bleeding of these lesions after radiosurgery. Novel approaches of more homogeneous dose distribution and hypofractionation may obviate this undesirable side effect.[1] A second reason would be a consequence of the necessary radiation dose compromise when treating large AVMs in eloquent areas, extending the latency period until obliteration is obtained. More frequently, retreatment is required, therefore, adding additional treatment morbidity to the already high risk of bleeding for deep-seated AVMs. The increased bleeding risk was significantly higher than the bleeding rate before treatment only in the group of large unruptured AVMs. This finding is in accordance with the data derived from other landmark studies in the literature and cited by the authors. This fact points to the direction of more sophisticated understanding of the hemodynamics of unruptured AVMs and possibly best tailored use of radiation for this particular subgroup. We already know that mistargeting leads to increased bleeding risk. Even the most recent publications of staged radiosurgery suggest in increased rate of bleeding, therefore this approach may taken with caution.[2]

This series is the largest one in the literature dealing with this specifically located AVMs. It clearly shows that radiosurgery results for deep-seated AVMs are not as brilliant as for small cortical AVMs but still very good, allowing the possibility of re-treatment with satisfactory obliteration rates and low morbidity for small to moderate lesions, ie, up to 8 mL or 2.5 cm in diameter. Their results corroborate to the extensive discussion existent in the literature and highlight the questions pending clarification. The crucial pending questions are directed to the large/giant unruptured deep-seated AVMs: (1) If left untreated, is the bleeding rate lower and, if so, within what time span? It is still unclear whether radiosurgery may increase the bleeding rate during the initial years posttreatment. And if it does, what about the bleeding risk at 20 years, 40 years once a proportion of these large AVMs will be obliterated during the life span of young

Copyright © Congress of Neurological Surgeons. Unauthorized reproduction of this article is prohibited.

population? (2) Does the severity of the bleeding differ after radiosurgery treatment of this subgroup of AVMs in comparison with nontreated lesions?

As the authors appropriately discuss, the interpretation of their findings on large deep-seated AVMs must be taken with caution. This series reflects the results of radiosurgery treatment encompassing a period of 20 years, which means that mistargeting may have been a factor contributing to increased hemorrhage rate after radiosurgery treatment in the era before routine use of 3D images for targeting (CT/ MRI/ MRA). The baseline hemorrhage rate for comparison is the natural history of the series cohort adding to 5 to 6 years at the most and in a small number of cases, imposing a strong limitation on the number of events for this sake. According to the data from Stapf,[3] the annual bleeding risk for deeply located AVMs with deep venous drainage and no hemorrhage is 5.5%, which is higher than the rate observed in this cohort (2.5%-2.8%). Because of the multiple confounding factors associated with this valuable, but limited by the retrospective nature of the analysis, the ARUBA trial aims to establish the true incidence of bleeding for AVMs receiving or not any type of intervention, by subgroups. Hopefully, despite the difficulties in recruitment in the United States, the ARUBA trial will be able to provide definitive data on this matter.[4]

The high (16%) permanent radiation-induced complications reported here highlight the increased risk of radiosurgery to deep-seated lesions, but also reflect the pioneer work of these authors with the initial technology learning curve and lack of 3-dimensional (3D) radiosurgery planning, what the authors call axial MRI, in the early years. It is plausible that with the incorporation of 3D angiography, functional imaging, and tractography to radiosurgery planning the rate of radiation undesired effects will decrease, even though the authors failed to observe an improvement in the obliteration rate in their own series. Moreover, the decrease in the number of radiation-induced complications seems to be an equally important end point to achieve, amenable with better definition of organs at risk, since dose prescription change likely will compromise the already less than optimal results.

Overall, this is a unique set of data based on the sheer number of patients, the outstanding analysis and candid report by the authors. It is a great addition to our knowledge of AVM treatment with focus radiation.

Antonio A.F. De Salles
Alessandra A. Gorgulho
Los Angeles, California

1. Xiao F, Gorgulho AA, Lin CS, et al. Treatment of giant cerebral arteriovenous malformation: hypofractionated stereotactic radiation as the first stage. *Neurosurgery*. 2010;67(5):1253-1259; discussion 1259.
2. Sirin S, Kondziolka D, Niranjan A, Flickinger JC, Maitz AH, Lunsford LD. Prospective staged volume radiosurgery for large arteriovenous malformations: indications and outcomes in otherwise untreatable patients. *Neurosurgery*. 2006;58 (1):17-27; discussion 17-27.
3. Stapf C, Mast H, Sciacca RR, et al. Predictors of hemorrhage in patients with untreated brain arteriovenous malformation. *Neurology*. 2006;66(9):1350-1355.
4. Mohr JP, Moskowitz AJ, Stapf C, et al. The ARUBA trial: current status, future hopes. *Stroke*. 2010;41(8):e537-e540.

The authors report their experience, accrued over many years, in the management of cerebral arteriovenous malformations in critical locations. As one of the initial proponents of AVM radiosurgery, they first used an early-generation gamma knife device with improvements in both hardware and software being incorporated through the years. Indeed, they evolved as they learned and as the experience among centers was shared. The AVM margin dose of 25 Gy was commonly used in many early patients, only to find that, in some instances, it was excessive because of the occurrence of adverse radiation effects. The balance between the goal of complete AVM obliteration and tissue safety was one that took years to define. Thus, this report contains many lessons, only some of which are related to AVM radiosurgery. In reading this report, one will learn about developing solutions to complex neurosurgical problems, the importance of data collection and technique refinement, and how some ideas require additional parallel developments (like magnetic resonance imaging [MRI]) to truly gain traction.

Douglas Kondziolka
Pittsburgh, Pennsylvania

In this article, the authors present a very thorough and insightful analysis of their 356 patients with thalamic/basal ganglia and 160 patients with brainstem AVMs. The natural history of deep, thalamic AVMs have repeatedly shown to be more aggressive and their management more complicated than their smaller, superficial counterparts. The use of multimodality treatment including surgery, embolization, and radiosurgery remains controversial. While some claim such collaborative interventions are necessary to obtain complete AVM obliteration, recent studies have demonstrated as high as a 24-fold higher risk of treatment complications in patients who underwent several different types of treatment. This of course conveys that AVM treatment depends on location, morphology, and clinical presentation and that the goals of care for each patient will be distinct. The authors of this article have presented the largest known series that examines a very specific cohort of patients with cerebral AVMs.

The present study provides a global characterization of demographics, clinical presentation, treatment algorithm, hemorrhage rates, and outcomes of patients with AVMs that are less amenable to surgical or interventional therapy. For such a large number of patients, the authors have obtained follow-up, clinical and/or radiographic, in greater than 70% of their patients. Specifically, the authors define 4 distinct locations for the AVMs included in the study: thalamic/basal ganglia, peritectal diencephalon, midbrain/tectal, and pontine/medullar. Majority of patients presented with hemorrhage (>80%), which was noted to be higher in smaller lesions.

The mean time between presentation and treatment was 4 years, and this period of time was used to calculate the pretreatment rebleed rates, which were found to increase with size in the thalamic group. Obliteration rates were found to be less in the peritectal region and midbrain in comparison with other locations studied. At 4 years, the authors note approximately 41% of midbrain, 42.5% of peritectal, 65% of pontine/medullar, and 69% of thalamic/BG lesions were obliterated. Larger lesions where shown to have lower obliteration rates with higher adverse radiation side-effect rates. The treatment side effects are not trivial either. As demonstrated in multiple other, smaller studies, permanent neurologic deficit is often correlated with the size of the lesion treated. In this study, the authors note a 50% permanent morbidity in patients with AVMs greater than 8 cm in size. Furthermore, 44% of patients in the large thalamic/BG group who bled after treatment died. Similarly, the Pittsburgh group has recently reported their large series of BG and thalamic AVMs in which they found that larger target volume, larger maximum diameter, lower margin dose, and a higher Pollock-Flickinger score were all factors contributing to worsened adverse radiation events.

The treatment algorithm for radiosurgery in this cohort, to no fault of the authors, does vary. Due to limitation in technological availability,

Copyright © Congress of Neurological Surgeons. Unauthorized reproduction of this article is prohibited.

MRI was introduced to radiosurgery planning after 1996. Initially, a marginal dose of 25Gy was used regardless of size and location, but the authors eventually reduced the dosing for eloquent locations, younger patients, larger lesions, and those who underwent previous radiotherapy. In the absence of 3D planning, AVM targeting was likely much more challenging and potentially less accurate than the later half of their cohort. It would be interesting to examine, in more detail, the implementation of 3D planning and updated technology to report how this has influenced treatment delivery and outcome of deep AVMs.

A subset of this study is the treatment of giant AVMs. In our experience, multimodality treatment has been efficacious in achieving good clinical and radiographic outcome. Having defined giant AVMs as those greater than 6 cm, we found that a combination of surgery, endovascular embolization, and radiosurgery of our 53 patients resulted in 19 (36%) having complete angiographic resolution of their AVM, 90% obliteration was achieved in 4 patients (8%), and less than 90% obliteration was achieved in 29 patients (55%). At 3 years of follow-up, 33 patients either completed treatment or were alive more than 3 years after undergoing their most recent radiosurgery; 19 patients (58%) were cured of their AVMs with a long-term treatment-related morbidity rate was 15%. Similarly, the authors report that an approximately 50% success rate in their cohort, though with more complications > MRS3.

In conclusion, the authors should be commended for their dedication to providing the neurosurgical community with evidence to help our patients make decisions regarding the care of their very complex disease process. The true natural history of untreated AVMs, whether deep or superficial, is still being determined; however, this article provides insight to the subset of our population for whom little is known.

Anand Veeravagu
Steven D. Chang
Stanford, California

1. Chang SD, Marcellus ML, Marks MP, Levy RP, Do HM, Steinberg GK. Multimodality treatment of giant intracranial arteriovenous malformations. *Neurosurgery*. 2007;61(1 suppl):432-442; discussion 442-444.
2. Xiao F, Gorgulho AA, Lin CS, et al. Treatment of giant cerebral arteriovenous malformation: hypofractionated stereotactic radiation as the first stage. Department of Neurosurgery and the Stanford Stroke Center, Stanford University School of Medicine, Stanford, California.

FOLLOW NEUROSURGERY® ON WORDPRESS

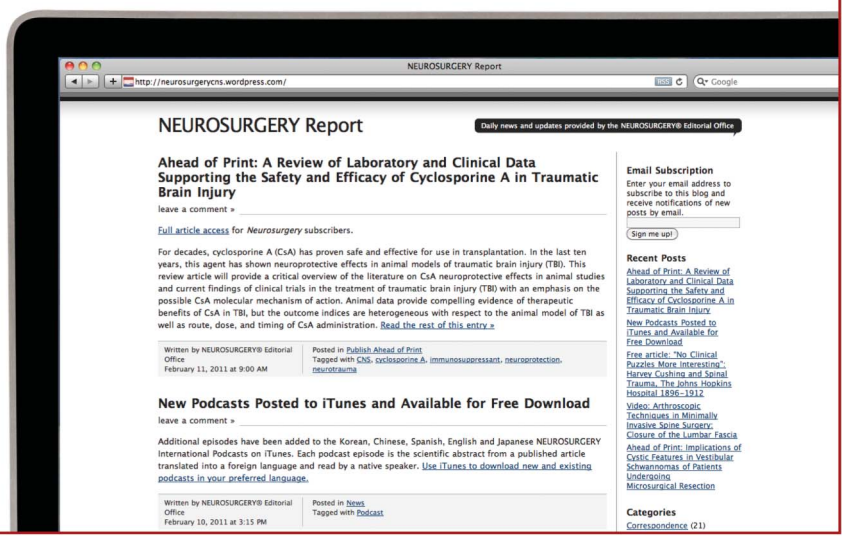

Follow NEUROSURGERY® at http://neurosurgerycns.wordpress.com

NEUROSURGERY
THE REGISTER OF THE NEUROSURGICAL MEME

Copyright © Congress of Neurological Surgeons. Unauthorized reproduction of this article is prohibited.