See the corresponding editorial in this issue, pp 362–363.

J Neurosurg 119:364–372, 2013
©AANS, 2013

The role of preoperative embolization for intracranial meningiomas

A review

Ashish H. Shah, B.S.,[1] Neal Patel,[1] Daniel M. S. Raper, M.B.B.S.,[2] Amade Bregy, M.D., Ph.D.,[1] Ramsey Ashour, M.D.,[1] Mohamed Samy Elhammady, M.D.,[1] Mohammad Ali Aziz-Sultan, M.D.,[1] Jacques J. Morcos, M.D.,[1] Roberto C. Heros, M.D.,[1] and Ricardo J. Komotar, M.D.[1]

[1]Department of Neurological Surgery, University of Miami, Florida; and [2]Department of Neurological Surgery, Royal North Shore Hospital, Sydney, Australia

Object. As endovascular techniques have become more advanced, preoperative embolization has become an increasingly used intervention in the management of meningiomas. To date, however, no consensus has been reached on the use of this technique. To clarify the role of preoperative embolization in the management of meningiomas, the authors conducted a systematic review of case reports, case series, and prospective studies to increase the current understanding of the management options for these common lesions and complications associated with preoperative embolization.

Methods. A PubMed search was performed to include all relevant studies in which the management of intracranial meningiomas with preoperative embolization was reported. Immediate complications of embolization were reported as major (sustained) or minor (transient) deficits, death, or no neurological deficits.

Results. A total of 36 studies comprising 459 patients were included in the review. Among patients receiving preoperative embolization for meningiomas, 4.6% (n = 21) sustained complications as a direct result of embolization. Of the 21 patients with embolization-induced complications, the incidence of major complications was 4.8% (n = 1) and the mortality rate was 9.5% (n = 2).

Conclusions. Preoperative embolization is associated with an added risk for morbidity and mortality. Preoperative embolization may be associated with significant complications, but careful selection of ideal cases for embolization may help reduce any added morbidity with this procedure. Although not analyzed in the authors' study, embolization may still reduce rates of surgical morbidity and mortality and therefore may still have a potential benefit for selected patients. Future prospective studies involving the use of preoperative embolization in certain cases of meningiomas may further elucidate its potential benefit and risks.
(http://thejns.org/doi/abs/10.3171/2013.3.JNS121328)

Key Words • **preoperative embolization** • **meningioma** • **complications** • **systematic review** • **oncology**

Intracranial meningiomas, though most often benign, may be associated with seizures, headaches, vision loss, or focal neurological deficits.[2,28] The current treatment paradigm for these lesions consists of safe, gross-total resection including the adjacent involved dura and bone, although some small incidental lesions may be primarily followed with active surveillance.[31,32,49] The extent of resection depends on a variety of factors including the location of the lesion, size, and proximity to vital structures. In recent years, preoperative embolization of meningiomas has been proposed as a method to reduce intraoperative complications and increase the ability to obtain a total resection at the time of surgery.[10,12,35]

Preoperative embolization may facilitate surgery by reducing blood loss and operating time.[10,12,35] Furthermore, several studies have shown that preoperative embolization may increase the ability to achieve gross-total resection of both skull base and large supratentorial meningiomas.[35,38] Embolization leads to devascularization of the target lesion, which may induce necrosis prior to surgery and in turn will facilitate resection (Fig. 1). This is particularly true when blood supply is on the other side of the tumor vis-à-vis the surgeon's line of sight. However, embolization is associated with a number of serious risks including tu-

Abbreviation used in this paper: PVA = polyvinyl alcohol.

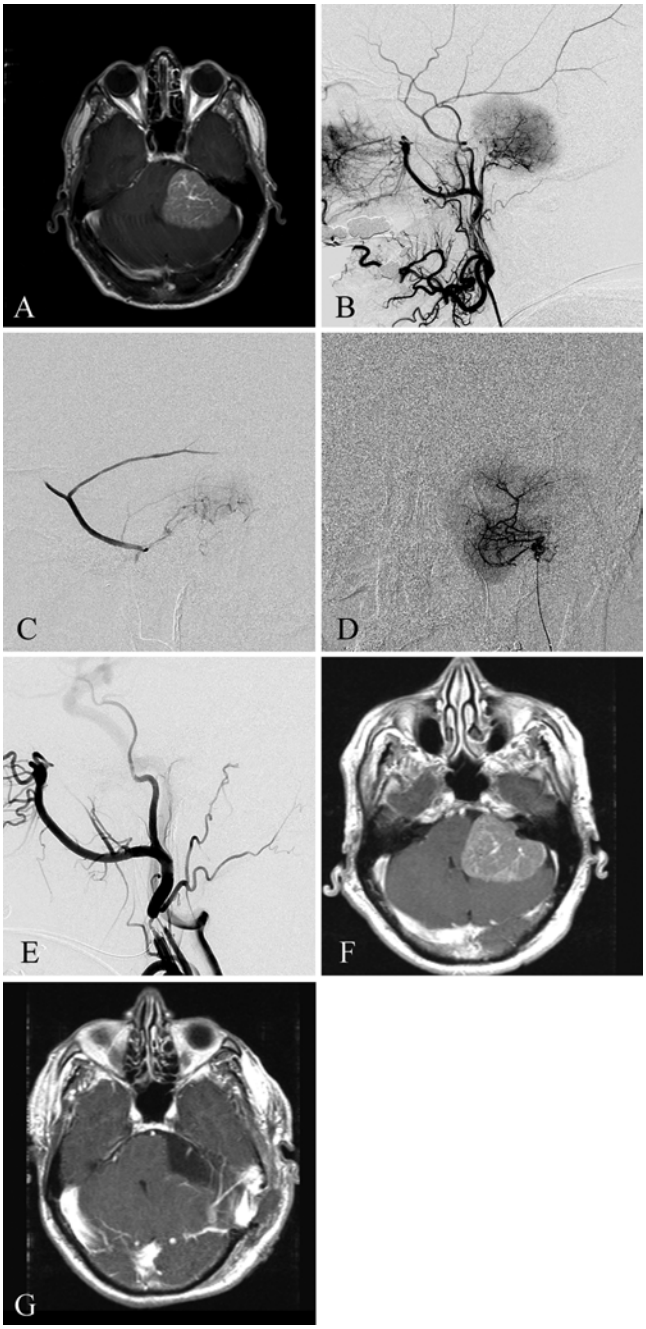

Fig. 1. The successful resection of a highly vascular petrous meningioma following preoperative embolization. Large petrous meningioma with prominent intratumoral blood vessels well visualized on contrast-enhanced MRI **(A)**. Left external carotid artery angiogram demonstrating hypervascular tumor blush supplied predominantly by the left ascending pharyngeal artery with a smaller contribution from the left middle meningeal artery **(B)**. Left middle meningeal pedicle **(C)** and left ascending pharyngeal pedicle **(D)** were selectively catheterized for embolization with Onyx-18. Final left external carotid artery angiogram after embolization demonstrating near-complete devascularization of the tumor **(E)**. Preoperative postembolization **(F)** and postoperative **(G)** MR images revealing successful resection of tumor.

moral hemorrhage, ischemia from untargeted vessel embolization, edema, worsening mass effect, hydrocephalus, cranial nerve deficits, seizures, and infection.[7–9] To better define the role of preoperative embolization for intracranial meningiomas, we have conducted a systematic review of the literature to help define the types and frequency of complications associated with preoperative embolization. This review hopes to answer questions pertaining to the viability and the usefulness of preoperative embolization.

Methods

Study Selection

Using the MeSH database system of PubMed, a literature search was performed by searching the years between 1990 and 2011 for all articles containing the phrases "meningioma" and "preoperative embolization." We then expanded our search to a general PubMed search of the following phrases using the MeSH system: ("Meningioma"[Mesh]) AND "Embolization, Therapeutic"[Mesh]. Articles were limited to English, and human beings were defined as the subjects for this study. Inclusion was limited to studies that used embolization as a treatment prior to surgery only. Articles in which embolization was undertaken with separate therapeutic intent were excluded. Case reports (detailing 1 or 2 specific patient symptoms, signs, diagnosis, treatment, and follow-up), retrospective studies (detailing more than 2 cases in a less specific and more data-based manner), and prospective analyses (following, analyzing, and documenting patients over time) were included, while editorials and commentaries were excluded. Articles focused on preoperative embolization that did not report surgical outcomes were excluded, as were reports primarily reporting on technique. Two authors reviewed the articles, and a single screener decided which articles to include or exclude, while discrepancies or indecisions were resolved via discussion with the other authors. A second author screened the articles to minimize the risk of selection bias. Individual study bias was mitigated by reviewing and confirming the appropriate sources indicated. One hundred fifty relevant articles were identified from this initial screen.

No studies were found to be duplicates. The last search was performed on October 21, 2011.

Data Extraction

The included studies were carefully analyzed based on the patient population, methodology, embolization technique and materials, embolization-related complications, location of the lesion, and blood loss. The studies were separated into groups based on embolic material and tumor location and were analyzed for embolization-induced complications.

Complications were defined as major if they represented sustained new deficits or minor if they were transient and resolved. It is noted that many papers did not separate complications for each subset of patients (location or artery embolized), so some comparative analysis is limited due to the nature of the data. Data for all patients was reported when available in the literature. Statistical tests were not performed.

Results

Study Selection

The initial PubMed search returned 212 research studies. After screening for the parameters for our study, 36 articles and 459 patients were included in our study. A flow chart of the screening process is illustrated in Fig. 2. There were 9 retrospective studies, 7 prospective studies, and 20 case reports. Sixty-six percent of reported cases were female patients. Patient and tumor characteristics are reported in Table 1. Risk of bias included selection for studies that fit most our criteria despite other ineligible aspects of the study.

Tumor Characteristics

The locations of meningiomas included in this study are summarized in Table 2. Convexity lesions were most common (40.2%), and these were followed by sphenoidal (15%), parasagittal (8.4%), and petroclival (6.5%) meningiomas. Seven articles focused on specific types of meningiomas including orbital, dorsum sellae, petroclival, intrasellar, falcine, and pineal region meningiomas.[1,6,15,17,33,36,39] There were not enough specific data to make a quantitative analysis based on lesion size or histopathology.

Embolic Material

The embolic materials reported for preresection embolization of meningiomas are reported in Table 3. Nearly half of the studies (n = 15) used PVA; the remaining studies used other materials either alone or in combinations. Six studies reported outcomes of embolization after using different types of embolic material including Onyx (n = 1), Lipiodol (n = 1), phenytoin (n = 1), hydroxyapatite (n = 1), and porous cellulose beads (n = 2).[14,19,23–25,40,50] Two studies compared the effects of different embolic materials.[5,47] In one study of 60 patients comparing trisacryl gelatin (TAG) microspheres against PVA, the trisacryl gelatin was associated with significantly lower operative blood loss.[3] Another study compared different sizes of PVA particles, demonstrating that smaller particles were associated with a higher rate of postembolization tumor necrosis.[47]

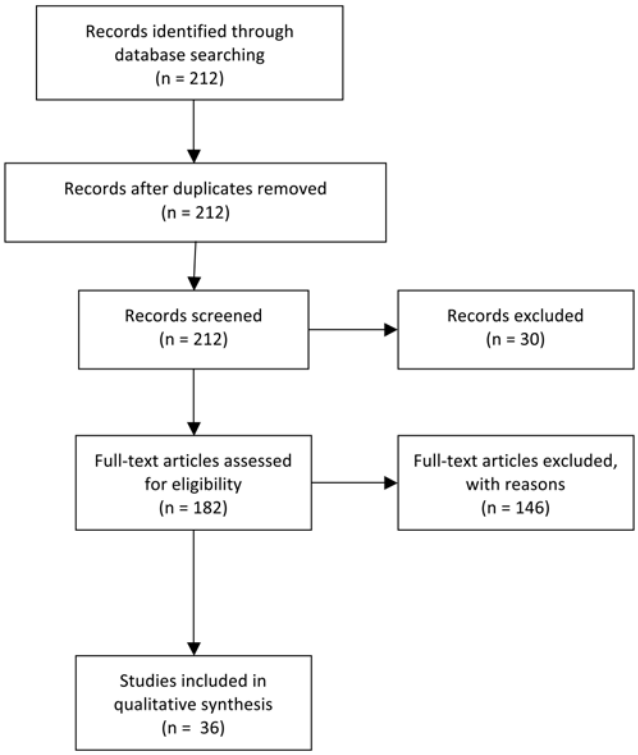

Fig. 2. PRISMA flow chart for systematic reviews.

Timing of Surgery After Embolization

The average time until surgery after embolization in patients in whom this parameter was reported (n = 320 patients) was 6.3 days. The range for delay of surgery after embolization varied between 0 and 30 days. One specific study compared the effects of delaying surgery after embolization[10] and found that delayed surgical cases had less bleeding, depending on the embolic material (337.5 ml vs 475 ml, $p < 0.01$).

Embolization-Related Complications

Outcomes were classified into 3 groups: no neurological deficit, minor deficits, and major complications. In the 459 patients in our study, complications were reported for 21 patients. Overall, 438 patients (95.4%) had no neurological deficits after embolization. There were 21 complications (4.6%) directly related to the embolization, including infection, hemiparesis, facial palsy, disseminated intravascular coagulation, glaucoma, tumor swelling, transient SIADH (syndrome of inappropriate antidiuretic hormone secretion), dysphagia, and cranial nerve deficit. Of the 21 complications, 85.7% (n = 18) were minor, 4.8% (n = 1) were major, and 9.5% (n = 2) were fatal. The major complication was the result of an embolization in a 60-year-old man that resulted in permanent blindness. The 2 deaths were a result of a cerebral infarction in a 37-year-old and a CNS infection in a 45-year-old, both a direct result of embolization. Outcomes and complications of the included studies are summarized in Table 1.

Discussion

Although first described in the early 1970s, preoperative embolization for meningiomas has generally been reserved for a minority of lesions.[30] With significant advances in endovascular techniques over the last decade, however, preoperative embolization has become possible for a wider variety of meningiomas.[48] Embolization offers a number of potential benefits including decreased operative blood loss, shorter operative time, and increased tumor necrosis and softening.[10,12,13,35] However, embolization is also associated with a number of serious risks, including the risk of stroke, hemorrhage, and infection.[5] The aim of our study was to better characterize the results of preoperative embolization of meningiomas as reported in the literature and to report the frequency of complications associated with this procedure in the modern neurosurgical practice.

TABLE 1: Study characteristics of preresection meningioma embolization*

Authors & Year	Study Design	No. of Pts	Male	Age (yrs)	Location	Embol Material	Immediate Complications	No. of GTRs	Time to Op (days)	Long-Term Complications	Notes
Wakhloo, 1993	prosp	34	—	—	—	PVA	tumor swelling (3)	34	—	—	—
Kantrowitz, 1994	CR	1	0	47	petrous apex	dextrose Hypaque	none	1	1	CN V palsy	—
Tymianski, 1994	CR	1	0	29	tentorial	PVA	none	1	21	facial weakness	—
O'Neill, 1995	CR	1	0	82	convexity	PVA	none	1	—	no neurological deficits	meningioma w/ aneurysm
Suzuki, 1995	retro	19	6	52.2	mixed	estrogen ± PVA	neurological deficits (5)	19	—	recurrence (5), death (7)	—
Chung, 1996	CR	1	0	44	convexity	PVA	none	1	—	death	—
Hamada, 1996	CT	11	3	54	mixed	CPBs	none	—	4.3	no neurological deficits	—
Terada, 1996	retro	5	4	45.8	mixed	Gelfoam	visual deficit (2)	5	0.4	hemiparesis (1), visual deficit (2)	—
Sagoh, 1997	CR	1	0	69	pineal	estrogen & PVA	none	0	7	no neurological deficits	—
Kallmes, 1997	CR	1	1	65	parasellar	PVA	hemiplegia, dysphasia	0	—	hemiplegia	hemorrhage due to embol
Nozaki, 1997	CR	1	0	51	intrasellar	platinum microcoils	none	1	6	transient DI	2 surgeries required to achieve GTR
Lefkowitz, 1998	retro	2	1	42	mixed	PVA	none	2	—	no neurological deficits	—
Oka, 1998	retro	12	5	51	mixed	PVA	none	7	—	facial palsy (1), LOC (1)	embol pts had better outcomes than nonembol pts
Yasui, 1998	retro	4	3	—	—	Lipiodol	none	4	7	lockjaw (1), perifocal edema (1)	50% of pts suffered extended complications
Abe, 1999	CR	1	0	73	sellar	PVA	transient SIADH	0	3	no neurological deficits	—
Kaji, 1999	retro	2	2	52.5	convexity	Gelfoam	none	2	4	no neurological deficits	—
Kasuya, 1999	prosp	7	2	57.3	mixed	phenytoin	cerebral edema, facial palsy	7	2	no neurological deficits	—
Bendszus, 2000[5]	prosp	30	11	60	mixed	TMs	permanent blindness	—	3	—	nonembol tumors had shorter surgical time
Bendszus, 2000[3]	prosp	60	15	58	mixed	TMs (30), PVA (30)	none	—	5.5	—	—
Boulos, 2001	CR	1	0	35	orbital	—	none	1	1	no neurological deficits	—
Chun, 2002	retro	50	20	—	mixed	PVA ± coils	none	—	0 (28), 2.5 (22)	—	less blood loss in delayed surgical cases
Hirohata, 2003	prosp	7	0	52.4	petroclival	PVA	none	2	—	no neurological deficits	—
Kubo, 2003	prosp	13	7	57	mixed	HA	none	13	7	—	—
Quinones-Hinojosa, 2003	CR	1	1	48	falcine	—	cortical blindness	1	—	visual deficit	—

(continued)

TABLE 1: Study characteristics of preresection meningioma embolization* ***(continued)***

Authors & Year	Study Design	No. of Pts	Male	Age (yrs)	Location	Embol Material	Immediate Complications	No. of GTRs	Time to Op (days)	Long-Term Complications	Notes
Sorimachi, 2003	CR	1	1	67	OG	PVA	glaucoma	1	30	no neurological deficits	2 surgeries required to achieve GTR
Hirai, 2004	prosp	9	1	67	mixed	—	none	9	—	recurrence (1)	—
Javadpour, 2004	CR	1	0	61	suprasellar	GDCs	none	—	7	no neurological deficits	—
Kai, 2006	retro	128	40	56.6	—	CPBs	none	128	9.9	—	greatest tumor softening seen 7.7 days postembol
Kunikata, 2006	CR	1	1	48	convexity	PVA	visual defect	1	2	diplopia	cilioretinal artery occlusion secondary to embol
Yen, 2006	CR	1	0	45	sphenoid wing	PVA	infection	0	2	death	CNS infection after embol
Tajima, 2007	CR.	1	1	37	convexity	NBCA	hemiparesis	1	1	death	cerebral infarction due to embol
Shi, 2008	retro	3	2	32.7	mixed	Onyx	none	3	10	visual field defect (1)	—
Quiñones-Hinojosa, 2009	retro	45	—	52.7	mixed	—	none	32	1	—	preop embol associated w/ significantly higher rate of GTR
Maekawa, 2009	CR	1	0	72	convexity	PVA	none	1	—	no neurological deficits	concurrent middle meningeal artery aneurysms
Hart, 2011	CR	1	1	57	falcine	Glubran	none	—	—	no neurological deficits	—
Velez, 2011	CR	1	0	62	convexity	Onyx	DIC	0	0	no neurological deficits	—

* CN = cranial nerve; CPB = cellulose porous bead; CR = case report; CT = controlled trial; DI = diabetes insipidus; DIC = disseminated intravascular coagulation; embol = embolization; GDC = Guglielmi detachable coil; GTR = gross-total resection; HA = hydroxyapatite; LOC = loss of consciousness; NBCA = *N*-butyl 2-cyanoacetate; OG = olfactory groove; prosp = prospective; pts = patients; retro = retrospective; SIADH = syndrome of inappropriate antidiueretic hormone secretion; TM = trisacryl microsphere.

TABLE 2: Meningioma location in preresection embolization studies

Location	No. of Pts (%)
tentorium	9 (4.2)
convexity	86 (40.2)
olfactory groove	5 (2.3)
orbital	4 (1.9)
suprasellar	4 (1.9)
posterior fossa	4 (1.9)
sphenoid	32 (15)
cavernous sinus	2 (0.9)
falcine	19 (8.9)
parasagittal	18 (8.4)
petroclival	14 (6.5)
clinoid	10 (4.7)
parasellar	1 (0.5)
pineal region	1 (0.5)
cerebellopontine angle	1 (0.5)
planum sphenoidale	1 (0.5)
dorsum sellae	1 (0.5)
cerebellum	1 (0.5)
intrasellar	1 (0.5)
total no. of pts	214

There are a number of reported benefits when preoperative embolization is applied to certain meningiomas. The most commonly reported benefits are tumor softening and reduced operative blood loss. In a large study of 128 patients, the authors reported significant tumor softening 7.7 days postembolization, facilitating complete resection of all lesions without immediate complications.[19]

TABLE 3: Embolization material in preresection embolization studies

Material	No. of Pts (%)
PVA	144 (31.4)
porous cellulose beads	139 (30.3)
trisacryl gelatin microspheres	60 (13.1)
hydroxyapatite	13 (2.8)
estrogen	11 (2.4)
estrogen + PVA	9 (2.0)
Gelfoam	7 (1.5)
phenytoin	7 (1.5)
Onyx-18	4 (0.9)
Lipiodol	4 (0.9)
Glubran	1 (0.2)
N-butyl-2-cyanoacrylate tissue adhesive	1 (0.2)
Guglielmi detachable coils	1 (0.2)
platinum microcoils	1 (0.2)
dextrose/Hypaque	1 (0.2)
not reported	56 (12.2)
total no. of pts	459

Embolization, for certain very vascularized tumors, may also be beneficial in reducing operative blood loss. In the case of orbital lesions, this may be particularly useful.[6]

Similar embolization-related benefits have been shown for other anterior skull base lesions as well.[38,48] Embolization has also been shown to play a role in certain complex meningiomas with associated vascular lesions or aneurysms. Some studies have illustrated the concurrent embolization of vascular lesions prior to meningioma resection with demonstrated success.[18,29,34]

On the other hand, preoperative embolization is also associated with a number of significant risks. Our analysis of the published English-language literature reveals an overall immediate complication rate of 4.6%. Compared with our study, other studies, which were not included in our analyses because of exclusion criteria in our initial search, have reported similar complication rates associated with preoperative embolization (a mean of 6.8% for 749 embolized tumors)[4,8,38,48] (Table 4). Because of the broad range of cases involving preoperative meningioma embolization, it is uncertain whether our complication rate truly reflects the actual complication rate of the procedure; however, it may be likely that an estimated complication rate falls within the range of 4.6% to 6.8%. The embolization-related complication rate is valuable for understanding the added risk of this procedure. For every 20 patients treated preoperatively with embolization, 1 will suffer from a complication (transient or sustained); however, this complication rate does not take into account the potential added benefit of embolization—that is, reduced surgical morbidity. Because our paper does not compare surgical outcomes of embolized and nonembolized meningiomas, assumptions on the added risk or benefit of preoperative embolization cannot be made at this time. Our paper did not report outcomes specifically because, in the studies included, there were no substantial control groups of meningioma patients without embolization.

The timing of surgery after embolization has only been investigated in 2 papers in the literature to date.[10,40] Both studies concluded that a delayed operative course (> 24 hours) was effective in reducing intraoperative bleeding and tumor size. However, in the event that a complication arises from preoperative embolization, the value of delaying surgery may not be warranted, as these deficits could potentially be reversed postoperatively if, in the cases of mass effect or hemorrhaging, the patient is taken to surgery immediately. It is important that patients be closely monitored in the time between embolization and surgery to ensure prompt diagnosis and treatment of any immediate complications. Based on the studies included in this review, delaying surgery may not add any significant increased risk. However, some of the senior authors are aware of several anecdotal cases in which preoperative embolization resulted in significant tumor necrosis and edema with acute neurological decline, requiring an emergency tumor resection.

In patients with giant meningiomas, preoperative embolization may help significantly in reducing intraoperative bleeding, which has been associated with a higher mortality rate. However, this is a matter of clinical judgment, and depending on the anatomy of individual

TABLE 4: Selected studies of preoperative embolization

Authors & Year	No. of Pts	Embolization Materials	Complications (%)
Bendzsus, 2005	185	TMs	6 (3.2)
Carli, 2010	198	PVA	11 (5.6)
Rosen, 2002	167	PVA	21 (12.6)
Waldron, 2011	199	PVA	13 (2.8)
total no. of pts	749		51 (6.8%)

tumors, in some of these patients these benefits may outweigh the risks of preoperative embolization.[36]

The reason why embolization is not more prevalent is understandable. For large "cranial vault" meningiomas, the main blood supply usually arises from branches of superficial temporal, occipital, middle meningeal, and/or posterior meningeal arteries, all of which are accessible surgically early during the exposure. For large "skull base" meningiomas, blood supply generally arises from petrous/cavernous/pial internal carotid artery branches or vertebrobasilar branches, all of which are difficult or impossible to selectively catheterize safely. In our opinion, the tumor that stands to gain most from preoperative embolization is the giant convexity lesion with such exuberant and multidirectional blood supply that simply opening the bone flap can result in catastrophic blood loss.

However, despite some of the reported benefits of devascularization, some neurosurgeons question its use because some surgical approaches may allow for in situ devascularization intraoperatively. In this concept, neurosurgeons must carefully plan operative approaches to identify parent vessels and effectively reduce blood loss, which may offer an alternative to preoperative embolization. In addition, with the decreased frequency of arteriography prior to MRI, surgical approaches that devascularize and facilitate tumor removal may be gaining prominence in the neurosurgical community.

In the rare case of a meningioma associated with a vascular lesion such as an aneurysm or arteriovenous malformation, preoperative embolization of the concurrent aneurysms may be essential to the success of resecting the meningioma. The 3 reviewed cases of preoperative embolization in cases of concurrent meningioma and aneurysm reported successful resection without complications when the aneurysm or arteriovenous malformation was embolized prior to surgery.[18,29,34]

Due to the nature of the published literature on this subject, this study is based on a collection of case series and case reports only and constitutes only Class III evidence. The original reports included in this study are subject to publication bias (reporting bias) and selection bias, which may both have affected the overall complications for preoperative embolization. Given these limitations, our reported complication rate is similar to the reported complication rates. Nevertheless, a full review comparing outcomes of preoperative embolization patients and control patients with meningiomas may yield further insight into the nature and benefit of this procedure. Taking these limitations into account, our intention is not to create a formal guideline but to provide a concise summary of the literature to outline the frequency and characteristics of complications associated with preoperative embolization.

Conclusions

Based on our review of the published literature, preoperative embolization is associated with a complication rate of 4.6%. However, based on our review, we cannot conclude that preoperative embolization is dangerous since most complications were transient; we do, however, maintain that preoperative embolization adds risks that must be factored into the decision making process. Treatment decisions for patients with meningiomas must be individualized based on the presenting symptoms, location of meningioma, presence of concurrent vascular lesions, surgeon's experience, and feasibility of resection. At present, guidelines governing the use of preoperative embolization cannot be made, and further studies are needed to fully assess the potential benefits/risks of preoperative embolization. As endovascular and embolic techniques continue to evolve and the immediate and delayed complications become more fully characterized, the complication rates of preoperative embolization of meningiomas may decline and the indications for this procedure may expand. There is also an increasing interest in intraoperative direct needle puncture intratumoral embolization, the value of which will have to await larger experiences.

Disclosure

The authors report no conflict of interest concerning the materials or methods used in this study or the findings specified in this paper.

Author contributions to the study and manuscript preparation include the following. Conception and design: Shah. Acquisition of data: Shah, Patel. Analysis and interpretation of data: Shah, Patel, Raper. Drafting the article: Shah, Bregy. Critically revising the article: all authors. Reviewed submitted version of manuscript: all authors. Administrative/technical/material support: Komotar, Shah. Study supervision: Komotar.

References

1. Abe T, Matsumoto K, Homma H, Kawamura N, Iwata T, Nemoto S: Dorsum sellae meningioma mimicking pituitary macroadenoma: case report. **Surg Neurol 51:**543–547, 1999
2. Anderson D, Khalil M: Meningioma and the ophthalmologist. A review of 80 cases. **Ophthalmology 88:**1004–1009, 1981
3. Bendszus M, Klein R, Burger R, Warmuth-Metz M, Hofmann E, Solymosi L: Efficacy of trisacryl gelatin microspheres versus polyvinyl alcohol particles in the preoperative embolization of meningiomas. **AJNR Am J Neuroradiol 21:**255–261, 2000

4. Bendszus M, Monoranu CM, Schütz A, Nölte I, Vince GH, Solymosi L: Neurologic complications after particle embolization of intracranial meningiomas. **AJNR Am J Neuroradiol 26:**1413–1419, 2005
5. Bendszus M, Rao G, Burger R, Schaller C, Scheinemann K, Warmuth-Metz M, et al: Is there a benefit of preoperative meningioma embolization? **Neurosurgery 47:**1306–1312, 2000
6. Boulos PT, Dumont AS, Mandell JW, Jane JA Sr: Meningiomas of the orbit: contemporary considerations. **Neurosurg Focus 10(5):**E5, 2001
7. Burkhardt JK, Zinn PO, Graenicher M, Santillan A, Bozinov O, Kasper EM, et al: Predicting postoperative hydrocephalus in 227 patients with skull base meningioma. **Neurosurg Focus 30(5):**E9, 2011
8. Carli DF, Sluzewski M, Beute GN, van Rooij WJ: Complications of particle embolization of meningiomas: frequency, risk factors, and outcome. **AJNR Am J Neuroradiol 31:**152–154, 2010
9. Celedin S, Rabitsch E, Hausegger KA, Richling B: Accidental transtumoral microparticle embolization of eloquent brain areas in a case of large temporofrontal meningioma. **Interv Neuroradiol 14:**339–343, 2008
10. Chun JY, McDermott MW, Lamborn KR, Wilson CB, Higashida R, Berger MS: Delayed surgical resection reduces intraoperative blood loss for embolized meningiomas. **Neurosurgery 50:**1231–1237, 2002
11. Chung YG, Lee KC, Lee IS, Lee NJ: Profound hypothermia and cardiopulmonary bypass in the treatment of recurrent giant angioblastic meningioma case report. **J Korean Med Sci 11:** 449–453, 1996
12. Dean BL, Flom RA, Wallace RC, Khayata MH, Obuchowski NA, Hodak JA, et al: Efficacy of endovascular treatment of meningiomas: evaluation with matched samples. **AJNR Am J Neuroradiol 15:**1675–1680, 1994
13. Dowd CF, Halbach VV, Higashida RT: Meningiomas: the role of preoperative angiography and embolization. **Neurosurg Focus 15(1):**E10, 2003
14. Hamada J, Ushio Y, Kazekawa K, Tsukahara T, Hashimoto N, Iwata H: Embolization with cellulose porous beads, I: An experimental study. **AJNR Am J Neuroradiol 17:**1895–1899, 1996
15. Hart JL, Davagnanam I, Chandrashekar HS, Brew S: Angiography and selective microcatheter embolization of a falcine meningioma supplied by the artery of Davidoff and Schechter. Case report. **J Neurosurg 114:**710–713, 2011
16. Hirai T, Korogi Y, Ono K, Uemura S, Yamashita Y: Preoperative embolization for meningeal tumors: evaluation of vascular supply with angio-CT. **AJNR Am J Neuroradiol 25:** 74–76, 2004
17. Hirohata M, Abe T, Morimitsu H, Fujimura N, Shigemori M, Norbash AM: Preoperative selective internal carotid artery dural branch embolisation for petroclival meningiomas. **Neuroradiology 45:**656–660, 2003
18. Javadpour M, Khan AD, Jenkinson MD, Foy PM, Nahser HC: Cerebral aneurysm associated with an intracranial tumour: staged endovascular and surgical treatment in two cases. **Br J Neurosurg 18:**280–284, 2004
19. Kai Y, Hamada JI, Morioka M, Yano S, Nakamura H, Makino K, et al: Clinical evaluation of cellulose porous beads for the therapeutic embolization of meningiomas. **AJNR Am J Neuroradiol 27:**1146–1150, 2006
20. Kaji T, Hama Y, Iwasaki Y, Kyoto Y, Kusano S: Preoperative embolization of meningiomas with pial supply: successful treatment of two cases. **Surg Neurol 52:**270–273, 1999
21. Kallmes DF, Evans AJ, Kaptain GJ, Mathis JM, Jensen ME, Jane JA, et al: Hemorrhagic complications in embolization of a meningioma: case report and review of the literature. **Neuroradiology 39:**877–880, 1997
22. Kantrowitz AB, Spallone A, Taylor W, Chi TL, Strack M, Feghali JG: Erythropoietin-augmented isovolemic hemodilution in skull-base surgery. Case report. **J Neurosurg 80:**740–744, 1994
23. Kasuya H, Shimizu T, Sasahara A, Takakura K: Phenytoin as a liquid material for embolisation of tumours. **Neuroradiology 41:**320–323, 1999
24. Kubo M, Kuwayama N, Hirashima Y, Takaku A, Ogawa T, Endo S: Hydroxyapatite ceramics as a particulate embolic material: report of the clinical experience. **AJNR Am J Neuroradiol 24:**1545–1547, 2003
25. Kubo M, Kuwayama N, Hirashima Y, Takaku A, Ogawa T, Endo S: Hydroxyapatite ceramics as a particulate embolic material: report of the physical properties of the hydroxyapatite particles and the animal study. **AJNR Am J Neuroradiol 24:**1540–1544, 2003
26. Kunikata H, Tamai M: Cilioretinal artery occlusions following embolization of an artery to an intracranial meningioma. **Graefes Arch Clin Exp Ophthalmol 244:**401–403, 2006
27. Lefkowitz M, Giannotta SL, Hieshima G, Higashida R, Halbach V, Dowd C, et al: Embolization of neurosurgical lesions involving the ophthalmic artery. **Neurosurgery 43:**1298–1303, 1998
28. Lieu AS, Howng SL: Intracranial meningiomas and epilepsy: incidence, prognosis and influencing factors. **Epilepsy Res 38:** 45–52, 2000
29. Maekawa H, Tanaka M, Hadeishi H: Middle meningeal artery aneurysm associated with meningioma. **Acta Neurochir (Wien) 151:**1167–1168, 2009
30. Manelfe C, Guiraud B, David J, Eymeri JC, Tremoulet M, Espagno J, et al: [Embolization by catheterization of intracranial meningiomas.] **Rev Neurol (Paris) 128:**339–351, 1973 (Fr)
31. Nakamura M, Roser F, Bundschuh O, Vorkapic P, Samii M: Intraventricular meningiomas: a review of 16 cases with reference to the literature. **Surg Neurol 59:**491–504, 2003
32. Nakamura M, Roser F, Michel J, Jacobs C, Samii M: The natural history of incidental meningiomas. **Neurosurgery 53:** 62–71, 2003
33. Nozaki K, Nagata I, Yoshida K, Kikuchi H: Intrasellar meningioma: case report and review of the literature. **Surg Neurol 47:**447–454, 1997
34. O'Neill OR, Barnwell SL, Silver DJ: Middle meningeal artery aneurysm associated with meningioma: case report. **Neurosurgery 36:**396–398, 1995
35. Oka H, Kurata A, Kawano N, Saegusa H, Kobayashi I, Ohmomo T, et al: Preoperative superselective embolization of skull-base meningiomas: indications and limitations. **J Neurooncol 40:**67–71, 1998
36. Quinones-Hinojosa A, Chang EF, McDermott MW: Falcotentorial meningiomas: clinical, neuroimaging, and surgical features in six patients. **Neurosurg Focus 14(6):**e11, 2003
37. Quiñones-Hinojosa A, Kaprealian T, Chaichana KL, Sanai N, Parsa AT, Berger MS, et al: Pre-operative factors affecting resectability of giant intracranial meningiomas. **Can J Neurol Sci 36:**623–630, 2009
38. Rosen CL, Ammerman JM, Sekhar LN, Bank WO: Outcome analysis of preoperative embolization in cranial base surgery. **Acta Neurochir (Wien) 144:**1157–1164, 2002
39. Sagoh M, Onozuka S, Murakami H, Hirose Y: Successful removal of meningioma of the pineal region after embolization. **Neurol Med Chir (Tokyo) 37:**852–855, 1997
40. Shi ZS, Feng L, Jiang XB, Huang Q, Yang Z, Huang ZS: Therapeutic embolization of meningiomas with Onyx for delayed surgical resection. **Surg Neurol 70:**478–481, 2008
41. Sorimachi T, Maruya J, Mizusawa Y, Ito Y, Takeuchi S: Glaucoma as a complication of superselective ophthalmic angiography. **AJNR Am J Neuroradiol 24:**1552–1553, 2003
42. Suzuki M, Mizoi K, Yoshimoto T: Should meningiomas involving the cavernous sinus be totally resected? **Surg Neurol 44:**3–13, 1995
43. Tajima Y, Takagi R, Kominato Y, Kuwayama N: A case of

iatrogenic cerebral infarction demonstrated by postmortem cerebral angiography. **Leg Med (Tokyo) 9:**326–329, 2007
44. Terada T, Kinoshita Y, Yokote H, Tsuura M, Itakura T, Komai N, et al: Preoperative embolization of meningiomas fed by ophthalmic branch arteries. **Surg Neurol 45:**161–166, 1996
45. Tymianski M, Willinsky RA, Tator CH, Mikulis D, TerBrugge KG, Markson L: Embolization with temporary balloon occlusion of the internal carotid artery and in vivo proton spectroscopy improves radical removal of petrous-tentorial meningioma. **Neurosurgery 35:**974–977, 1994
46. Velez AM, Friedman WA: Disseminated intravascular coagulation during resection of a meningioma: case report. **Neurosurgery 68:**E1165–E1169, 2011
47. Wakhloo AK, Juengling FD, Van Velthoven V, Schumacher M, Hennig J, Schwechheimer K: Extended preoperative polyvinyl alcohol microembolization of intracranial meningiomas: assessment of two embolization techniques. **AJNR Am J Neuroradiol 14:**571–582, 1993
48. Waldron JS, Sughrue ME, Hetts SW, Wilson SP, Mills SA, McDermott MW, et al: Embolization of skull base meningiomas and feeding vessels arising from the internal carotid circulation. **Neurosurgery 68:**162–169, 2011
49. Yano S, Kuratsu J: Indications for surgery in patients with asymptomatic meningiomas based on an extensive experience. **J Neurosurg 105:**538–543, 2006
50. Yasui K, Shoda Y, Suyama T, Numa Y, Amanouchi YY, Kawamoto K: Preoperative embolization for meningioma using lipiodol. **Interv Neuroradiol 4 (Suppl 1):**63–66, 1998
51. Yen PS, Lin CC, Lee CC, Harnod T, Loh TW, Hsu YH: CNS Clostridium perfringens infection: a rare complication of preoperative embolization of meningioma. **AJNR Am J Neuroradiol 27:**1355–1356, 2006

Manuscript submitted July 5, 2012.
Accepted March 8, 2013.
Please include this information when citing this paper: published online April 12, 2013; DOI: 10.3171/2013.3.JNS121328.
Address correspondence to: Ricardo J. Komotar, M.D., Department of Neurological Surgery, 1095 NW 14th Terrace, Room 2-06, University of Miami Hospital, West Building, Suite 306, Miami, Florida 33125. email: RKomotar@med.miami.edu.