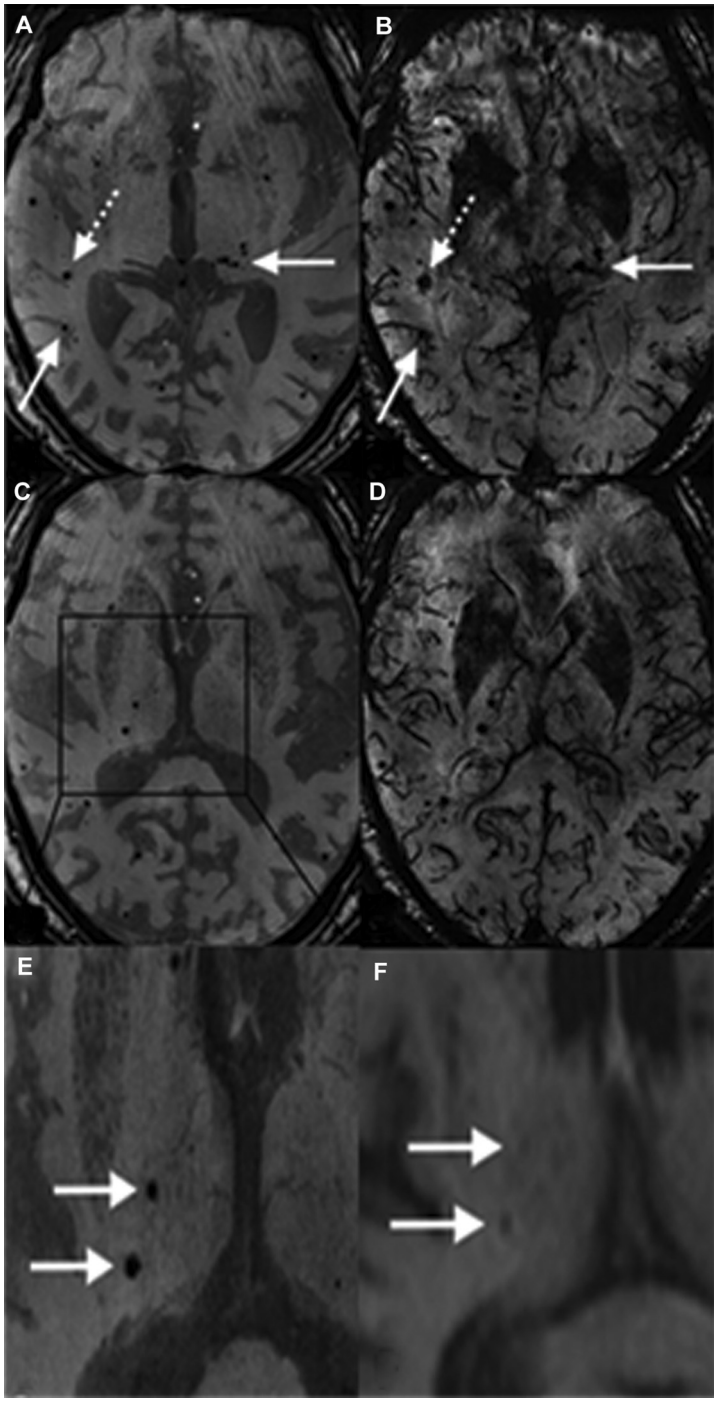

*Figure 3. A 77-year-old male presented with transient ischemic attack of the left hemisphere. Minimum intensity projections of 7T MRI with a 10-mm thickness for the 1st echo (**A** and **C**) and 2nd echo (**B** and **D**) show multiple microbleeds (arrows). Some lesions overlapping venous structures (striped arrows) are less easily distinguishable in the 2nd echo of 7T MRI. A zoomed 7T MRI image (**E**) provides a better depiction of the microbleeds than that of 1.5T MRI (**F**) due to the increased susceptibility effects.[3] Reprinted from* European Journal of Radiology, *Vol 82/5, van der Kolk AG, Hendrikse J, Zwanenburg JJ, Visser F, Luijten PR, Clinical applications of 7T MRI in the brain, Pages No. 708-718, Copyright (2013), with permission from Elsevier.*

5. Conijn MM, Hendrikse J, Zwanenburg JJ, et al. Perforating arteries originating from the posterior communicating artery: a 7.0-Tesla MRI study. *Eur Radiol.* 2009;19(12):2986-2992.
6. Hasan D, Chalouhi N, Jabbour P, et al. Early change in ferumoxytol-enhanced magnetic resonance imaging signal suggests unstable human cerebral aneurysm: a pilot study. *Stroke*. 2012;43:3258-3265.
7. Biessels GJ, Zwanenburg JJ, Visser F, Frijns CJ, Luijten PR. Hypertensive cerebral hemorrhage: imaging the leak with 7-T MRI. *Neurology*. 2010;75(6): 572-573.
8. Kuroda S, Kashiwazaki D, Ishikawa T, Nakayama N, Houkin K. Incidence, locations, and longitudinal course of silent microbleeds in moyamoya disease: a prospective T2*-weighted MRI study. *Stroke*. 2013; 44(2):516-518.
9. Conijn MM, Geerlings MI, Luijten PR, et al. Visualization of cerebral microbleeds with dual-echo T2*-weighted magnetic resonance imaging at 7.0 T. *J Magn Reson Imaging.* 2010;32(1):52-59.

Identification of Novel Therapeutic Targets Through Genomic Analysis of Meningiomas

Meningiomas are the most common primary extraaxial brain tumors.[1] Although the majority of meningiomas are benign it is difficult to discern atypical or anaplastic meningiomas without pathological diagnosis. As these tumors are often in proximity to key neural and vascular structures, complete surgical resection is often associated with significant morbidity and mortality. Stereotactic radiosurgery is a commonly employed adjuvant or primary therapy, but can also lead to genetic mutations and additional primary tumors.[2] Medical therapy is limited in the treatment of meningiomas in part due to our incomplete understanding of DNA alterations in meningiomas. A number of genetic alterations have been identified in meningiomas including loss of Neurofibromin 2 (NF2, marlin) in 40%-60% of sporadic meningiomas, but further genetic pathways remain incompletely defined.[3-5] A greater evaluation of the genetic alterations in meningiomas could also help predict those that are more likely to be or transform into anaplastic lesions.

Recently, publications in *Science*[6] and *Nature Genetics*[7] reported key mutations in a number of genes in meningiomas. Studies found that meningiomas had a small number of somatic genetic events as compared to other tumor types, but was more likely in high grade meningiomas. Clark et al performed a genome-wide genotyping analysis of 50 meningiomas

Copyright © Congress of Neurological Surgeons. Unauthorized reproduction of this article is prohibited.

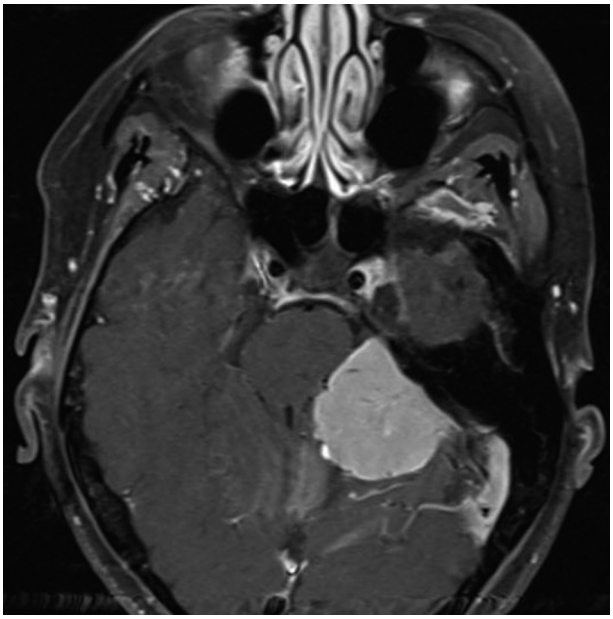

Figure. T1-weighted MRI with contrast demonstrates meningiomas of the cerebellopontine angle that was found to be a WHO grade I meningiomas.

along with matched normal DNA.[6] A number of mutations were found that occurred more likely than would be found by chance, for example NF2, TNF receptor-associated factor 7 (TRAF7), Krupple-like factor 4 (KLF4), v-akt murine thymoma viral oncogene homolog 1 (AKT1), and Smoothened, frizzled family receptor (SMO) (source). Additionally, NF2 occurred independently of those in TRAF7, KLF4, AKT1, and SMO. Targeted resequencing of these genes along with another cohort of 250 meningiomas reveled mutations in 1 of these genes and/or loss of chromosome 22 in 79% of samples.

TRAF7 mutations occurred in approximately 25% of samples.[6] This has important functional implications as TRAF7 plays a role in many pathways proapoptotic mechanisms. KLF4 has been recently found to be a key pluropotency factor that can help transform differentiated somatic cells into pluripotent stem cells[8] and was found in approximately 10% of meningiomas samples.[6] AKT1 can induce PI3K/mTOR signaling pathways, is a known recurrent mutation in tumorgenesis, and occurred in approximately 13% of samples.[6] Mutations in SMO which has been shown to active that Hedgehog signaling pathway in other tumors were found in approximately 4% of meningiomas.[6] Similarly, Brastianos et al used genome analysis of a set of meningiomas and focused sequence analysis in a validation set to identify a number of mutations including NF2, SMO, and AKT1.[7] The authors also found significant gains on chromosomes 5 and 20 and losses on 1p, 7p, 14p, and 19 which have been previously noted in the literature.[9] Additionally, recurrent losses were found on 10q and 14q which found been previously found in anaplastic meningiomas.[10]

Both studies carried out additional studies to further assess pathway activation in meningiomas samples. GAB1 immunoreactivity has been used in medullobstomas to assess Hedgehog pathway activation.[11] Brastianos et al found strong immunoreactivity for 7 tumors along including 3 meningiomas with SMO mutations.[7] Similarly, STMN1 has been used to characterize PI3K-AKT induction.[12] The authors also found that all meningiomas with AKT1 and MTOR mutations had strong immunoreactivity for STMN1.[7] Additionally, 3 meningiomas with SMO mutations had STMN1 immunostaining. This supports prior studies that have indicated interactions between the PI3K-AKT-mTOR pathways.[13]

Mutations were further assessed to determine if they were associated with specific clinical and histological subtypes. Chromosome 22 loss, occurring 50% of samples was significantly associated with NF2 mutations, higher grade meningiomas, male gender, and cerebral hemisphere location.[6] The majority of non-NF2 meningiomas were located medially and more likely to occur along with skull base.[6] Those with TRAF7 and KLF4 were also associated with a histological secretory component (source).[6] Brastianos et al also found that meningiomas with SMO and AKT1 mutations may be more likely to be located in therapeutically challenging locations such as the skull base.[7] Additionally, they found that tumors with SMO and AKT1 mutations were more likely to have meningothelial histology and grade 1, NF2 mutated tumors were more likely to be of the transitional or fibroblastic subtype.[7]

These studies provide further evidence of the growing differentiation of specific tumors into genetic subtypes rather than just histological variants. Further studies may confirm that a number of these mutations are mutually exclusive, provide a significant risk of aggressive malignancy, are associated with specific anatomical locations, and demonstrate a specific histological diagnosis. Additionally, there are currently a number of medications that are either FDA-approved or in clinical trails that inhibit MTOR, AKT1, and SMO and may be particularly beneficial for specific meningiomas.

Ricardo J. Komotar
Robert M. Starke
E. Sander Connolly

REFERENCES

1. Wiemels J, Wrensch M, Claus EB. Epidemiology and etiology of meningioma. *J Neurooncol.* 2010;99(3):307-314.
2. Shoshan Y, Chernova O, Juen SS, et al. Radiation-induced meningioma: a distinct molecular genetic pattern? *J Neuropathol Exp Neurol.* 2000;59(7):614-620.
3. Riemenschneider MJ, Perry A, Reifenberger G. Histological classification and molecular genetics of meningiomas. *Lancet Neurol.* 2007;6(2):105.
4. Schmitz U, Mueller W, Weber M, Sevenet N, Delattre O, von Deimling A. INI1 mutations in meningiomas at a potential hotspot in exon 9. *Br J Cancer.* 2001;84(2):199-201.
5. Mawrin C, Perry A. Pathological classification and molecular genetics of meningiomas. *J Neurooncol.* 2010;99(3):379-391.
6. Clark VE, Erson-Omay EZ, Serin A, et al. Genomic analysis of non-NF2 meningiomas reveals mutations in TRAF7, KLF4, AKT1, and SMO. *Science*. 2013;339(6123):1077-1080.
7. Brastianos PK, Horowitz PM, Santagata S, et al. Genomic sequencing of meningiomas identifies oncogenic SMO and AKT1 mutations. *Nat Genet.* 2013;45(3):285-289.
8. Takahashi K, Tanabe K, Ohnuki M, et al. Induction of pluripotent stem cells from adult human fibroblasts by defined factors. *Cell.* 2007;131(5):861-872.
9. Ketter R, Kim YJ, Storck S, et al. Hyperdiploidy defines a distinct cytogenetic entity of meningiomas. *J Neurooncol.* 2007;83(2):213-221.
10. Choy W, Kim W, Nagasawa D, et al. The molecular genetics and tumor pathogenesis of meningiomas and the future directions of meningioma treatments. *Neurosurg Focus.* 2011;30(5):E6.

Copyright © Congress of Neurological Surgeons. Unauthorized reproduction of this article is prohibited.

11. Ellison DW, Dalton J, Kocak M, et al. Medulloblastoma: clinicopathological correlates of SHH, WNT, and non-SHH/WNT molecular subgroups. *Acta Neuropathol.* 2011;121(3):381-396.
12. Karst AM, Levanon K, Duraisamy S, et al. Stathmin 1, a marker of PI3K pathway activation and regulator of microtubule dynamics, is expressed in early pelvic serous carcinomas. *Gynecol Oncol.* 2011;123(1):5-12.
13. Riobo NA, Lu K, Ai X, Haines GM, Emerson CP Jr. Phosphoinositide 3-kinase and Akt are essential for Sonic Hedgehog signaling. *Proc Natl Acad Sci U S A.* 2006;103(12):4505-4510.

Can Pain Be Measured Objectively?

As neurosurgeons, many of the patients we encounter suffer from pain. As such it can play a central role in our decision making process. For example, the judgment to perform spine surgery is frequently dependent on the patient's narrative of their pain. Furthermore, neurosurgeons commonly encounter clinical scenarios in which, patients are unable to report pain due to head trauma or sedation. In these situations we cannot determine with any certainty whether we have treated their pain either inadequately or excessively. In the past, pain could only be assessed as a subjective report given by patients. However, self-reporting has obvious limitations and may be affected by secondary gain. The unreliability of such an important variable in our decision making process may have far reaching effects on the outcome of our interventions.

In an article published in the April 2013 edition of the *New England Journal of Medicine*, Wager and colleagues attempted to determine brain signatures to quantify pain objectively using modern functional magnetic resonance imaging (fMRI) technology.[1] The authors conducted several different studies. The first identified the brain regions (neurological signature) activated by thermal pain applied to the forearm, as the dorsal posterior insula, the secondary somatosensory cortex the anterior insula, the ventrolateral and medial thalamus, the hypothalamus and the dorsal anterior cingulate cortex (Figure). In the second study, activation in these brain regions by non-painful warmth was compared to painful heat. The third study investigated the brains' activity during somatic stimulus as compared with social/emotional stimulations. The final branch of the study investigated the effect of remifentanil on brain activity during both social and heat-induced pain.

In contrast to the possibility that different individuals manifest pain in different brain regions, the authors noticed a universal pattern of pain activation (neurological signature) across individuals that could be used to detect pain objectively across all study participants. fMRI scans were able to discriminate between painful heat and non-painful warmth with a sensitivity and specificity of 94%. More importantly, fMRI was able to discriminate between relative differences in pain with a sensitivity and specificity of 93%, with pain ratings differing by 2 or more points on the 10-point Visual Analogue Scale. As expected from wide-dynamic-range neurons and nociceptive-specific neurons, signal intensity increased on a continuum from warmth to painful heat stimulation. Interestingly, the signal strength correlation with the reported level of pain was $r = 0.73$ compared to $r = 0.65$ with temperature change, indicating the strength of neural signature holds a stronger correlation to subjective pain perception than to the intensity of the thermal stimulation. Remifentanil infusion was associated with a 53% reduction in the signature response ($P = .94$). This shows that fMRI signals may be clinically useful for monitoring the adequacy of pain control.

This benchmark paper expanded our understanding of acute pain in healthy individuals and provided an important method to visualize and quantify pain objectively using brain imaging. However, we need to remember that the pain signature described in this study were the result of moderate thermal pain applied to the forearm of young healthy volunteers. Severe pain, pain in other locations, pathological pain, or chronic pain may all produce variations in pain signature patterns. Additionally, modulating factors such as anxiety, fatigue, and depression were not studied. Specifically, central pain processing in chronic pain states from certain diseases may differ significantly from the acute pain in healthy individuals. The authors rightly pointed out that further investigation of different anatomical locations and pain modalities is needed to assess the generalizability of this method before it can be applied to clinical practice.

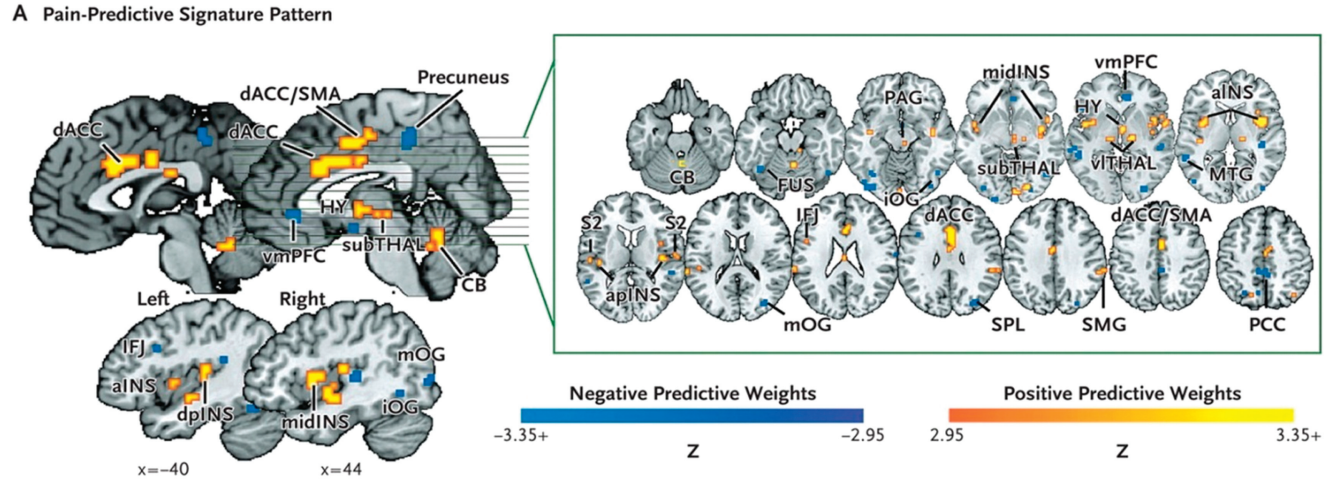

Figure. Fluid attenuated inversion recovery MRI demonstrates a lesion in the left atrium with significant edema, which turned out to be an anaplastic meningioma.

Copyright © Congress of Neurological Surgeons. Unauthorized reproduction of this article is prohibited.